



PATIENT

Checkers Reitzel

PRESENTING CLINICAL SIGNS

Ca elevation/vomiting/PU/PD
Abnormal PE/Chem/CBC/UA Results: lymphs decreased 19%, Ca 12.7

SPECIES

Feline

ULTRASONOGRAPHIC EXAMINATION OF THE ABDOMEN

Urinary System

Urinary bladder is moderately distended. It has a normal uniform wall thickness (<0.2 cm). Contents include primarily anechoic fluid combined with suspended echogenic non-shadowing debris within the fluid. No masses or cystoliths are observed. The trigone and visible pelvic urethra are normal in thickness with a smooth mucosal surface.

BREED

Domestic Shorthair

SEX

Neutered male

Left kidney is normal in size (3.93 cm), shape and echogenicity. It has smooth peripheral margination and appropriate corticomedullary distinction. There is no pyelectasia noted. No mineral is observed.

AGE

7 years

Right kidney is normal in size (4.13 cm), shape and echogenicity. It has smooth peripheral margination and appropriate corticomedullary distinction. There is no pyelectasia noted. No mineral is observed.

WEIGHT

7.3 lbs

Adrenal Glands

Left adrenal gland is normal in size (0.84 cm long x 0.4 cm thick), shape and contour. Corticomedullary structure is unremarkable.

Right adrenal gland is normal in size (0.96 cm long x 0.35 cm thick), shape and contour. Corticomedullary structure is unremarkable.

INTERPRETED BY

Beth Johnson, DVM
DACVIM

Spleen

Spleen is subjectively normal in size with normal smooth margins. Parenchyma is normal in echogenicity and echotexture. No focal nodules or masses are observed. Splenic vasculature appears normal.

IMAGING PERFORMED BY

Diane McFadden,
RVT

Liver

Liver is subjectively normal in size. Margins are sharp and smooth. It has normal homogenous echotexture and normal echogenicity. No focal lesions are observed. Visible vasculature appears normal. Gallbladder is mildly distended with anechoic contents. The wall is smooth without visible thickening. There is no evidence of common bile duct dilation.

HOSPITAL NAME

Summit Dog and Cat
Hospital

REFERRING VET

Dr. Vogler

Gastrointestinal

The visible gastric wall is normal in thickness (canine < 0.5 cm and feline < 0.4 cm). The stomach is empty.

INVOICE

95950

The small intestines are normal in wall thickness and layering. Small intestinal motility appears adequate (1-3 contractions per min). There are no luminal contents noted within small intestines.

DATE

2/9/22

Colon is normal in wall thickness (< 0.2 cm) and layering.



PATIENT

Pancreas

Checkers Reitzel

Pancreas has normal homogenous echotexture and is normal in echogenicity and smooth margination. There is no evidence of peripancreatic inflammation.

SPECIES

Feline

Free Abdomen

Lymph nodes are normal with no observed enlargement.

BREED

Domestic Shorthair

ULTRASONOGRAPHIC FINDINGS

SEX

Neutered male

Primary Findings

- Urinary bladder sediment – Urine changes are most consistent with incidental suspended lipid in a cat, however, cellular debris or crystalluria cannot be ruled out and should be interpreted in combination with urinalysis results.
- Otherwise, unremarkable abdomen.

AGE

7 years

INTERPRETATION OF THE FINDINGS & FURTHER RECOMMENDATIONS

WEIGHT

7.3 lbs

There are no visible ultrasonographic explanations for the vomiting or PU/PD in this patient which lends suspicion that the PU/PD and vomiting are potentially secondary to the hypercalcemia. Recommendations include pursuing a hypercalcemia work-up with a PTH, PTHRP and ionized calcium. There is a malignancy panel that includes all 3 at Michigan State University. If a urinalysis has not been recently performed recommendations also include a urinalysis with urine culture if indicated based on urinalysis results.

INTERPRETED BY

Beth Johnson, DVM
DACVIM

IMAGING PERFORMED BY

Diane McFadden,
RVT

HOSPITAL NAME

Summit Dog and Cat
Hospital

REFERRING VET

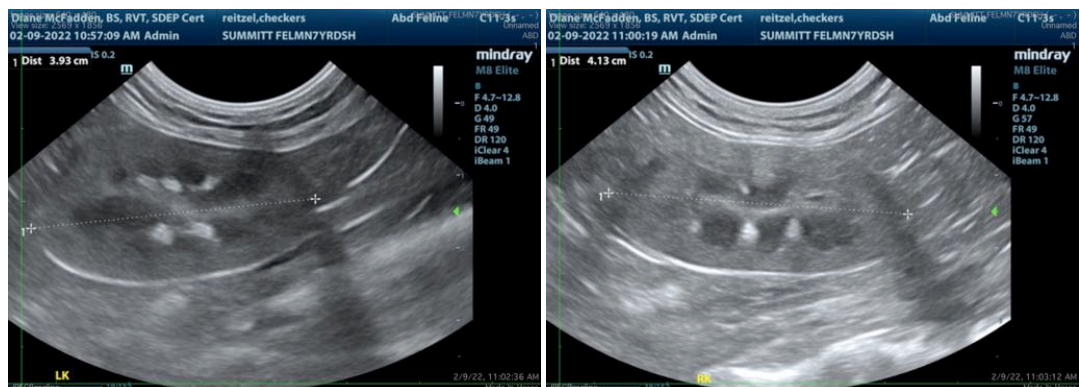
Dr. Vogler

INVOICE

95950

DATE

2/9/22





PATIENT

Checkers Reitzel

SPECIES

Feline

BREED

Domestic Shorthair

SEX

Neutered male

AGE

7 years

WEIGHT

7.3 lbs

INTERPRETED BY

Beth Johnson, DVM
DACVIM

IMAGING PERFORMED BY

Diane McFadden,
RVT

HOSPITAL NAME

Summit Dog and Cat
Hospital

REFERRING VET

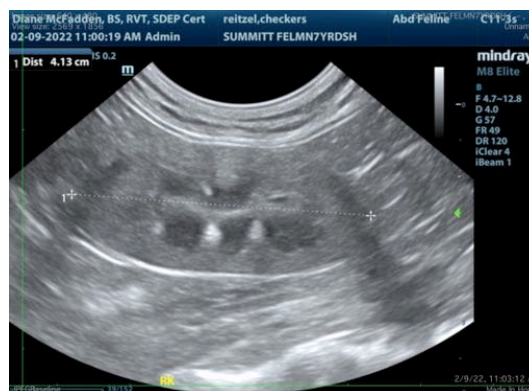
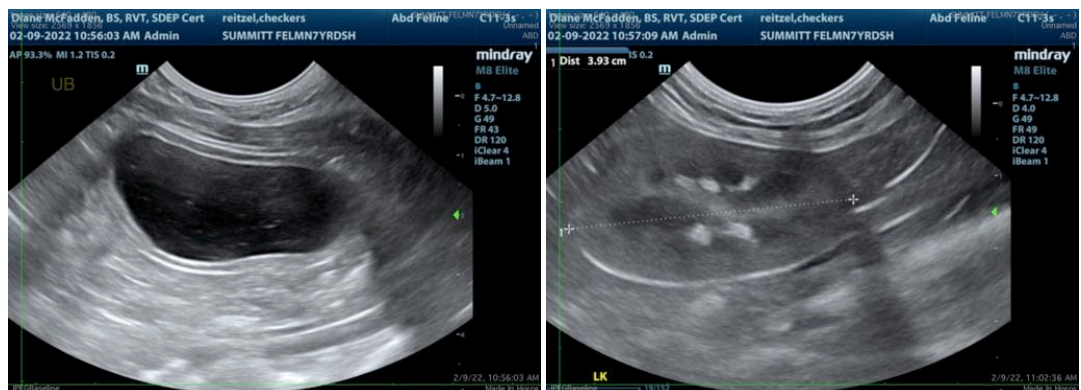
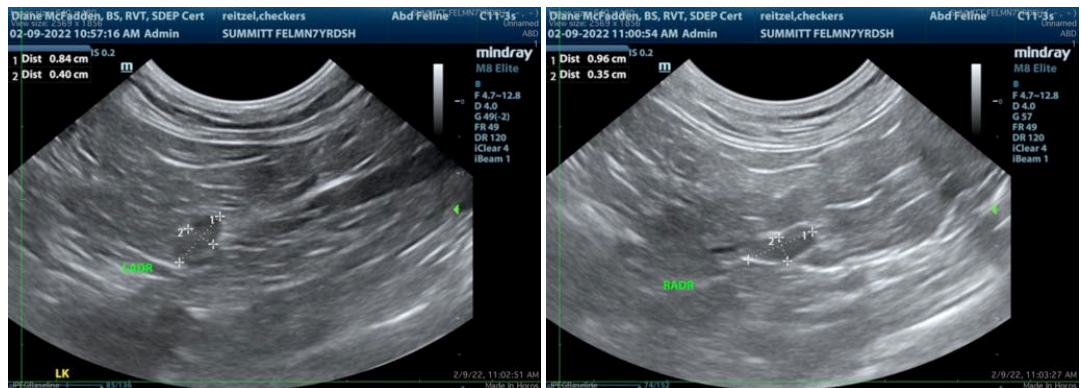
Dr. Vogler

INVOICE

95950

DATE

2/9/22



The information and recommendations provided are based on the images presented by the referring veterinarian/sonographer. No evaluation can be communicated regarding pathology that was not visible in the image/video clips provided.

Thank you for this referral. If the clinical or image interpretation does not parallel your findings or if I can be of any further assistance please contact me.

Beth Johnson, DVM DACVIM

Beth.Johnson@SonoPath.com



PATIENT

Checkers Reitzel

SPECIES

Feline

BREED

Domestic Shorthair

SEX

Neutered male

AGE

7 years

WEIGHT

7.3 lbs

INTERPRETED BY

Beth Johnson, DVM
DACVIM

**IMAGING
PERFORMED BY**

Diane McFadden,
RVT

HOSPITAL NAME

Summit Dog and Cat
Hospital

REFERRING VET

Dr. Vogler

INVOICE

95950

DATE

2/9/22