



PATIENT

Bob Florkowski

PRESENTING CLINICAL SIGNS

3yo FS DSH that presented for vomiting intermittently (sometimes once daily, sometimes several times daily) for the previous 2 weeks. Has lost ~1.8lbs in the last 2.5 years since we had seen her last. Bloodwork was unremarkable. Ultrasound to rule out further causes of vomiting and weight loss.

SPECIES

Feline

ULTRASONOGRAPHIC EXAMINATION OF THE ABDOMEN

BREED

Domestic Shorthair

Urinary System

Urinary bladder is moderately distended with anechoic contents. It has normal uniform wall thickness (< 0.2 cm). No masses or cystoliths are observed.

SEX

Spayed Female

Left kidney is normal in size (3.55 cm) and shape with smooth peripheral margination. A normal 1:3 cortex to medulla ratio is maintained. The medulla and cortices are uniform in texture with some mild increased echogenicity and mild loss of corticomedullary distinction. There is no evidence of pyelectasia, mineral or infarcts observed.

AGE

13 years

Right kidney is normal in size (3.44 cm) and shape with smooth peripheral margination. A normal 1:3 cortex to medulla ratio is maintained. The medulla and cortices are uniform in texture with some mild increased echogenicity and mild loss of corticomedullary distinction. Non-obstructive nephrolithiasis was noted. There is no evidence of pyelectasia or infarcts observed.

WEIGHT

8 lbs

Adrenal Glands

INTERPRETED BY

Beth Johnson, DVM
DACVIM

Left adrenal gland is normal in size (0.3 cm thick), shape and contour. Corticomedullary structure is unremarkable.

Right adrenal gland is normal in size (0.37 cm thick), shape and contour. Corticomedullary structure is unremarkable.

IMAGING PERFORMED BY

Dr. Harris

Spleen

Spleen is subjectively large in size with normal smooth margins. The parenchyma is homogenous in echotexture, but is diffusely hyperechoic. No focal nodules or masses are observed. Splenic vasculature appears normal. The head of the spleen is not visible in these images.

HOSPITAL NAME

TotalBond VH

REFERRING VET

Dr. Harris

Liver

Liver is subjectively normal in size. Margins are sharp and smooth. It has normal homogenous echotexture and normal echogenicity. Just caudal to the right liver there is a discrete, round, homogenous, hyperechoic mass that measures 1.7 cm in diameter and appears to be associated with the liver; however, the head of the spleen wrapping around cannot be ruled out. Visible vasculature appears normal. Gallbladder is mildly distended with anechoic bile and gravity dependent echogenic sediment. The wall is smooth without visible thickening. There is no evidence of common bile duct dilation. There is no evidence of effusion or inflammation.

INVOICE

95931

DATE

2/9/22



PATIENT	Gastrointestinal
Bob Florkowski	The visible gastric wall is normal in thickness (canine < 0.5 cm and feline < 0.4 cm). The stomach is empty.
SPECIES	The small intestines are normal in wall thickness. Normal layering is maintained except for a diffusely disproportionately thick muscularis layer relative to mucosa. Small intestinal motility appears adequate (1-3 contractions per min). There are no luminal contents noted within small intestines.
Feline	Colon is normal in wall thickness (< 0.2 cm) and layering.
BREED	
Domestic Shorthair	Pancreas
SEX	Pancreas has normal homogenous echotexture and is normal in echogenicity and smooth margination. There is no evidence of peripancreatic inflammation.
Spayed Female	
AGE	Free Abdomen
13 years	Lymph nodes are normal with no observed enlargement.
WEIGHT	ULTRASONOGRAPHIC FINDINGS
8 lbs	Primary Findings
INTERPRETED BY	Hyperechoic splenomegaly, which can be associated with congestion caused by sedation if sedated, but can also be associated with diffuse infiltrative disease. Benign condition such as extramedullary hematopoiesis, lymphoid hyperplasia, etc. as well as infiltrative neoplastic disease such as round cell neoplasia should be considered. The mildly hyperechoic parenchyma can sometimes be suggestive of mast cell tumor.
Beth Johnson, DVM DACVIM	Discrete hyperechoic mass at the caudal edge of the liver. Differentials for which include primary hepatic neoplasia versus round cell neoplasia or less likely metastatic disease. The mass may be the head of the spleen wrapping around or possibly an enlarged lymph node cannot be ruled out. Definitive origin of the mass cannot be determined.
IMAGING PERFORMED BY	Cholecystic debris of unknown clinical significance, which can be seen with biliary stasis from fasting or illness. However, can also be associated with hepatobiliary disease in cats and should be interpreted in combination with clinical signs such as nausea, inappetence, cranial abdominal discomfort and/or laboratory changes such as increased ALKP and/or increased total bilirubin.
Dr. Harris	
HOSPITAL NAME	Age related kidney change – This finding is expected/consistent with age-related mild degenerative disease and should be interpreted clinically in combination with laboratory changes.
TotalBond VH	Nephrolithiasis in the right kidney, non-obstructive.
REFERRING VET	Thick muscularis – This finding has been reported in cats with infiltrative bowel disease including both benign inflammatory disease as well as infiltrative neoplasia such as lymphoma.
Dr. Harris	
INVOICE	
95931	
DATE	
2/9/22	



PATIENT

Bob Florkowski

SPECIES

Feline

BREED

Domestic Shorthair

SEX

Spayed Female

AGE

13 years

WEIGHT

8 lbs

INTERPRETED BY

Beth Johnson, DVM
DACVIM

IMAGING PERFORMED BY

Dr. Harris

HOSPITAL NAME

TotalBond VH

REFERRING VET

Dr. Harris

INVOICE

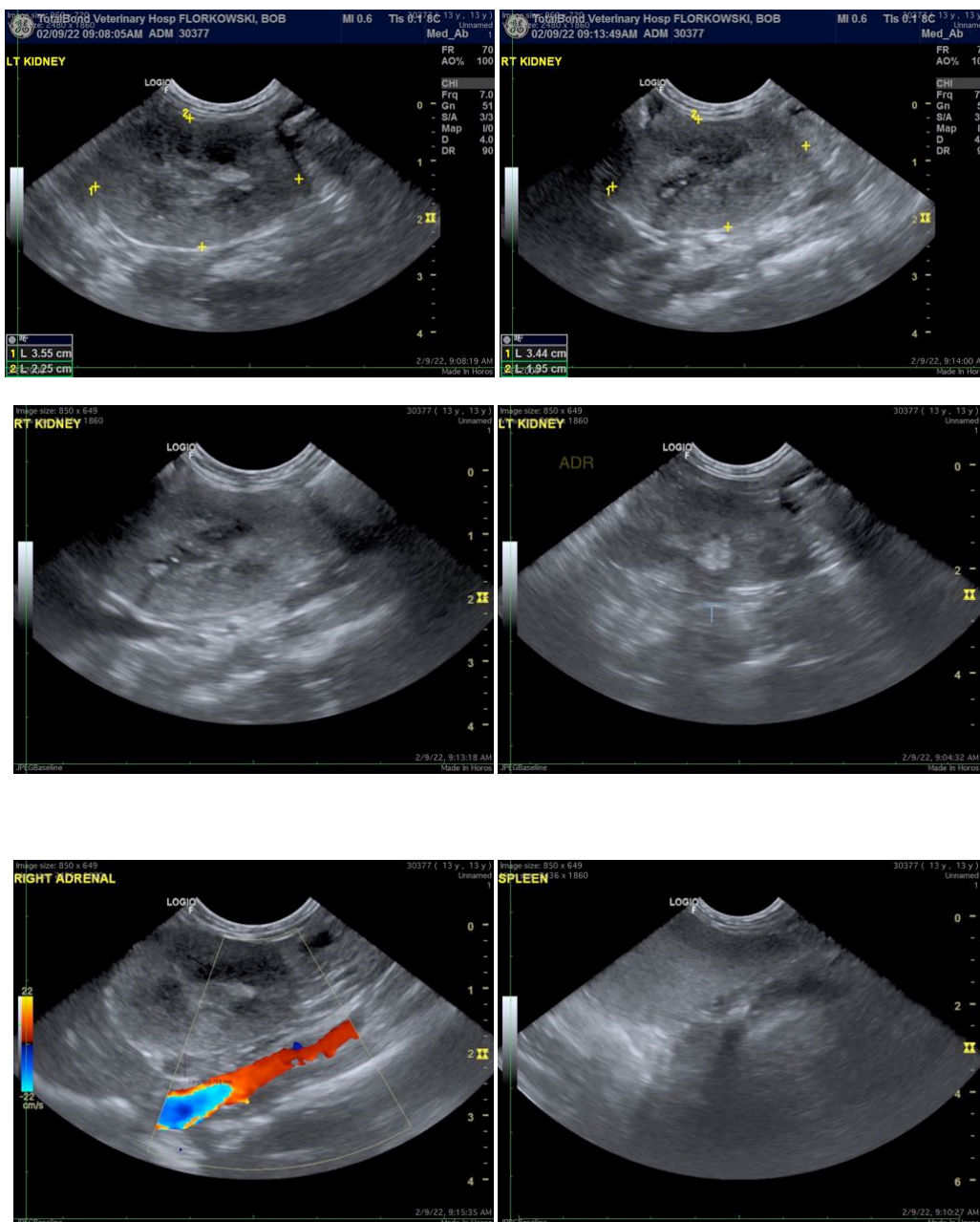
95931

DATE

2/9/22

INTERPRETATION OF THE FINDINGS & FURTHER RECOMMENDATIONS

Recommendations for this patient given the gastrointestinal signs as well as the eosinophilia and organomegaly include a gastrointestinal malabsorption panel including TLI, PLI, folate and cobalamin to Texas A&M GI laboratory to further assess the gastrointestinal tract and pancreas. FNA of the spleen as well as the mass caudal to the liver is recommended if the patient's coagulation status is appropriate. Recommendations are to pre medicate with Diphenhydramine prior to the aspirate in case this is infiltrative mast cell disease. In the meantime, given the eosinophilia empirical deworming with a 5 day course of Panacur is recommended as is a diet change to a novel or hydrolyzed protein diet as a eosinophilia can be associated with parasitic disease or food allergy. Ultimately if cytology does not reveal round cell neoplasia and clinical signs do not improve with diet change then biopsies of the intestines being sure to include the ileum if possible may be necessary to definitely diagnose the cause of the infiltrative process and guide appropriate therapy.





PATIENT

Bob Florkowski

SPECIES

Feline

BREED

Domestic Shorthair

SEX

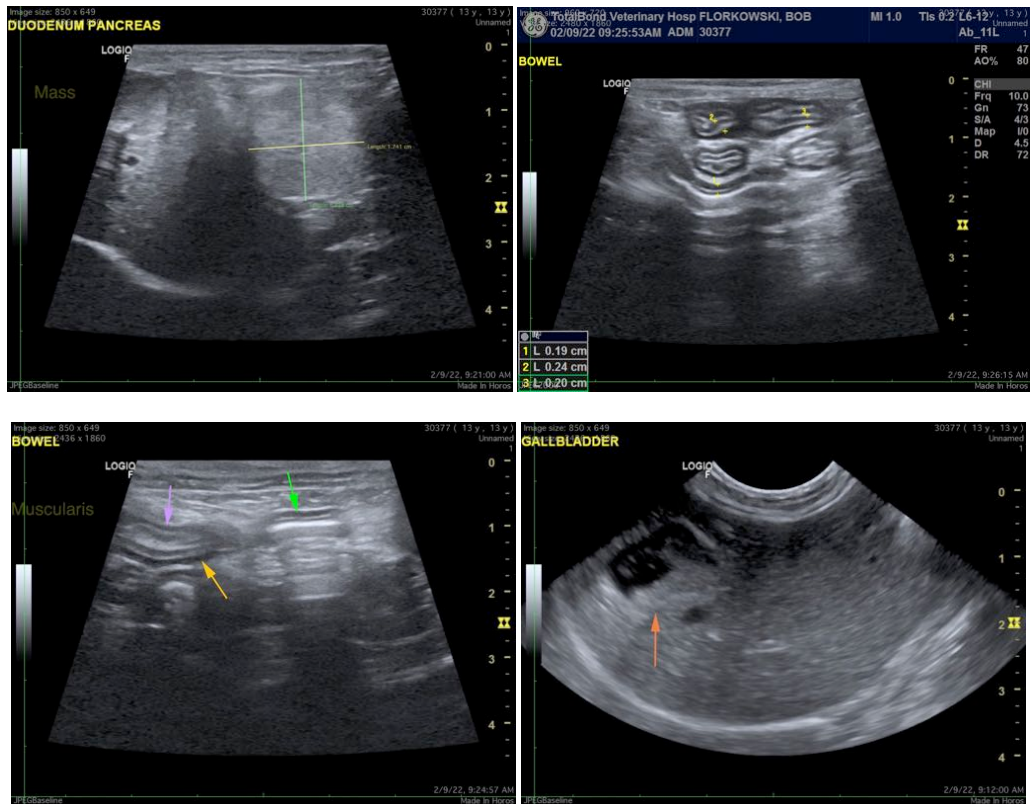
Spayed Female

AGE

13 years

WEIGHT

8 lbs



INTERPRETED BY

Beth Johnson, DVM
DACVIM

The information and recommendations provided are based on the images presented by the referring veterinarian/sonographer. No evaluation can be communicated regarding pathology that was not visible in the image/video clips provided.

IMAGING PERFORMED BY

Dr. Harris

Beth Johnson, DVM DACVIM

HOSPITAL NAME

TotalBond VH

Beth.Johnson@SonoPath.com

REFERRING VET

Dr. Harris

INVOICE

95931

DATE

2/9/22