



**PATIENT**

Loki Bisconti

**SPECIES**

Feline

**BREED**

DSH

**SEX**

Neutered Male

**AGE**

6 Years 6 Months

**WEIGHT**

13.09 Pounds

**INTERPRETED BY**

Beth Johnson, DVM  
DACVIM

**IMAGING PERFORMED BY**

Shari Reffi, CVT

**HOSPITAL NAME**

ACC Flanders

**REFERRING VET**

Dr. Hallihan

**INVOICE**

21050

**DATE**

2/7/23

**PRESENTING CLINICAL SIGNS**

History: Hx of regurg. and vomiting. Usually goes away after Tx w/ Cerenia inj. and Famotidine.

Abnormal PE/Chem/CBC/UA Results: U/A-cysto pending

**ULTRASONOGRAPHIC EXAMINATION OF THE ABDOMEN**

**Urinary System**

Urinary bladder is adequately distended. It has a normal uniform wall thickness. Contents include primarily anechoic fluid with occasional echogenic non-shadowing debris, most consistent with incidental suspended lipid in a cat, possibly combined with exfoliated cells, mucous and/or small blood clots. Both sterile inflammation as well as urinary tract infection can also present with echogenic debris. No masses or cystoliths are observed. The trigone and visible pelvic urethra are normal in thickness with a smooth mucosal surface.

Left kidney is normal in size (3.53 cm), shape and echogenicity. It has smooth peripheral margination. There is a normal 1:3 cortex to medulla ratio with appropriate corticomedullary distinction. There is no evidence of pyelectasia, mineral or infarcts observed.

Right kidney is normal in size (3.98 cm), shape and echogenicity. It has smooth peripheral margination. There is a normal 1:3 cortex to medulla ratio with appropriate corticomedullary distinction. There is no evidence of pyelectasia, mineral or infarcts observed.

**Adrenal Glands**

Left adrenal gland is normal in size (0.34 cm), shape and overall architecture, echogenicity and echotexture. Visible surrounding vasculature appears normal.

Right adrenal gland is normal in size (0.29 cm), shape and overall architecture, echogenicity and echotexture. Visible surrounding vasculature appears normal.

**Spleen**

Spleen is subjectively normal in size with a normal smooth capsular contour. Parenchyma is appropriately finely textured and homogenous with normal echogenicity relative to surrounding tissue (hyperechoic to liver). No focal nodules or masses are observed. Splenic vasculature appears normal.

**Liver**

Liver is subjectively normal in size with normal smooth curvilinear peripheral contour. Parenchyma is appropriately hypoechoic to the spleen in echogenicity and appropriately mildly coarse and homogenous in echotexture. No focal lesions are observed. Visible vasculature and biliary tree appear normal without distension or congestion.

Gallbladder is non-distended in size. The wall is smooth without visible thickening. Luminal contents are primarily anechoic. There is no evidence of cystic or common bile duct dilation.

**Gastrointestinal**

The visible stomach wall is normal in thickness and layering. The lumen of the stomach is empty with no evidence of obstruction, foreign material or infiltrative disease. Pyloric outflow tract appears patent.



**PATIENT**

Loki Bisconti

The visible small intestine demonstrates areas of thick muscularis layer relative to mucosa (disruption of the normal 1:3 muscularis:mucosa ratio). Small intestinal submucosa is slightly irregular, thick and hyperechoic, without evident loss of layering appreciated. The lumen of the small intestine is empty with no evidence of obstruction or foreign material.

**SPECIES**

Feline

The visible colon is normal in wall thickness and layering. Contents are consistent with normal formed feces and gas.

**Pancreas**

**BREED**

DSH

The observed pancreas appears appropriately isoechoic to surrounding omental fat. Visible capsule is smooth and normal in contour. Visible pancreatic parenchyma is homogenous and unremarkable. There is no visible pancreatic duct dilation. There is no evidence of active peripancreatic inflammation.

**SEX**

Neutered Male

**Free Abdomen**

There is no evidence of peritoneal effusion. There is no apparent lymphadenopathy. Mesenteric fat around the ileocecolic junction is mildly hyperechoic/enhanced.

**AGE**

6 Years 6 Months

**ULTRASONOGRAPHIC FINDINGS**

**Primary Findings**

- Inflammatory bowel disease (IBD) pattern with some mild focal peritonitis with some mild focal inflammation associated with bowel disease suspected – Thick muscularis has been reported with infiltrative bowel disease including both benign inflammatory disease as well as infiltrative neoplasia such as lymphoma. No aggressive lymphadenopathy, loss of layering, etc. is noted to make lymphoma more probable, but lymphoma cannot be definitively ruled out without tissue sampling.

**WEIGHT**

13.09 Pounds

**INTERPRETED BY**

Beth Johnson, DVM  
DACVIM

**Secondary Findings**

- Urinary bladder debris

**IMAGING PERFORMED BY**

Shari Reffi, CVT

**INTERPRETATION OF THE FINDINGS & FURTHER RECOMMENDATIONS**

If not already evaluated, a general metabolic health screen is recommended, including CBC chemistry panel and electrolytes, as is reportedly already pending, urinalysis and, if indicated based on urinalysis results, urine culture is recommended. If protein is present in an otherwise quiet sediment, protein quantification with a urine protein to creatinine ration is recommended.

**HOSPITAL NAME**

ACC Flanders

A gastrointestinal malabsorption panel (including cobalamin, folate, TLI and PLI) to Texas A&M GI Laboratory is recommended for further evaluation of GI and pancreatic function.

**REFERRING VET**

Dr. Hallihan

Ideally, biopsies of the GI tract, being sure to include ileum, if possible, are recommended to definitively diagnose and therefore manage the infiltrative bowel disease.

**INVOICE**

21050

If biopsies cannot be obtained, empirical therapies could include diet transition, if tolerated, to a hydrolyzed protein diet, knowing that some patients need trials with several different brands prior to finding a hydrolyzed protein diet that fits, empirical deworming with a 5 day course of Panacur, cobalamin supplementation (unless cobalamin level is evaluated and supplementation is not warranted) and prednisolone (if not contraindicated based on patient contraindications, co-morbidities, etc.).

**DATE**

2/7/23



**PATIENT**

Loki Bisconti

**SPECIES**

Feline

**BREED**

DSH

**SEX**

Neutered Male

**AGE**

6 Years 6 Months

**WEIGHT**

13.09 Pounds

**INTERPRETED BY**

Beth Johnson, DVM  
DACVIM

**IMAGING PERFORMED BY**

Shari Reffi, CVT

**HOSPITAL NAME**

ACC Flanders

**REFERRING VET**

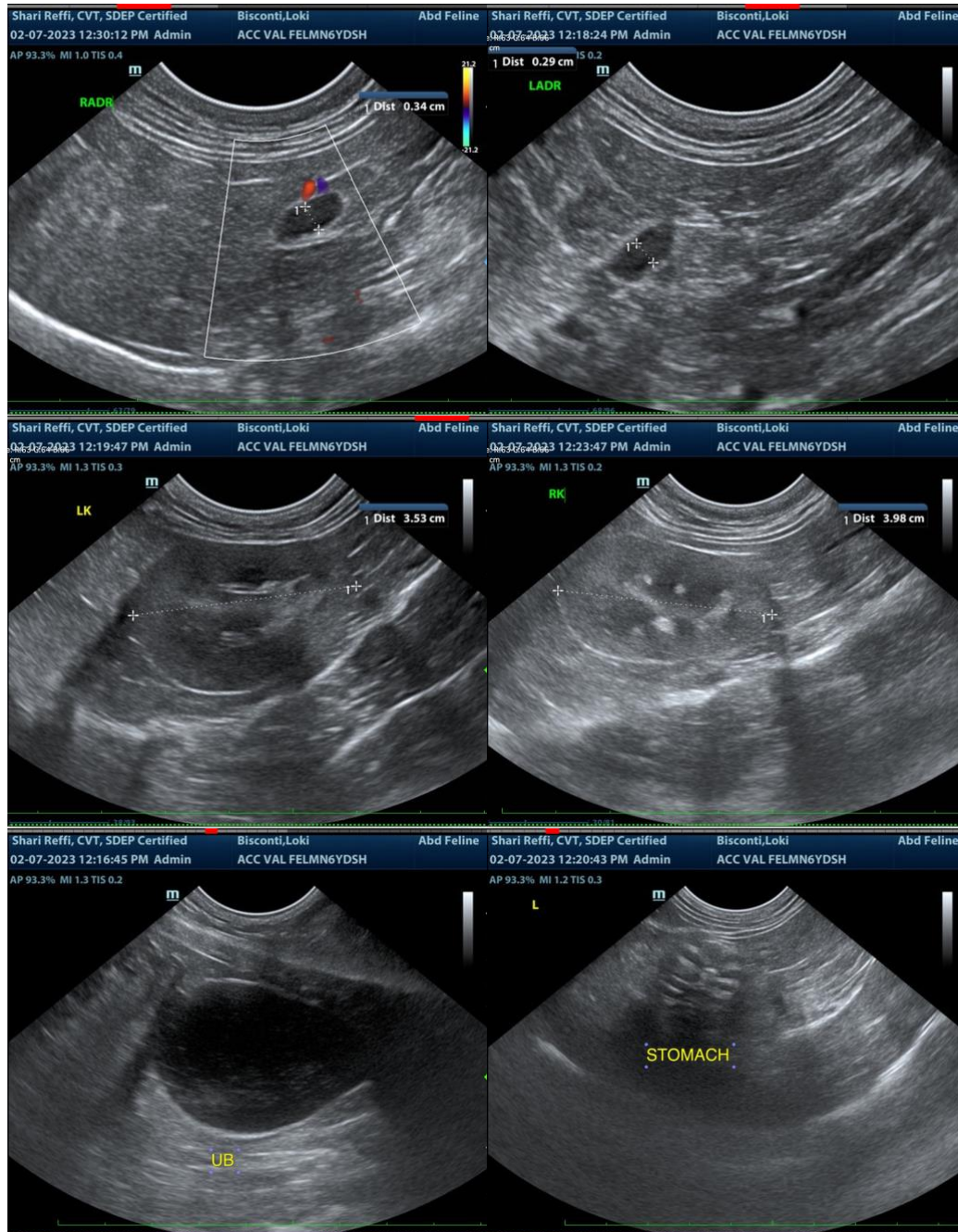
Dr. Hallihan

**INVOICE**

21050

**DATE**

2/7/23





**PATIENT**

Loki Bisconti

**SPECIES**

Feline

**BREED**

DSH

**SEX**

Neutered Male

**AGE**

6 Years 6 Months

**WEIGHT**

13.09 Pounds

**INTERPRETED BY**

Beth Johnson, DVM  
DACVIM

**IMAGING PERFORMED BY**

Shari Reffi, CVT

**HOSPITAL NAME**

ACC Flanders

**REFERRING VET**

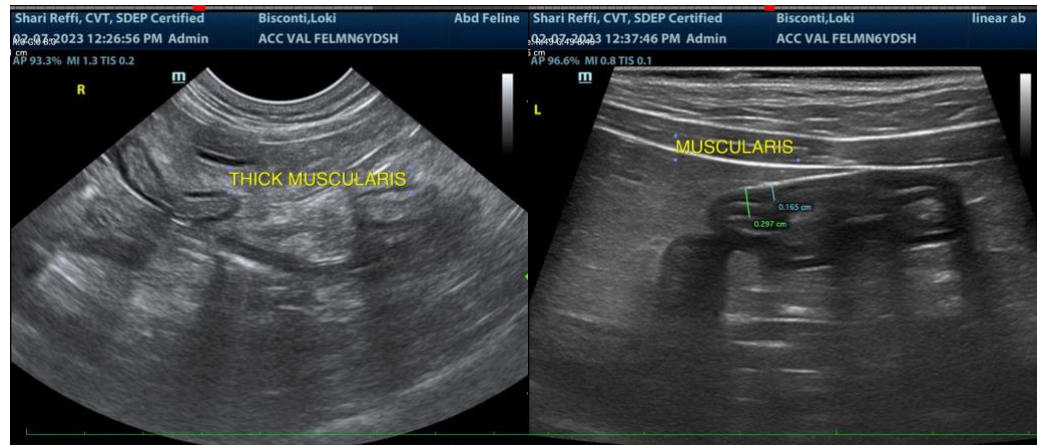
Dr. Hallihan

**INVOICE**

21050

**DATE**

2/7/23



The information and recommendations provided are based on the images presented by the referring veterinarian. No evaluation can be communicated regarding pathology that was not visible in the image/video clips provided.

Thank you for this referral. If the clinical or image interpretation does not parallel your findings or if I can be of any further assistance please contact me.

**Beth Johnson, DVM DACVIM**

Beth.Johnson@SonoPath.com