



PATIENT

Jingles Seitchik

SPECIES

Canine

BREED

Chihuahua X

SEX

Spayed Female

AGE

10 Years

WEIGHT

12.8 Pounds

INTERPRETED BY

Beth Johnson, DVM
DACVIM

IMAGING PERFORMED BY

Jessica Miller

HOSPITAL NAME

Millburn Vet Hospital

REFERRING VET

Dr. Turowsky

INVOICE

44811

DATE

2/7/23

PRESENTING CLINICAL SIGNS

Abdominal US recheck, hx of Cushing's and left hyperechoic adrenal nodules
Abnormal PE/Chem/CBC/UA Results: ALT 440, ALP 282, ACTH stim: Pre 3.5, Post 5.9

ULTRASONOGRAPHIC EXAMINATION OF THE ABDOMEN

Urinary System

The urinary bladder is moderately distended with anechoic contents. No masses, inflammatory changes, echogenic sediment or cystoliths are observed. The urinary bladder, trigone and visible pelvic urethra are normal in thickness with a smooth mucosal surface.

The right kidney is normal in size (5.02 cm), shape and echogenicity. It has smooth peripheral margination. There is a normal 1:3 cortex to medulla ratio with appropriate corticomedullary distinction. There is no evidence of pyelectasia, mineral or infarcts observed. Multiple cortical cysts are noted.

The left kidney is normal in size (4.4 cm), shape and echogenicity. It has smooth peripheral margination. There is a normal 1:3 cortex to medulla ratio with appropriate corticomedullary distinction. There is no evidence of pyelectasia, mineral or infarcts observed. Multiple cortical cysts are noted.

Adrenal Glands

Adrenal glands are plump/swollen in size. Normal shape and contour are maintained without evidence of capsular invasion. Corticomedullary structure is unremarkable. Visible surrounding vasculature appears normal. In the left adrenal gland, three focal hyperechoic nodules are noted in the cranial pole. The nodules do not disrupt normal shape and/or architecture.

The left adrenal gland measures 2.98 cm long x 1.32 cm at the cranial pole and 0.72 cm at the caudal pole. The right adrenal gland measures 2.55 cm long x 1.46 cm at the cranial pole and 0.50 cm at the caudal pole.

Spleen

The spleen is subjectively normal in size with a normal smooth capsular contour. Parenchyma is appropriately finely textured and homogenous with normal echogenicity relative to surrounding tissue (hyperechoic to liver). No focal nodules or masses are observed. Splenic vasculature appears normal.

Liver

Liver is subjectively enlarged (swollen contour) without disruption of architecture. It has a normal homogenous echotexture. Parenchyma is diffusely hyperechoic characterized by less prominent than normal portal vein walls and increased echogenicity relative to the spleen and falciform fat. No focal lesions are observed. Visible vasculature and biliary tree appear normal without distension or congestion.

The gallbladder is non-distended in size. The wall is smooth without visible thickening. Luminal contents are primarily anechoic. There is a small echogenic density near the neck of the gallbladder that may be some non-shadowing mineral debris/sand versus a non-shadowing cytolith versus a small benign polyp. There is no evidence of cystic or common bile duct dilation.

Gastrointestinal

The stomach wall is normal in thickness (canine < 0.5 cm and feline < 0.4 cm) and layering. The lumen of the stomach is empty with no evidence of obstruction, foreign material or infiltrative disease. Pyloric outflow tract appears patent.



PATIENT

Jingles Seitchik

The visible small intestines are normal in wall thickness and layering (canine duodenum < 0.5 cm and feline duodenum < 0.4 cm; other < 0.3 cm). Small intestinal motility appears adequate (1-3 contractions per min). The lumen of the small intestine is empty with no evidence of obstruction, foreign material or infiltrative disease.

SPECIES

Canine

The visible colon is normal in wall thickness (< 0.2 cm) and layering. Contents are consistent with normal formed feces and gas.

BREED

Pancreas

Chihuahua X

The pancreatic parenchyma is appropriately isoechoic to surrounding tissue. Visible capsule is smooth and normal in contour. There is no visible pancreatic duct dilation. There is no evidence of active peripancreatic inflammation.

SEX

Spayed Female

Free Abdomen

AGE

10 Years

There is no evidence of free peritoneal effusion noted in these images.

There is no apparent lymphadenopathy noted in these images.

PRIMARY FINDINGS

WEIGHT

12.8 Pounds

- **Bilateral adrenomegaly** - consistent with this patient's reported history of hyperadrenocorticism, and likely represents pituitary dependent hyperadrenocorticism. The appearance of the hyperechoic adrenal nodules has not changed and is most consistent with benign change such as a myelolipoma or benign mineral versus other. Bilateral adrenal adenomas versus adrenal hyperplasia is possible but considered less likely. The overall appearance of the adrenal glands is relatively static to the previous scan.
- **Hyperechoic hepatomegaly** - This appearance is non-specific and most consistent with a benign steroid (endocrine) or vacuolar hepatopathy or reactive or idiopathic hepatopathy. Inflammatory and/or infiltrative disease (such as round cell neoplasia) are also possible but considered less likely.
- **Small incidental density within the gallbladder neck** - Believed to most likely be a benign polyp versus potentially a non-shadowing small cholecystolith or debris and does not appear obstructive.

INTERPRETED BY

Beth Johnson, DVM
DACVIM

IMAGING PERFORMED BY

Jessica Miller

HOSPITAL NAME

Millburn Vet Hospital

SECONDARY FINDINGS

- Multiple bilateral renal cortical cysts

REFERRING VET

Dr. Turowsky

INTERPRETATION OF THE FINDINGS & FURTHER RECOMMENDATIONS

INVOICE

44811

These ultrasound findings are similar to the previous scan and are consistent with hyperadrenocorticism. Given the liver enzyme pattern, which is more of a hepatocellular injury pattern than a cholestatic pattern, a concurrent hepatopathy could be considered, and testing for Leptospirosis is warranted, as is potentially a fine needle aspirate of the liver if patient's coagulation status is appropriate.

DATE

2/7/23

Beyond that, additional recommendations are dependent on current treatment regimen, clinical signs, etc., which is unknown.



PATIENT

Jingles Seitchik

SPECIES

Canine

BREED

Chihuahua X

SEX

Spayed Female

AGE

10 Years

WEIGHT

12.8 Pounds

INTERPRETED BY

Beth Johnson, DVM
DACVIM

IMAGING PERFORMED BY

Jessica Miller

HOSPITAL NAME

Millburn Vet Hospital

REFERRING VET

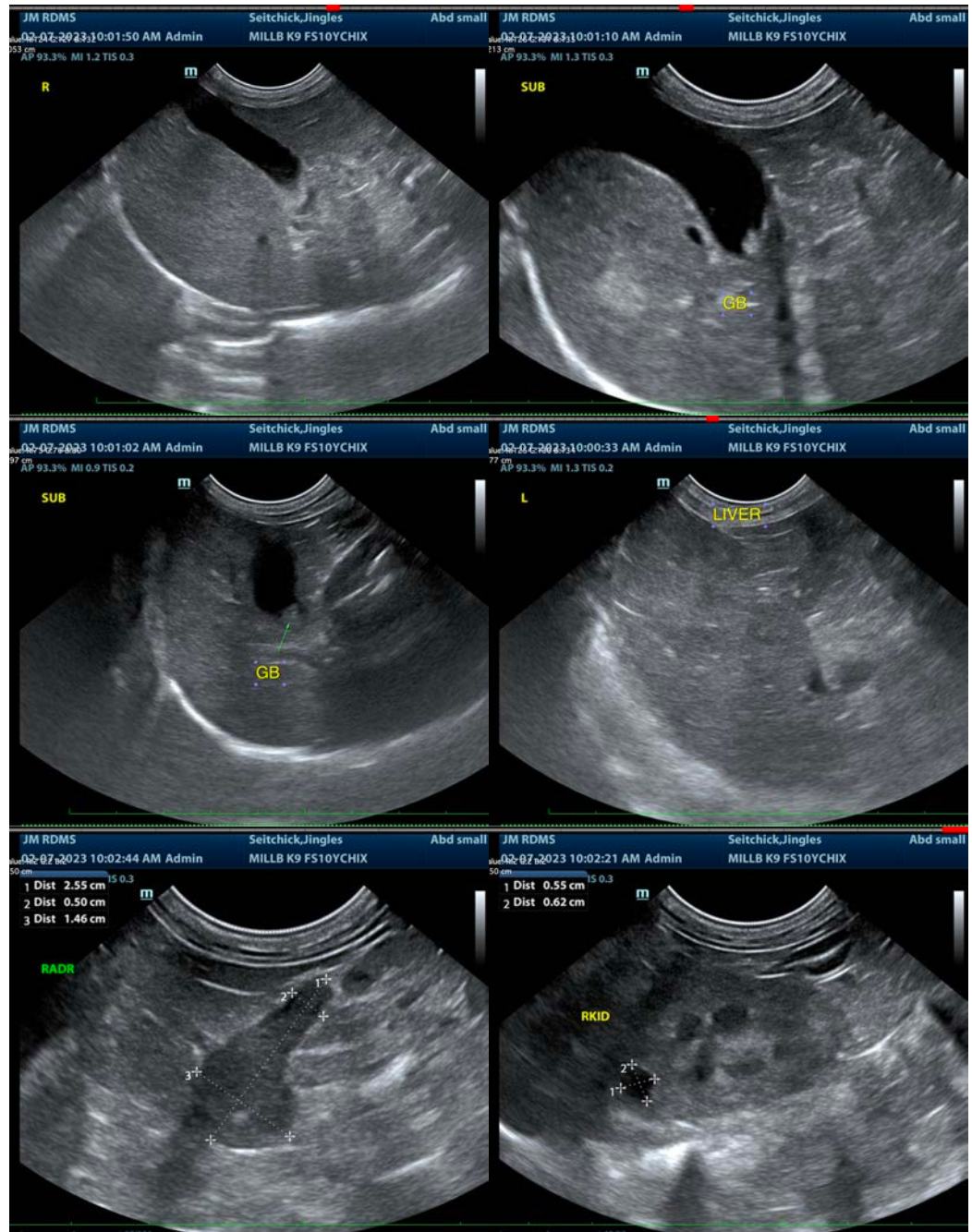
Dr. Turowsky

INVOICE

44811

DATE

2/7/23





PATIENT

Jingles Seitchik

SPECIES

Canine

BREED

Chihuahua X

SEX

Spayed Female

AGE

10 Years

WEIGHT

12.8 Pounds

INTERPRETED BY

Beth Johnson, DVM
DACVIM

IMAGING PERFORMED BY

Jessica Miller

HOSPITAL NAME

Millburn Vet Hospital

REFERRING VET

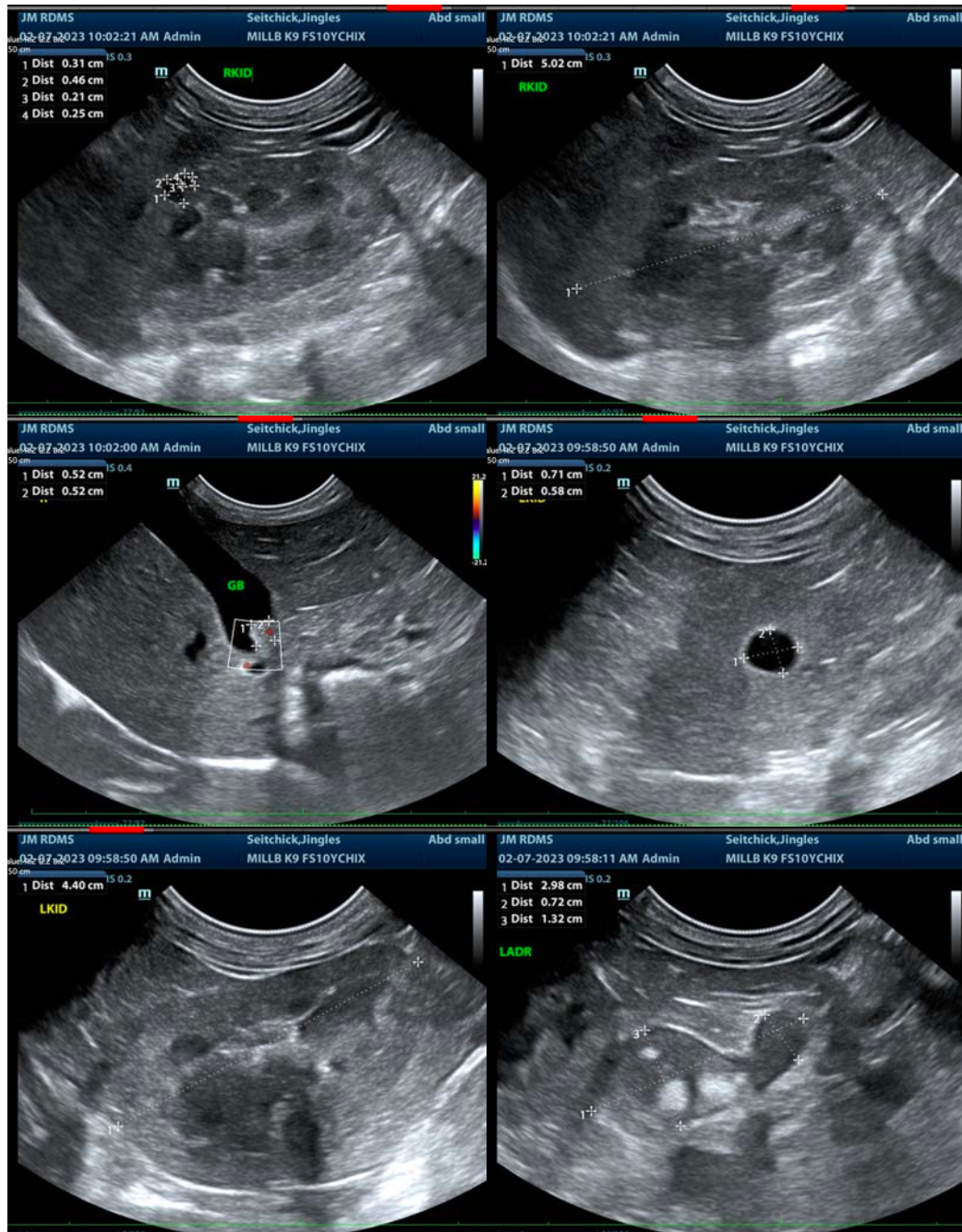
Dr. Turowsky

INVOICE

44811

DATE

2/7/23



The information and recommendations provided are based on the images presented by the referring veterinarian/sonographer. No evaluation can be communicated regarding pathology that was not visible in the image/video clips provided.

Thank you for this referral. If the clinical or image interpretation does not parallel your findings or if I can be of any further assistance please contact me.

Beth Johnson, DVM, DACVIM
Beth.Johnson@sonopath.com