

IMAGING PERFORMED BY

IntraPet.com



SonoPath

Clinical Sonography & Telecytology

EDUCATIONAL TELECONSULTATION SERVICES™

1-800-838-4268 info@sonopath.com SonoPath.com

DATE PRESENTING CLINICAL SIGNS

2/7/23 2 weeks ago decreased weight noted PE down 2 lbs. BW diagnosed hyperthyroidism, lost 1 lb. in past 2 weeks now abdominal intestinal mass palpated.

PATIENT

Jasper Jude Randle

Current Medications: None listed.
Lab Results: Hyperthyroidism.
Radiographs: Suspect intestinal mass, chest clear.
Date of Previous IntraPet Ultrasound: No previous.
Sedation: Not required to complete full diagnostic ultrasound.
Stat Report: Not requested.
Imaging Performed By: Andi Parkinson, BS, RDMS.

SPECIES

Feline

BREED

DLH

SEX

Neutered Male

AGE

1/1/10

WEIGHT

8lb 5 oz

INTERPRETED BY

Beth Johnson, DVM
DACVIM

HOSPITAL NAME

Chadwell AH

REFERRING VET

Dr. Gold

INVOICE

44809

ULTRASONOGRAPHIC EXAMINATION OF THE ABDOMEN

Urinary System

The urinary bladder is moderately distended with anechoic contents. No masses, inflammatory changes, echogenic sediment or cystoliths are observed. The urinary bladder, trigone and visible pelvic urethra are normal in thickness with a smooth mucosal surface.

The right kidney is normal in size (3.33 cm), shape and echogenicity. It has smooth peripheral margination. There is a normal 1:3 cortex to medulla ratio with appropriate corticomedullary distinction. There is no evidence of pyelectasia, mineral or infarcts observed.

The left kidney is normal in size (3.51 cm), shape and echogenicity. It has smooth peripheral margination. There is a normal 1:3 cortex to medulla ratio with appropriate corticomedullary distinction. There is no evidence of pyelectasia, mineral or infarcts observed.

Adrenal Glands

The areas of the adrenal glands are examined without evident adrenal gland pathology.

Spleen

The spleen is subjectively normal in size with a normal smooth capsular contour. Parenchyma is appropriately finely textured and homogenous with normal echogenicity relative to surrounding tissue (hyperechoic to liver). No focal nodules or masses are observed. Splenic vasculature appears normal.

Liver

The liver is subjectively normal in size with normal smooth curvilinear peripheral contour. Parenchyma is appropriately hypoechoic to the spleen in echogenicity and appropriately mildly coarse and homogenous in echotexture. No focal lesions are observed. Visible vasculature and biliary tree appear normal without distension or congestion.

The gallbladder is non-distended in size. The wall is smooth without visible thickening. Luminal contents are primarily anechoic. There is no evidence of cystic or common bile duct dilation.

Gastrointestinal

The stomach wall is normal in thickness (canine < 0.5 cm and feline < 0.4 cm) and layering. The lumen of the stomach is empty with no evidence of obstruction, foreign material or infiltrative disease. Pyloric outflow tract appears patent.

The small bowel contains a large 8-11 cm long, apparent jejunal (but encompassing large portion of the ileum as well) mass characterized by a markedly thick, hypoechoic wall measuring 2.0 cm thick with complete loss

of layering. The area is surrounded by enhanced hyperechoic mesenteric fat and a scant amount of anechoic free fluid.

The visible colon is normal in wall thickness (< 0.2 cm) and layering. Contents are consistent with normal formed feces and gas.

Pancreas

The pancreatic parenchyma is appropriately isoechoic to surrounding tissue. Visible capsule is smooth and normal in contour. There is no visible pancreatic duct dilation. There is no evidence of active peripancreatic inflammation.

Free Abdomen

A scant amount of anechoic free fluid is noted adjacent to the mass.

Mesenteric/jejunal lymph nodes are enlarged with swollen irregular capsular contour and loss of normal length to width ratio (rounded in shape). Nodes are hypoechoic with loss of normal parenchymal detail.

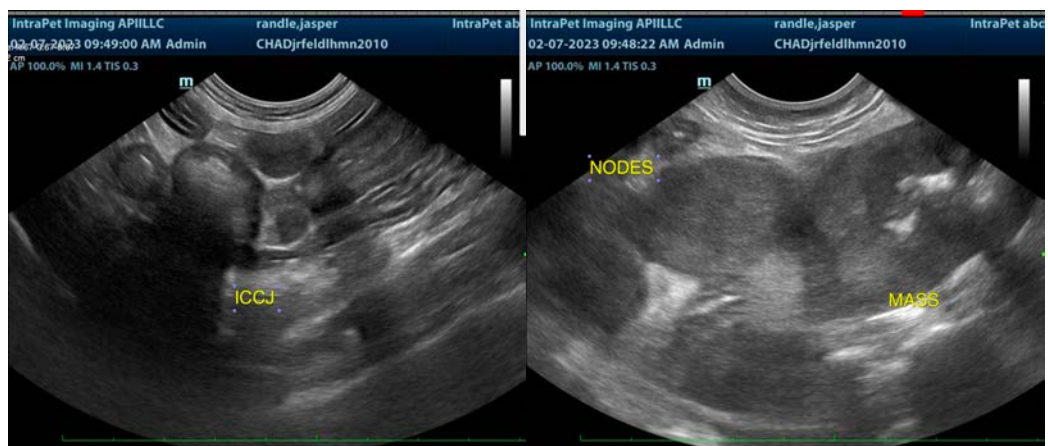
ULTRASONOGRAPHIC FINDINGS

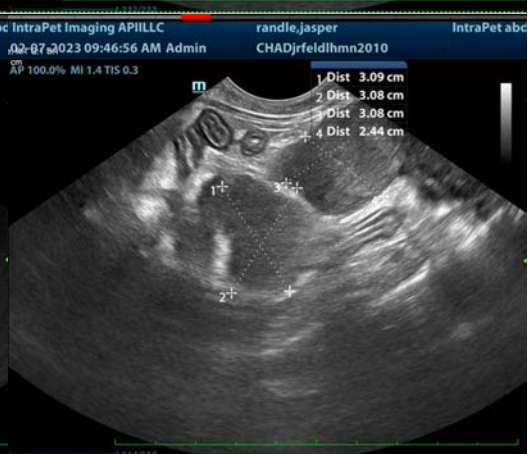
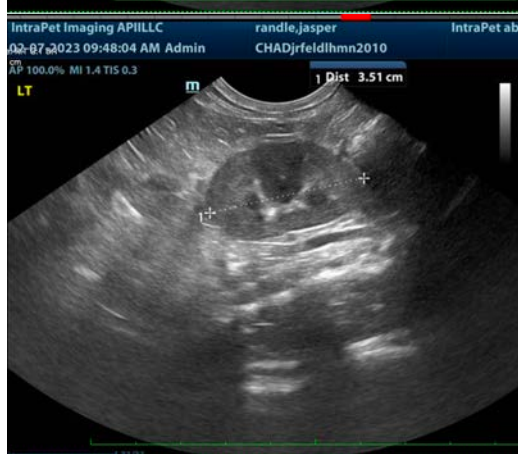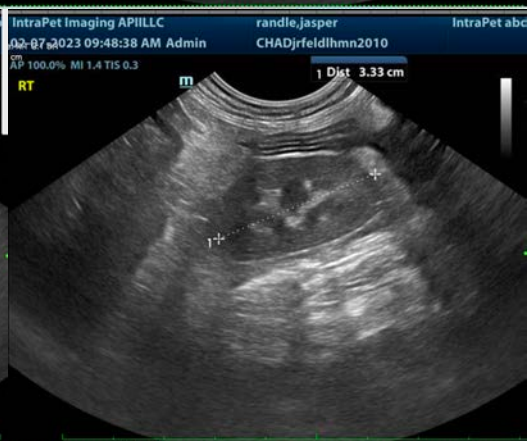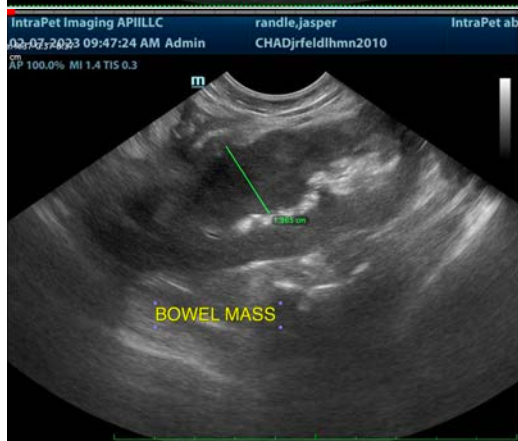
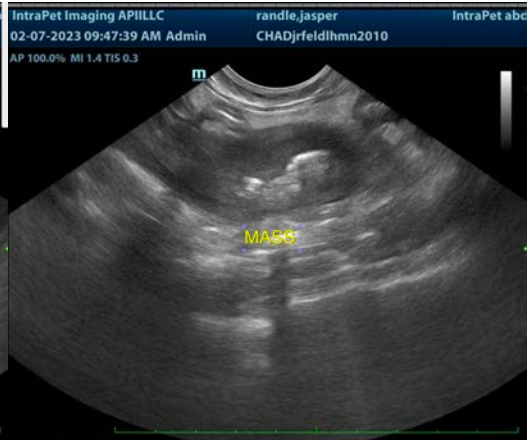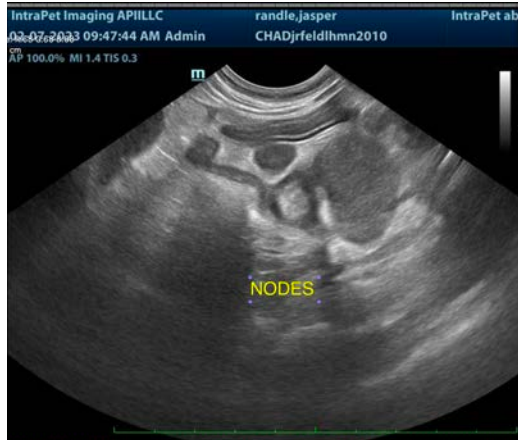
- **Small bowel/jejunal (and ileal) mass** – Most concerning for infiltrative neoplasia such as lymphoma versus other.
- **Aggressive mesenteric/jejunal lymph nodes** – most consistent with infiltrative round cell or metastatic neoplasia. A benign aggressive inflammatory response cannot be ruled out without tissue sampling +/- culture.

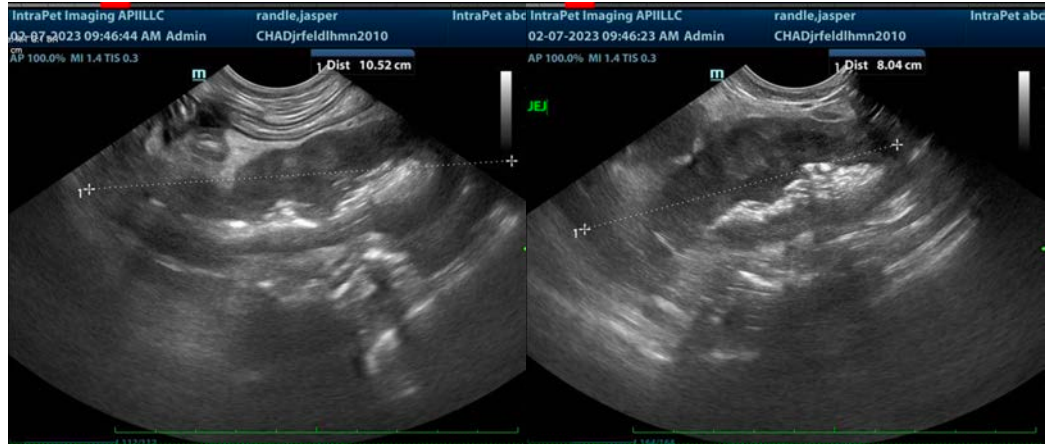INTERPRETATION OF THE FINDINGS & FURTHER RECOMMENDATIONS

A fine needle aspirate of the bowel mass and/or enlarged lymph nodes could be considered if patient's coagulation status is appropriate. However, given the evidence of a focal peritonitis surrounding the mass, an exploratory laparotomy for planned mass removal/resection and anastomosis may be warranted based on patient stability.

Given location, closely associated with and possibly involving ICCJ, if surgery is elected, consultation with a veterinary surgeon is recommended.







The information and recommendations provided are based on the images presented by the referring veterinarian/sonographer. No evaluation can be communicated regarding pathology that was not visible in the image/video clips provided.

Thank you for this referral. If the clinical or image interpretation does not parallel your findings or if I can be of any further assistance please contact me.

Beth Johnson, DVM, DACVIM
Beth.Johnson@sonopath.com