



PATIENT PRESENTING CLINICAL SIGNS

Hamilton Regina Diarrhea, vomiting and weight loss. Current med: had Depomedrol inj.

SPECIES Abnormal PE/Chem/CBC/UA Results: Decreased Na and chloride, all else WNL. T4 WNL.

Feline

ULTRASONOGRAPHIC EXAMINATION OF THE ABDOMEN

BREED *Urinary System*

DSH

Urinary bladder is adequately distended. It has a normal uniform wall thickness. Contents include primarily anechoic fluid with occasional echogenic non-shadowing debris, most consistent with incidental suspended lipid in a cat, possibly combined with exfoliated cells, mucous and/or small blood clots. Both sterile inflammation as well as urinary tract infection can also present with echogenic debris. No masses or cystoliths are observed. The trigone and visible pelvic urethra are normal in thickness with a smooth mucosal surface.

SEX

Neutered Male

AGE

6 Years 5 Months

Kidneys are normal in size with increased cortical echogenicity. Normal smooth peripheral margination and shape are maintained. There is a normal 1:3 cortex to medulla ratio with appropriate corticomedullary distinction. There is no evidence of pyelectasia, mineral or infarcts observed.

WEIGHT

8.1 Pounds

Infiltrative disease (infectious, neoplastic, etc.) or nephritis cannot be ruled out but is considered less likely. The right kidney measures 3.8 cm. The left kidney measures 3.49 cm.

Adrenal Glands

INTERPRETED BY

Beth Johnson, DVM
DACVIM

The area of the right adrenal gland is examined without evident adrenal pathology.

The left adrenal gland is normal in size (0.57 cm long x 0.23 cm thick), shape and contour. Corticomedullary structure is unremarkable. Visible surrounding vasculature appears normal.

Spleen

IMAGING PERFORMED BY

Kelly Vazquez

The spleen is subjectively normal in size with a normal smooth capsular contour. Parenchyma is appropriately finely textured and homogenous with normal echogenicity relative to surrounding tissue (hyperechoic to liver). No focal nodules or masses are observed. Splenic vasculature appears normal.

HOSPITAL NAME

Northvale Vet Clinic

Liver

The liver is subjectively normal in size with normal smooth curvilinear peripheral contour. Parenchyma is appropriately hypoechoic to the spleen in echogenicity and appropriately mildly coarse and homogenous in echotexture. No focal lesions are observed. Visible vasculature and biliary tree appear normal without distension or congestion.

REFERRING VET

Dr. Stefanie Simon

The gallbladder is non-distended in size. The wall is smooth without visible thickening. Luminal contents are primarily anechoic. There is no evidence of cystic or common bile duct dilation.

INVOICE

44806

Gastrointestinal

DATE

2/7/23

The visible stomach wall is normal in thickness and layering. The stomach is moderately distended with echogenic non-shadowing luminal contents and gas consistent with normal ingesta. There is no evidence of obstruction, foreign material or infiltrative disease. However, given the reported history of fasting, delayed gastric emptying could be considered. Soft (cloth) fluid absorbing foreign material is considered less likely but cannot be definitively ruled out. If clinical signs are consistent (vomiting, etc.), recommendations include supportive medical care, 24 hours fasting and re-image.

The visible small intestine demonstrates areas of thick muscularis layer relative to mucosa (disruption of the normal 1:3 muscularis:mucosa ratio). Small intestinal submucosa is slightly irregular, thick and



PATIENT

Hamilton Regina

hyperechoic, without evident loss of layering appreciated. The lumen is mildly distended with echogenic non-shadowing luminal contents and gas consistent with normal ingesta. There is no evidence of obstruction or foreign material noted.

SPECIES

Feline

The visible colon is normal in wall thickness (< 0.2 cm) and layering. Contents are consistent with normal formed feces and gas.

Pancreas

BREED

DSH

The pancreatic parenchyma is appropriately isoechoic to surrounding tissue. Visible capsule is smooth and normal in contour. There is no visible pancreatic duct dilation. There is no evidence of active peripancreatic inflammation.

SEX

Neutered Male

Free Abdomen

AGE

6 Years 5 Months

There is no apparent lymphadenopathy noted in these images.

PRIMARY FINDINGS

WEIGHT

8.1 Pounds

- **Inflammatory bowel disease (IBD) pattern** – Thick muscularis has been reported with infiltrative bowel disease including both benign inflammatory disease as well as infiltrative neoplasia such as lymphoma. No aggressive lymphadenopathy, loss of layering, etc. is noted to make lymphoma more probable, but lymphoma cannot be definitively ruled out without tissue sampling.
- Foreign material within the stomach cannot be definitively ruled out, but is considered much less likely, as the entire GI tract appears most consistent with post-prandial presentation. Delayed gastric emptying, potentially slowed motility, etc. may be present secondary to the suspected diffuse bowel disease.

INTERPRETED BY

Beth Johnson, DVM
DACVIM

SECONDARY FINDINGS

- Urinary bladder debris

IMAGING PERFORMED BY

Kelly Vazquez

INTERPRETATION OF THE FINDINGS & FURTHER RECOMMENDATIONS

HOSPITAL NAME

Northvale Vet Clinic

A gastrointestinal malabsorption panel (including cobalamin, folate, TLI and PLI) to Texas A&M GI Laboratory is recommended for further evaluation of GI and pancreatic function.

REFERRING VET

Dr. Stefanie Simon

Ideally, biopsies of the GI tract, being sure to include ileum if possible, are recommended to definitively diagnose and therefore manage the infiltrative bowel disease.

INVOICE

44806

If biopsies cannot be obtained, empirical therapies could include diet change, empirical deworming with a 5 day course of Panacur, cobalamin supplementation (unless cobalamin level is evaluated and supplementation is not warranted) and prednisolone (if not contraindicated based on patient contraindications, co-morbidities, etc.). Other supportive therapeutic considerations could include fiber supplementation, especially with large bowel diarrhea and/or a probiotic.

DATE

2/7/23

Additionally, if not recently evaluated, a urinalysis and, if indicated based on urinalysis results, urine culture are recommended. If protein is present in an otherwise quiet sediment, protein quantification with a urine protein to creatinine ratio is recommended.



PATIENT

Hamilton Regina

SPECIES

Feline

BREED

DSH

SEX

Neutered Male

AGE

6 Years 5 Months

WEIGHT

8.1 Pounds

INTERPRETED BY

Beth Johnson, DVM
DACVIM

IMAGING PERFORMED BY

Kelly Vazquez

HOSPITAL NAME

Northvale Vet Clinic

REFERRING VET

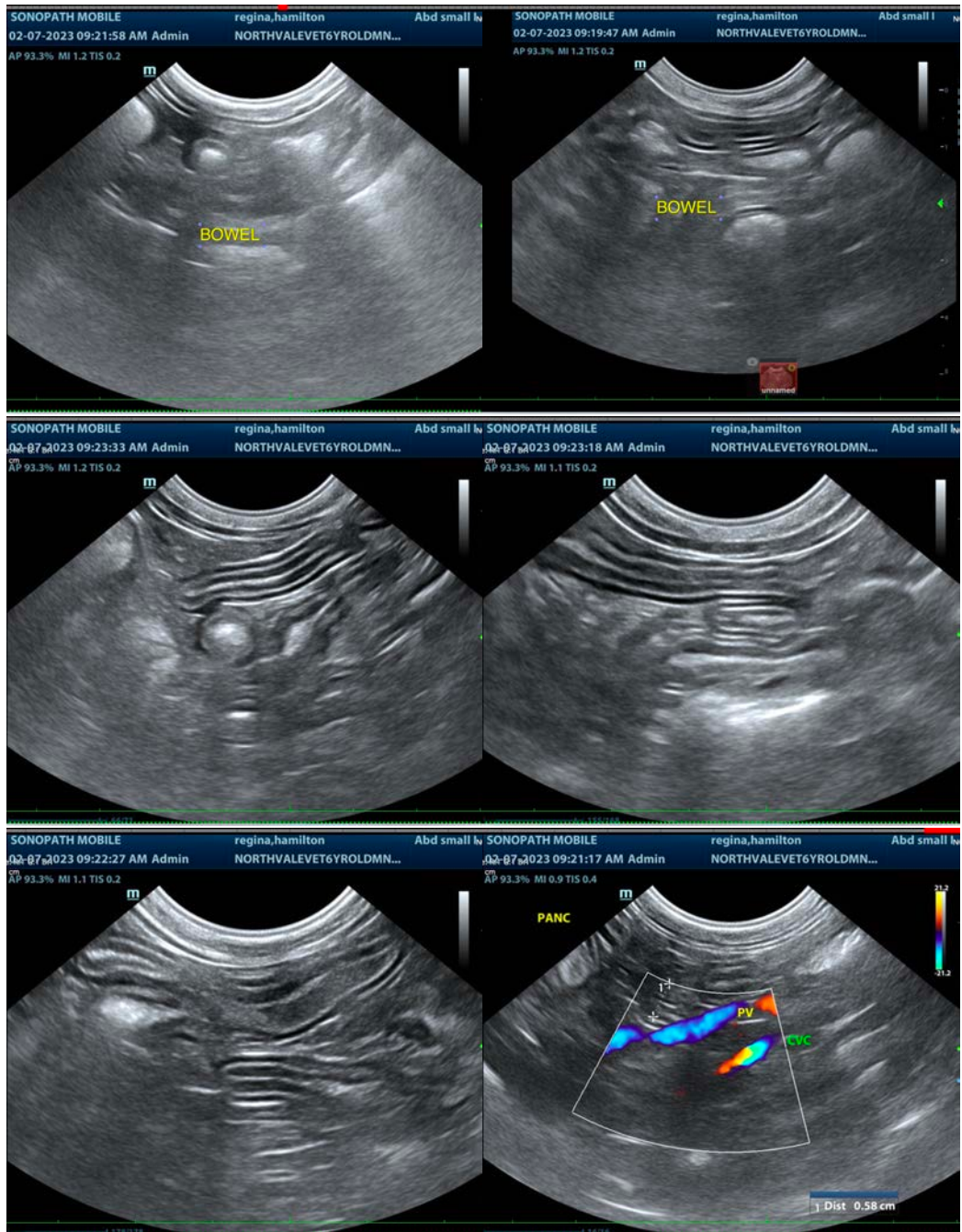
Dr. Stefanie Simon

INVOICE

44806

DATE

2/7/23





PATIENT

Hamilton Regina

SPECIES

Feline

BREED

DSH

SEX

Neutered Male

AGE

6 Years 5 Months

WEIGHT

8.1 Pounds

INTERPRETED BY

Beth Johnson, DVM
DACVIM

IMAGING PERFORMED BY

Kelly Vazquez

HOSPITAL NAME

Northvale Vet Clinic

REFERRING VET

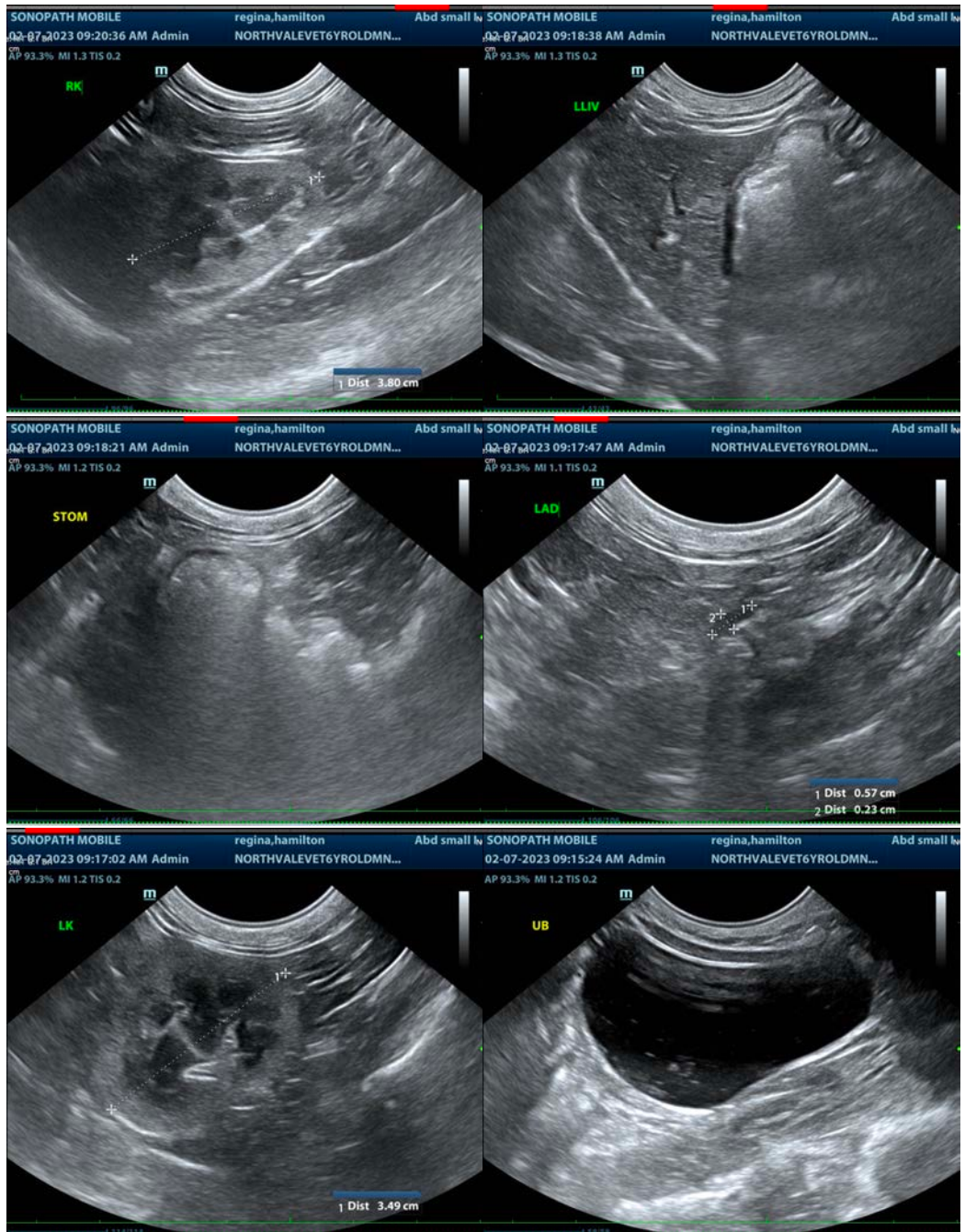
Dr. Stefanie Simon

INVOICE

44806

DATE

2/7/23



The information and recommendations provided are based on the images presented by the referring veterinarian/sonographer. No evaluation can be communicated regarding pathology that was not visible in the image/video clips provided.

Thank you for this referral. If the clinical or image interpretation does not parallel your findings or if I can be of any further assistance please contact me.

Beth Johnson, DVM, DACVIM
Beth.Johnson@sonopath.com