



**PATIENT PRESENTING CLINICAL SIGNS**

Bailey Erdos History: Low albumin 1.8, v/d, improved w/pred. Became anemic.

**SPECIES ULTRASONOGRAPHIC EXAMINATION OF THE ABDOMEN**

**Canine Urinary System**

Urinary bladder is adequately distended with anechoic contents. No masses, inflammatory changes, echogenic sediment or cystoliths are observed. The urinary bladder, trigone and visible pelvic urethra are normal in thickness with a smooth mucosal surface.

**BREED**

Yorkie

Kidneys are overall normal in size and shape with smooth peripheral margination. A normal 1:3 cortex to medulla ratio is maintained. The medulla and cortices are uniform in texture with some mild increased cortical echogenicity and mild loss of corticomedullary distinction, expected in this age patient. There is no evidence of pyelectasia or infarcts observed. Non-obstructive areas of mineralization/nephroliths are noted bilaterally. Small cortical cysts are noted bilaterally. The left measures 3.8 cm. The right kidney measures 4.7 cm.

**SEX**

Spayed Female

**AGE**

13.5 Years

**Adrenal Glands**

Left adrenal gland is plump/swollen in size (0.42 cm cranial pole and 1.0 cm caudal pole). Normal shape and contour are maintained without evidence of capsular invasion. Corticomedullary structure is unremarkable. Visible surrounding vasculature appears normal.

**WEIGHT**

8.7

Right adrenal gland is unable to be well visualized.

**Spleen**

Spleen is subjectively normal in size with a normal smooth capsular contour. Parenchyma is appropriately finely textured and homogenous with normal echogenicity relative to surrounding tissue (hyperechoic to liver). Multifocal well-demarcated hyperechoic homogenous nodules are noted. Splenic vasculature appears normal.

**INTERPRETED BY**

Beth Johnson, DVM  
DACVIM

**IMAGING PERFORMED BY**

Dr. Giuliani

**HOSPITAL NAME**

The Pet Hospital of  
Stratford

**REFERRING VET**

Dr. Claudia Giuliani

**Liver**

Liver is subjectively enlarged with mildly irregular margins. Parenchyma is heterogenous characterized by multiple poorly defined hypoechoic nodules within otherwise hyperechoic liver parenchyma. Visible vasculature and biliary tree appear normal without distension or congestion.

Gallbladder is non-distended in size. The wall is smooth without visible thickening. Luminal contents are primarily anechoic. There is no evidence of cystic or common bile duct dilation.

**Gastrointestinal**

The visible stomach wall is normal in thickness and layering. The lumen of the stomach is mildly distended with very echogenic reverberation artifact from intraluminal gas. There is no evidence of obstruction, foreign material or infiltrative disease; however, complete visualization of far wall is partially inhibited by gas. Pyloric outflow tract appears patent.

**INVOICE**

21037

Small intestine is diffusely mildly thick with a relatively thick mucosa compared to other layers. Normal wall layering is preserved; however, the mucosa is more echogenic than normal and contains hyperechoic striations perpendicular to the lumen. The lumen of the small intestine is empty with no evidence of obstruction or foreign material.

**DATE**

2/6/23



**PATIENT**

The visible colon is normal in wall thickness and layering. Contents are consistent with normal formed feces and gas.

Bailey Erdos

**Pancreas**

**SPECIES**

The observed pancreas appears appropriately isoechoic to surrounding omental fat. Visible capsule is smooth and normal in contour. Visible pancreatic parenchyma is homogenous and unremarkable. There is no visible pancreatic duct dilation. There is no evidence of active peripancreatic inflammation.

Canine

**BREED**

**Free Abdomen**

There is no evidence of peritoneal effusion. There is no apparent lymphadenopathy.

Yorkie

**ULTRASONOGRAPHIC FINDINGS**

**SEX**

**Primary Findings**

Spayed Female

- Lymphangiectasia – Small bowel findings are most consistent with lacteal dilation. These findings can be observed with protein-losing enteropathies caused by either primary lymphangiectasia or primary infiltrative inflammatory disease with secondary lymphangiectasia. Infiltrative neoplasia is possible but considered less likely. Histopathology is necessary to definitively determine underlying cause.

**AGE**

13.5 Years

- Heterogenous Liver – These changes are most consistent with benign processes such as nodular hyperplasia, steroid (vacuolar) hepatopathy, extramedullary hematopoiesis or possibly chronic inflammatory disease and less commonly infiltrative round cell or metastatic neoplasia.

**WEIGHT**

8.7

- Left adrenomegaly- This may be normal patient variant or stress response, however, could represent an adrenal adenoma or even adrenal hyperplasia secondary to pituitary dependent hyperadrenocorticism. This finding should be interpreted in combination with clinical signs of hyperadrenocorticism and/or other adrenal disease.

**INTERPRETED BY**

Beth Johnson, DVM  
DACVIM

**Secondary Findings**

**IMAGING**

**PERFORMED BY**

Dr. Giuliani

- Age-related kidney changes with nonobstructive dystrophic mineralization bilaterally and small bilateral cortical cysts
- Hyperechoic splenic nodules – most consistent with benign myelolipomas. Other differentials such as fibrosis or calcification caused by old hematomas or infarcts, chronic inflammation, granulomatous disease or metastatic disease cannot be ruled out, but are considered less likely.

**HOSPITAL NAME**

The Pet Hospital of  
Stratford

**REFERRING VET**

Dr. Claudia Giuliani

**INTERPRETATION OF THE FINDINGS & FURTHER RECOMMENDATIONS**

A gastrointestinal malabsorption panel (including cobalamin, folate, TLI and PLI) to Texas A&M GI Laboratory is recommended for further evaluation of GI and pancreatic function.

**INVOICE**

Ideally, biopsies of the GI tract are recommended to definitively diagnose and therefore manage the infiltrative bowel process.

21037

If biopsies cannot be obtained safely due to low albumin or patient stability, etc., empirical therapies could include diet change to an ultra-low-fat diet, empirical deworming with a 5 day course of Panacur, cobalamin supplementation (unless cobalamin level is evaluated and supplementation is not

**DATE**

2/6/23



**PATIENT**

Bailey Erdos

warranted) a probiotic and prednisolone (if not contraindicated based on patient contraindications, co-morbidities, etc.). Calcium monitoring, and supplementation, if necessary, is also recommended.

**SPECIES**

Canine

If not recently evaluated, to rule out concurrent proteinuria as a contributing factor to the reported hypoalbuminemia, urinalysis and (if indicated based on urinalysis results) urine culture are recommended. If protein is present in an otherwise quiet sediment, protein quantification with a urine protein to creatinine ration is recommended.

**BREED**

Yorkie

Addressing this patients suspected gastrointestinal disease should be the primary focus, however, once stabilized, only if clinical signs of hyperadrenocorticism are present, further testing may be warranted, beginning with a low dose dexamethasone suppression test. In the meantime, however, a blood pressure is recommended if not recently evaluated.

**SEX**

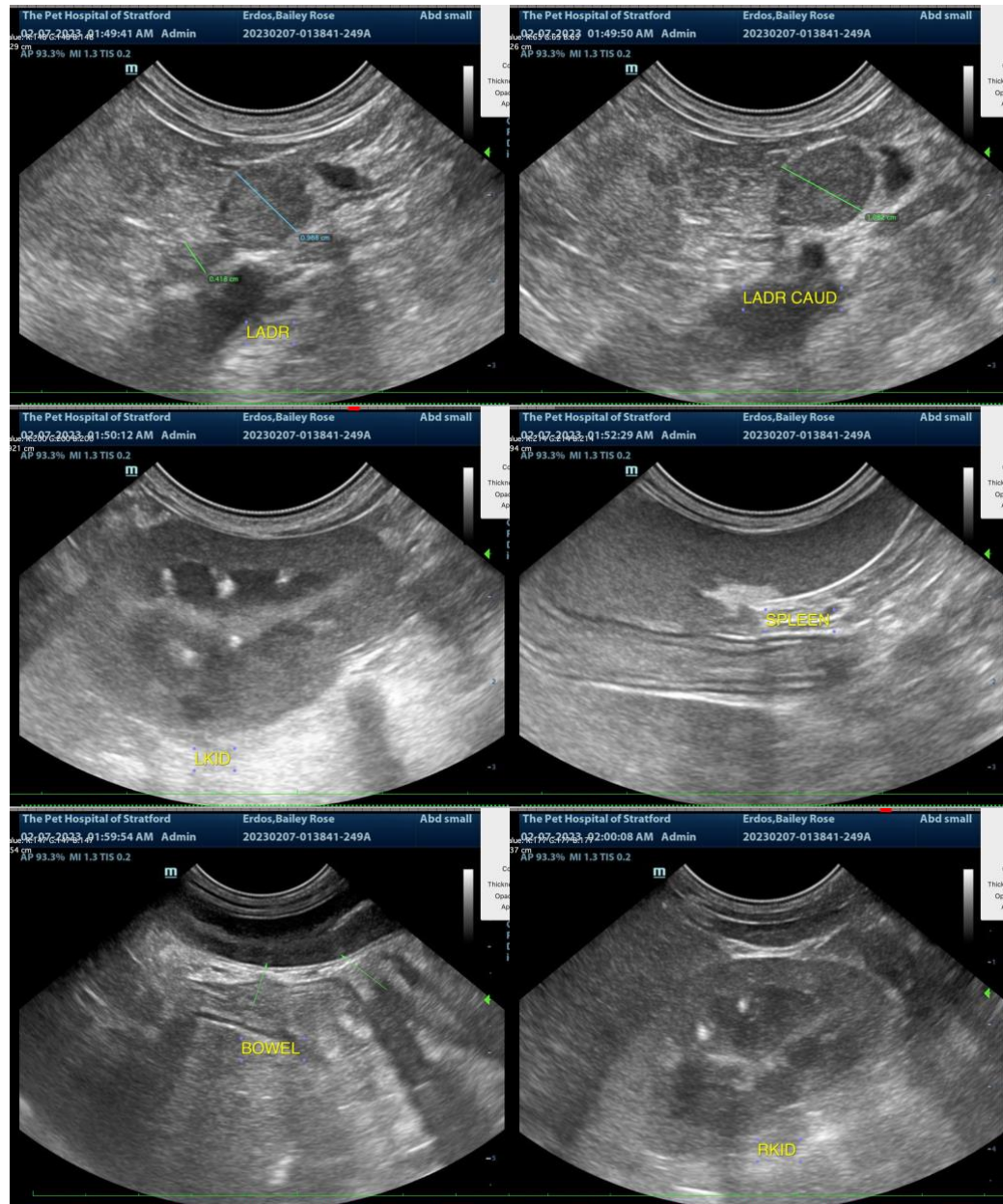
Spayed Female

**AGE**

13.5 Years

**WEIGHT**

8.7



**INTERPRETED BY**

Beth Johnson, DVM  
DACVIM

**IMAGING PERFORMED BY**

Dr. Giuliani

**HOSPITAL NAME**

The Pet Hospital of  
Stratford

**REFERRING VET**

Dr. Claudia Giuliani

**INVOICE**

21037

**DATE**

2/6/23



**PATIENT**

Bailey Erdos

**SPECIES**

Canine

**BREED**

Yorkie

**SEX**

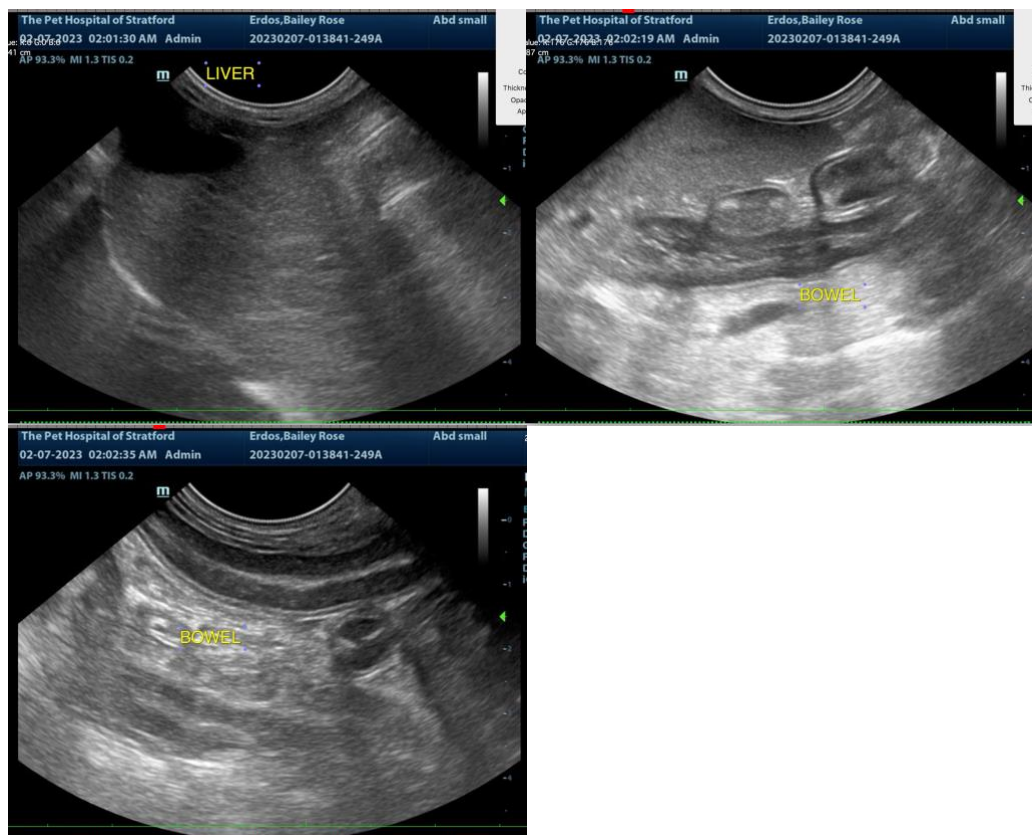
Spayed Female

**AGE**

13.5 Years

**WEIGHT**

8.7



**INTERPRETED BY**

Beth Johnson, DVM  
DACVIM

**IMAGING PERFORMED BY**

Dr. Giuliani

**HOSPITAL NAME**

The Pet Hospital of  
Stratford

**REFERRING VET**

Dr. Claudia Giuliani

**INVOICE**

21037

**DATE**

2/6/23

The information and recommendations provided are based on the images presented by the referring veterinarian. No evaluation can be communicated regarding pathology that was not visible in the image/video clips provided.

Thank you for this referral. If the clinical or image interpretation does not parallel your findings or if I can be of any further assistance please contact me.

**Beth Johnson, DVM DACVIM**

Beth.Johnson@SonoPath.com