SonoPath

Clinical Sonography & Telecytology

EDUCATIONAL TELECONSULTATION SERVICES™

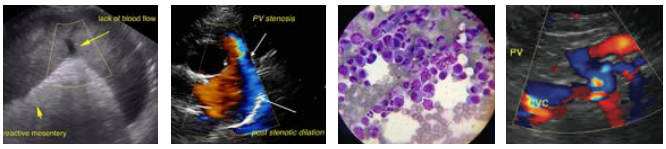

SonoPath.com™
1-800-838-4268 info@sonopath.com

PATIENT

Skylar Doubt

SPECIES

Canine

BREED

Australian Labradoodle

SEX

Spayed Female

AGE

9 years

WEIGHT

11.4 kg

INTERPRETED BY

Beth Johnson, DVM DACVIM

IMAGING PERFORMED BY

Evan Bell

HOSPITAL NAME

Cedarview AH

REFERRING VET

Dr. Holzman

INVOICE

95825

DATE

2/7/22

PRESENTING CLINICAL SIGNS

Currently on Hepatosupport, gabapentin and cartrophen. Upcoming stifle surgery (TPLO) and PA bloods showed an elevation in liver enzymes. Otherwise no clinical signs noted.
Abnormal PE/Chem/CBC/UA Results: Albumin increased to 40 ALT increased to 412 (prev 174) ALP increased to 795 (prev 536) GGT increased to 21 Cholesterol increased to 8.72

ULTRASONOGRAPHIC EXAMINATION OF THE ABDOMEN

Urinary System

Urinary bladder is moderately distended with anechoic contents. It has normal uniform wall thickness (< 0.2 cm). No masses or cystoliths are observed.

Left kidney is normal in size (4.2 cm) and shape with smooth peripheral margination. A normal 1:3 cortex to medulla ratio is maintained. The medulla and cortices are uniform in texture with some mild increased echogenicity and mild loss of corticomedullary distinction. There is no evidence of pyelectasia, mineral or infarcts observed.

Right kidney is normal in size (4.4 cm) and shape with smooth peripheral margination. A normal 1:3 cortex to medulla ratio is maintained. The medulla and cortices are uniform in texture with some mild increased echogenicity and mild loss of corticomedullary distinction. There is no evidence of pyelectasia, mineral or infarcts observed.

Adrenal Glands

Left adrenal gland is normal in size (1.8 cm long x 0.63 cm at cranial pole and 0.57 cm at caudal pole), shape and contour. Corticomedullary structure is unremarkable.

Right adrenal gland is normal in size (1.5 cm long x 0.87 cm at cranial pole and 0.4 cm at caudal pole), shape and contour. Corticomedullary structure is unremarkable.

Spleen

Spleen is subjectively enlarged in size with rounded margins but intact capsule. Parenchyma is homogenously coarse/mottled in echotexture and normal echogenicity. Several small, hypoechoic nodules were noted with a representative nodule measuring 0.35 cm in diameter. Splenic vasculature appears normal.

Liver

Liver is subjectively enlarged. Margins are smooth but round. It has a normal homogenous echotexture. Parenchyma is diffusely hyperechoic characterized by less prominent than normal portal vein walls and increased echogenicity relative to the spleen. Several, multi-focal, round, discrete, hyperechoic nodules are noted. Visible vasculature and biliary tree appear normal without distension or congestion. GB is moderately distended with anechoic bile and gravity dependent echogenic sediment. Some mineral was present. The wall is smooth without visible thickening. There is no evidence of cystic or CBD dilation. There is no evidence of effusion or inflammation.

SonoPath
Clinical Sonography & Telecytology

EDUCATIONAL TELECONSULTATION SERVICES™

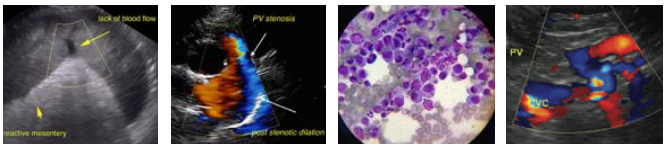

SonoPath.com
1-800-838-4268 info@sonopath.com

PATIENT

Skylar Doubt

SPECIES

Canine

BREED

Australian Labradoodle

SEX

Spayed Female

AGE

9 years

WEIGHT

11.4 kg

INTERPRETED BY

Beth Johnson, DVM DACVIM

IMAGING PERFORMED BY

Evan Bell

HOSPITAL NAME

Cedarview AH

REFERRING VET

Dr. Holzman

INVOICE

95825

DATE

2/7/22

Gastrointestinal

The visible gastric wall is normal in thickness (canine < 0.5 cm and feline < 0.4 cm). The stomach is empty.

The small intestines are normal in wall thickness and layering. Small intestinal motility appears adequate (1-3 contractions per min). The small intestinal lumen is mildly distended with echogenic non-shadowing luminal contents and gas consistent with normal ingesta. There is no evidence of obstruction, foreign material or infiltrative disease.

Colon is normal in wall thickness (< 0.2 cm) and layering.

Pancreas

Pancreas has normal homogenous echotexture and is normal in echogenicity and smooth margination. There is no evidence of peripancreatic inflammation.

Free Abdomen

Lymph nodes are normal with no observed enlargement.

ULTRASONOGRAPHIC FINDINGS

Primary Findings

Coarse splenomegaly – can be associated with congestion caused by sedation (if sedated) but can also be associated with diffuse infiltrative disease. Both benign conditions such as extramedullary hematopoiesis, lymphoid hyperplasia, as well as infiltrative neoplastic diseases such as round cell neoplasia should be considered. Several hypoechoic splenic nodules were noted. The nodules likely represent benign cysts, hematomas, nodular hyperplasia or extramedullary hematopoiesis. Infiltrative neoplasia can mimic benign lesions and cannot be ruled out.

Hyperechoic hepatomegaly– most consistent with benign steroid (endocrine) hepatopathy or reactive or idiopathic hepatopathy. Infiltrative neoplasia such as round cell neoplasia is also possible, but considered less likely. Small, multi-focal, discrete, hyperechoic nodules present. Differentials include benign nodular hyperplasia; however, infiltrative round cell neoplasia, primary hepatic neoplasia or metastatic neoplasia cannot be definitively ruled out.

Age related kidney change" – This finding is expected/consistent with age-related mild degenerative disease and should be interpreted clinically in combination with laboratory changes.

Canine Gallbladder debris" - Cholecystic debris is of unknown clinical significance. It can be seen with biliary stasis from fasting or illness. Cholecystic debris is not necessarily related to hepatobiliary disease. Echogenic bile is most commonly an incidental finding in dogs and should be interpreted in combination with clinical signs such as nausea, inappetence, cranial abdominal discomfort and/or laboratory changes such as increased ALP and/or increased Tbili.

SonoPath
Clinical Sonography & Telecytology
EDUCATIONAL TELECONSULTATION SERVICES™

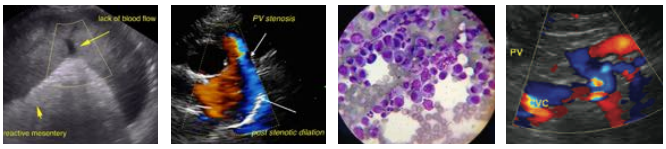

SonoPath.com
1-800-838-4268 info@sonopath.com

PATIENT

Skylar Doubt

SPECIES

Canine

BREED

Australian Labradoodle

SEX

Spayed Female

AGE

9 years

WEIGHT

11.4 kg

INTERPRETED BY

Beth Johnson, DVM
DACVIM

IMAGING PERFORMED BY

Evan Bell

HOSPITAL NAME

Cedarview AH

REFERRING VET

Dr. Holzman

INVOICE

95825

DATE

2/7/22

INTERPRETATION OF THE FINDINGS & FURTHER RECOMMENDATIONS

Recommendations for this patient given the increased liver enzymes combined with the liver and splenic changes include a FNA of the liver and spleen if the patient's coagulation status is appropriate as well as testing for Leptospirosis. If a diagnosis is not obtained in this fashion recommendations include to taper pain management especially Carprofen as soon as possible following surgery and monitor liver enzymes while the patient received both Denamarin and Ursodiol for hepatic support. If the liver enzymes do not improve and/or progress a liver biopsy may be warranted. If not already performed three view thoracic radiographs to further assess cardiopulmonary status and look for evidence of metastatic disease are recommended prior to anesthesia.

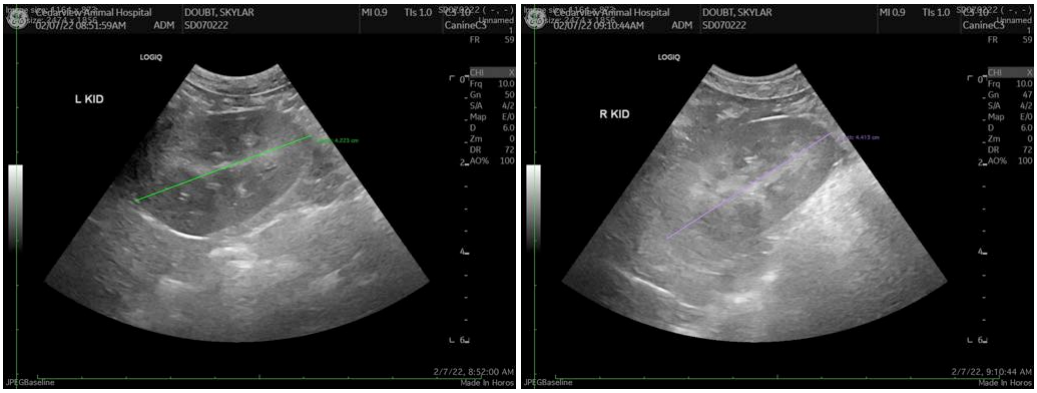

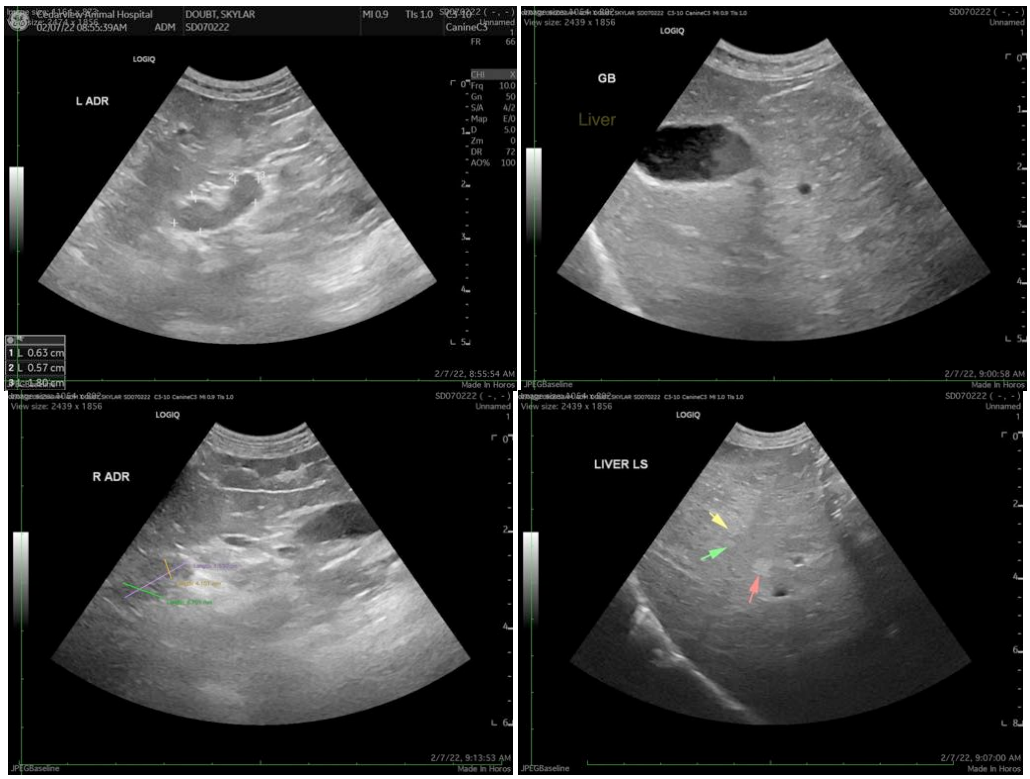

SonoPath

Clinical Sonography & Telecytology

EDUCATIONAL TELECONSULTATION SERVICES™

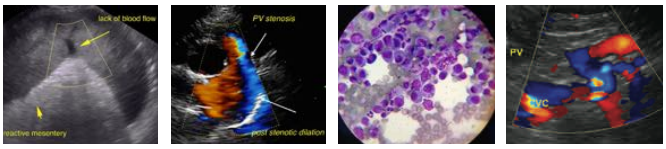

SonoPath.com™
1-800-838-4268 info@sonopath.com

PATIENT

Skylar Doubt

SPECIES

Canine

BREED

Australian Labradoodle

SEX

Spayed Female

AGE

9 years

WEIGHT

11.4 kg

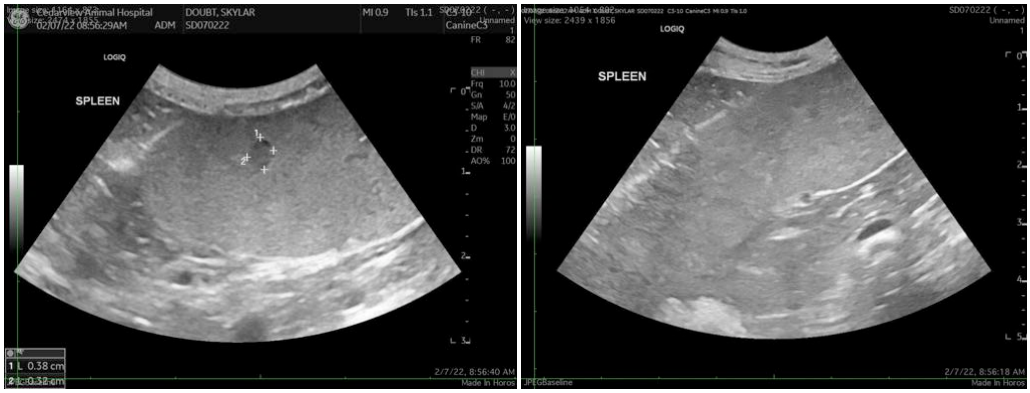

INTERPRETED BY

Beth Johnson, DVM DACVIM

IMAGING PERFORMED BY

Evan Bell

HOSPITAL NAME

Cedarview AH

REFERRING VET

Dr. Holzman

INVOICE

95825

DATE

2/7/22

The information and recommendations provided are based on the images presented by the referring veterinarian/sonographer. No evaluation can be communicated regarding pathology that was not visible in the image/video clips provided.

Thank you for this referral. If the clinical or image interpretation does not parallel your findings or if I can be of any further assistance please contact me.

Beth Johnson, DVM DACVIM

Beth.Johnson@SonoPath.com