

**DATE PRESENTING CLINICAL SIGNS**

2/6/23

History: 1/18/23- Came in for ++vomiting; given fluids, Cerenia, Metronidazole, bland diet and seemed to resolve; bloodwork done showing elevated ALT, sl elevated SAP, and elevated GGT. 9/2022 - MCT removed, at that time ALT mod elevated and was more increased at this visit

**PATIENT**

Molly Priet

Current Medications: Metronidazole 120mg BID (soln)

Lab Results: ALT- 288, SAP- 176, GGT- 31.

**SPECIES**

Date of Previous IntraPet Ultrasound: No previous.

Canine

Sedation: Not required to complete full diagnostic ultrasound.

**BREED**

Stat Report: Not requested.

Imaging Performed By: Stephanie Warga RDCS, RVT.

French Bulldog

**ULTRASONOGRAPHIC EXAMINATION OF THE ABDOMEN****SEX****Urinary System**

Spayed Female

Urinary bladder is adequately distended with anechoic contents. No masses, inflammatory changes, echogenic sediment or cystoliths are observed. The urinary bladder, trigone and visible pelvic urethra are normal in thickness with a smooth mucosal surface.

**AGE**

17.8 Pounds

Left kidney is normal is size (4.59 cm), shape and echogenicity. It has smooth peripheral margination. There is a normal 1:3 cortex to medulla ratio with appropriate corticomedullary distinction. There is no evidence of pyelectasia, mineral or infarcts observed.

**WEIGHT**

1/11/11

Right kidney is normal is size (4.28 cm), shape and echogenicity. It has smooth peripheral margination. There is a normal 1:3 cortex to medulla ratio with appropriate corticomedullary distinction. There is no evidence of pyelectasia, mineral or infarcts observed.

**INTERPRETED BY**

Beth Johnson, DVM  
DACVIM

**Adrenal Glands**

Adrenal glands are largely normal in size, shape and contour. Some parenchymal heterogeneity is present without concerning capsular distortion. These changes are likely normal for this age but should be monitored if there is any suspicion of adrenal disease. The left adrenal gland measures 2.43 cm long x 0.6 cm at the cranial pole and 0.73 cm at the caudal pole. The right adrenal gland measures 2.02 cm long x 0.97 cm at the cranial pole and 0.64 cm at the caudal pole.

**HOSPITAL NAME**

Essex Middle River  
VC

**Spleen**

Spleen is subjectively normal in size with a normal smooth capsular contour. Parenchyma is appropriately finely textured and homogenous with normal echogenicity relative to surrounding tissue (hyperechoic to liver). A slightly irregular 1.8 cm x 0.83 cm hyperechoic nodule is noted in the mid body, non-capsule-disrupting. Splenic vasculature appears normal.

**REFERRING VET**

Dr. Hicks

**Liver**

Liver is subjectively enlarged with mildly irregular margins. Parenchyma is heterogenous characterized by multiple poorly defined hypoechoic nodules within otherwise hyperechoic liver parenchyma. Visible vasculature and biliary tree appear normal without distension or congestion.

**INVOICE**

21041

Gallbladder is non-distended in size. The wall is smooth without visible thickening. Luminal contents are primarily anechoic. There is no evidence of cystic or common bile duct dilation.

**Gastrointestinal**

The visible stomach wall is normal in thickness and layering. The lumen of the stomach is empty with no evidence of obstruction, foreign material or infiltrative disease. Pyloric outflow tract appears patent.

The visible small intestines are normal in wall thickness and layering. Very subtle/mild hyperechoic mucosal fogging or speckling is noted. Small intestinal motility appears adequate (1-3 contractions per min). The lumen of the small intestine is empty with no evidence of obstruction or foreign material.

The visible colon is normal in wall thickness and layering. Contents are consistent with normal formed feces and gas.

### ***Pancreas***

The observed pancreas appears appropriately isoechoic to surrounding omental fat. Visible capsule is smooth and normal in contour. Visible pancreatic parenchyma is homogenous and unremarkable. There is no visible pancreatic duct dilation. There is no evidence of active peripancreatic inflammation.

### ***Free Abdomen***

There is no evidence of peritoneal effusion. There is no apparent lymphadenopathy.

## **ULTRASONOGRAPHIC FINDINGS**

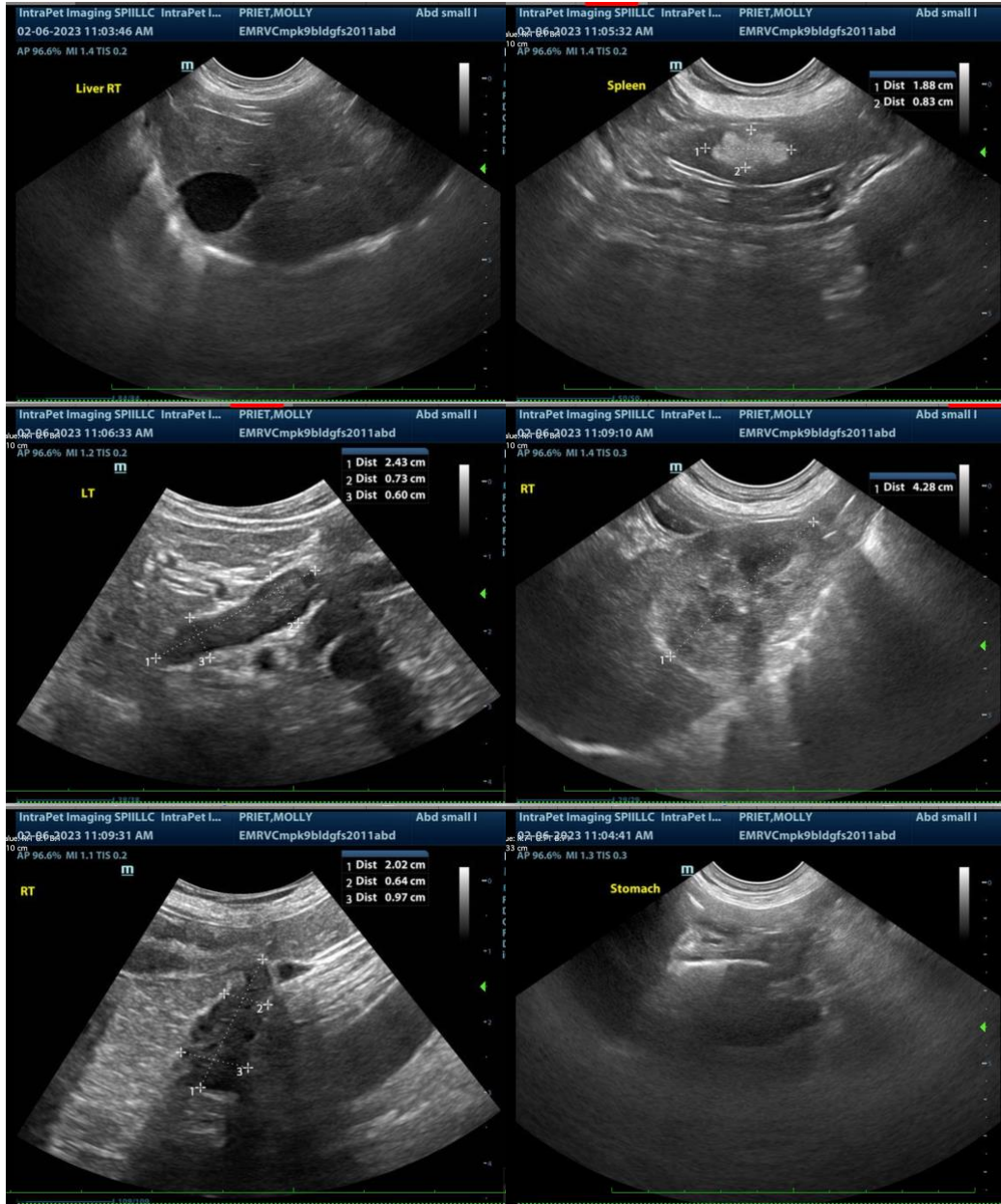
- Very mild/subtle mucosal speckling – Mucosal speckling is often present with inflammatory bowel disease (IBD). It is not specific for type or severity of disease. Mild speckling change can occur as a normal patient variant in the post-prandial state.
- Heterogenous Liver – These changes are most consistent with benign processes such as nodular hyperplasia, steroid (vacuolar) hepatopathy, extramedullary hematopoiesis or possibly chronic inflammatory disease and less commonly infiltrative round cell or metastatic neoplasia.
- Hyperechoic splenic nodule – most consistent with benign myelolipoma. Other differentials such as fibrosis or calcification caused by old hematoma or infarct, chronic inflammation, granulomatous disease or metastatic disease cannot be ruled out, but is considered less likely.

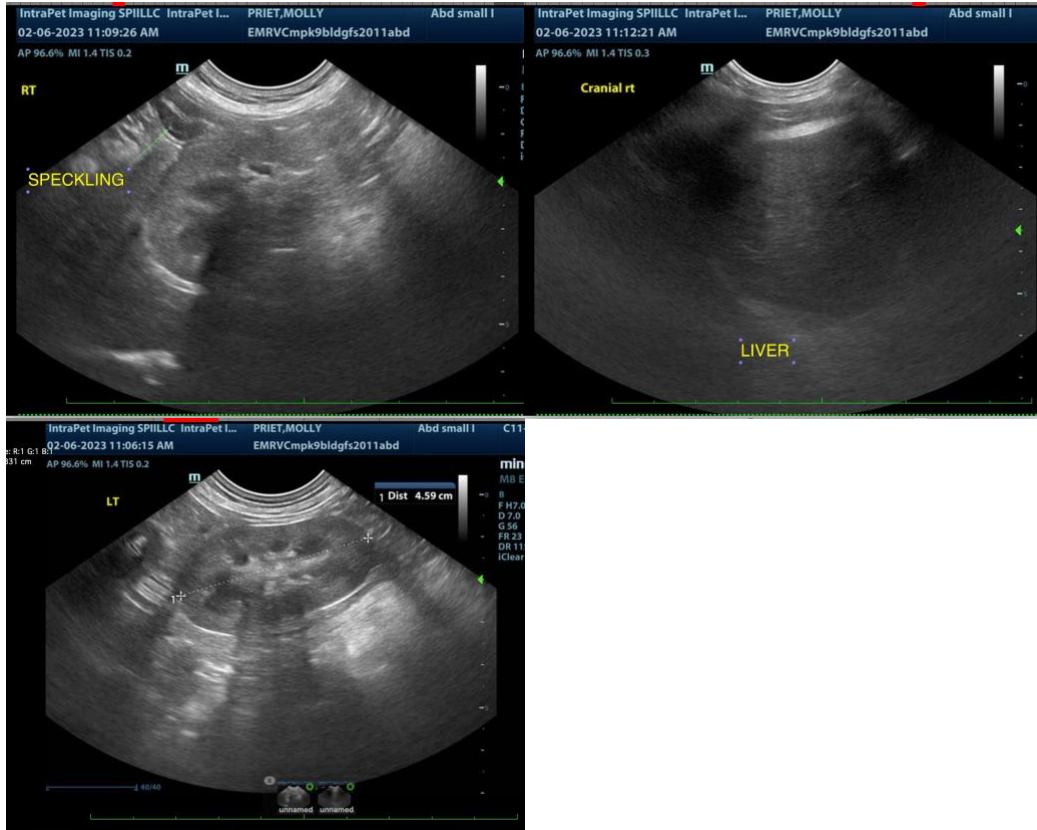
## **INTERPRETATION OF THE FINDINGS & FURTHER RECOMMENDATIONS**

Given this patient's reported progressive increase in ALT, bile acids are recommended if total bilirubin is normal. Additionally, testing for Leptospirosis could be considered.

While both the liver and splenic changes trend in appearance toward benign, given this patient's history of mast cell tumor, fine needle aspirates of the liver and spleen could also be considered if patient's coagulation status is appropriate.

In the meantime, if the reported gastrointestinal signs are acute, then supportive/symptomatic medical management of gastritis/gastroenteritis is recommended, including empirical deworming with a 5-day course of Panacur. However, if clinical signs don't improve and/or progress, or there is any chronicity to them, even though the bowel changes described above are very subtle, further investigation for possible inflammatory bowel disease could be considered, beginning with a gastrointestinal malabsorption panel (including cobalamin, folate, TLI and PLI) to Texas A&M GI Laboratory is recommended for further evaluation of GI and pancreatic function.





The information and recommendations provided are based on the images presented by the referring veterinarian. No evaluation can be communicated regarding pathology that was not visible in the image/video clips provided.

Thank you for this referral. If the clinical or image interpretation does not parallel your findings or if I can be of any further assistance please contact me.

**Beth Johnson, DVM DACVIM**  
Beth.Johnson@SonoPath.com