

**DATE PRESENTING CLINICAL SIGNS**

2/6/23 History: Diagnosed with pancreatitis 1/10; was recommended by urgent care to have an ultrasound.

PATIENT

Marley Lee

Current Medications: Cerenia 16mg ½ SID, Propectalin small dog.

Date of Previous IntraPet Ultrasound: No previous.

Sedation: Not required to complete full diagnostic ultrasound.

Stat Report: Not requested.

SPECIES

Canine

Imaging Performed By: Andi Parkinson, BS, RDMS.

ULTRASONOGRAPHIC EXAMINATION OF THE ABDOMEN**BREED**

Yorkie

Urinary System

Urinary bladder is adequately distended with anechoic contents. No masses, inflammatory changes, echogenic sediment or cystoliths are observed. The urinary bladder, trigone and visible pelvic urethra are normal in thickness with a smooth mucosal surface.

SEX

Intact Male

Prostate is normal in size (2.6 cm wide) for an intact male. Parenchyma is diffusely homogenous and relatively hyperechoic. Normal distinct margins and symmetrical bilobed shape are maintained.

AGE

4/30/11

Kidneys are overall normal in size and shape with smooth peripheral margination. A normal 1:3 cortex to medulla ratio is maintained. The medulla and cortices are uniform in texture with some mild increased cortical echogenicity and mild loss of corticomedullary distinction, expected in this age patient. There is no evidence of pyelectasia, mineral or infarcts observed. The left kidney measures 3.37 cm. The right kidney measures 4.11 cm.

WEIGHT

5 Pounds

Adrenal Glands

Left adrenal gland is normal in size (1.23 cm long x 0.59 cm at cranial pole and 0.46 cm at caudal pole), shape and overall architecture, echogenicity and echotexture. Visible surrounding vasculature appears normal.

Right adrenal gland is normal in size (1.05 cm long x 0.37 cm at cranial pole and 0.35 cm at caudal pole), shape and overall architecture, echogenicity and echotexture. Visible surrounding vasculature appears normal.

INTERPRETED BY

Beth Johnson, DVM
DACVIM

HOSPITAL NAME

Banfield Timonium

Spleen

Spleen is subjectively normal in size with a normal smooth capsular contour. Parenchyma is appropriately finely textured and homogenous with normal echogenicity relative to surrounding tissue (hyperechoic to liver). No focal nodules or masses are observed. Splenic vasculature appears normal.

REFERRING VET

Dr. Borrison

Liver

Liver is subjectively normal in size with normal smooth curvilinear peripheral contour. Parenchyma is appropriately hypoechoic to the spleen in echogenicity and appropriately mildly coarse and homogenous in echotexture. No focal lesions are observed. Visible vasculature and biliary tree appear normal without distension or congestion.

INVOICE

21039

Gallbladder is non-distended in size. The wall is smooth without visible thickening. Luminal contents are primarily anechoic. There is no evidence of cystic or common bile duct dilation.

Gastrointestinal

The visible stomach wall is normal in thickness and layering. The lumen of the stomach is mildly distended with echogenic non-shadowing luminal contents and gas consistent with normal ingesta. There is no evidence of obstruction, foreign material or infiltrative disease. Pyloric outflow tract appears patent. Patient was reportedly not fasted.

The visible small intestines are normal in wall thickness and layering. Small intestinal motility appears adequate (1-3 contractions per min). The lumen of the small intestine is mildly distended with echogenic non-shadowing luminal contents and gas consistent with normal ingesta. There is no evidence of obstruction, foreign material or infiltrative disease. Patient was reportedly not fasted.

The visible colon is normal in wall thickness and layering. Contents are consistent with normal formed feces and gas.

Pancreas

The observed pancreas appears appropriately isoechoic to surrounding omental fat. Visible capsule is smooth and normal in contour. Visible pancreatic parenchyma is homogenous and unremarkable. There is no visible pancreatic duct dilation. There is no evidence of active peripancreatic inflammation.

Free Abdomen

There is no evidence of peritoneal effusion. There is no apparent lymphadenopathy.

Other

Both testicles are visualized without evident testicular pathology.

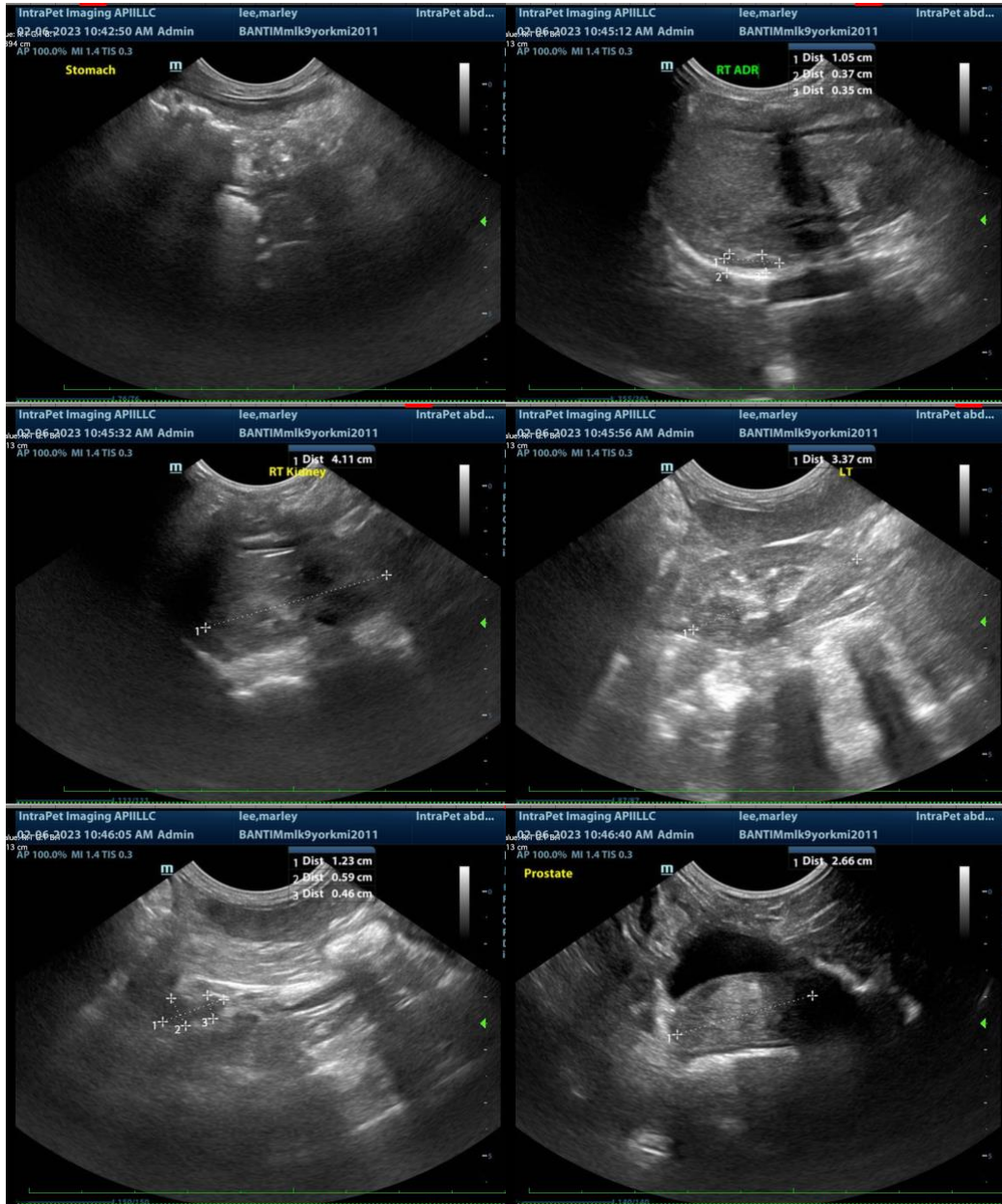
ULTRASONOGRAPHIC FINDINGS

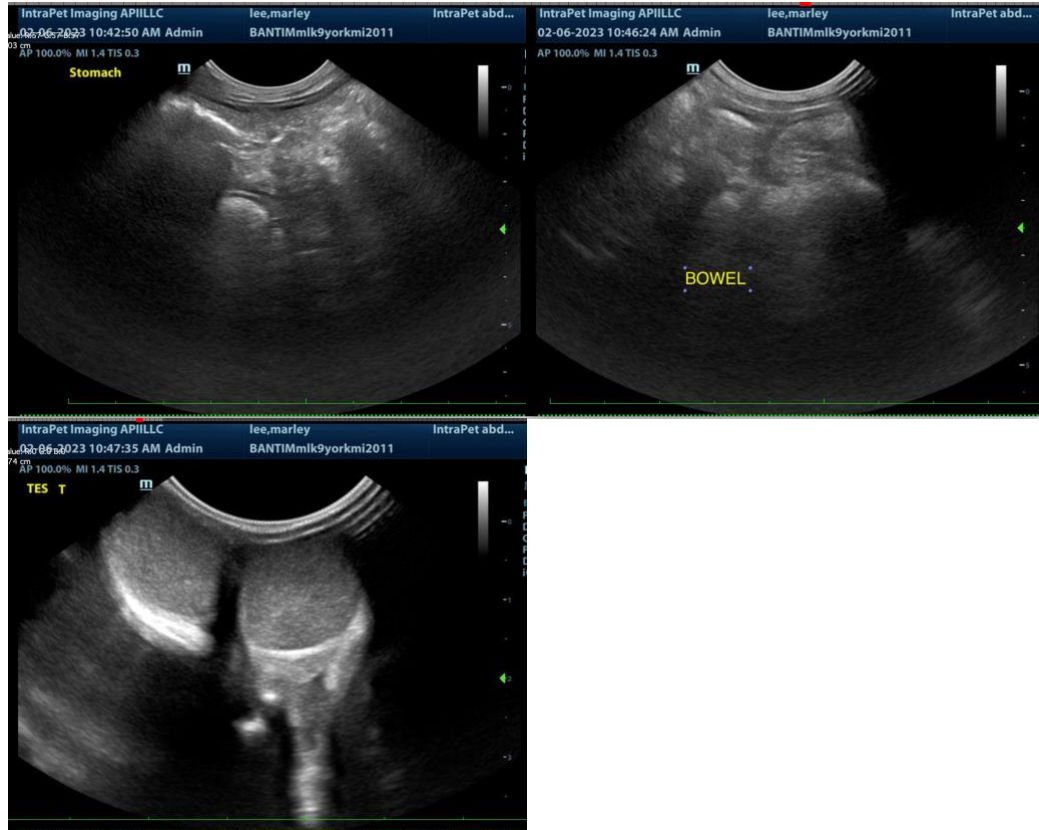
- Mild age-related kidney changes
- There is no evidence of gastrointestinal or pancreatic disease visible in these images at this time, however, mild pathology could be missed in the face of a postprandial state and/or infiltrative bowel disease and pancreatitis can exist without visible ultrasonographic evidence in the early stages.

INTERPRETATION OF THE FINDINGS & FURTHER RECOMMENDATIONS

Given this patient's reported hypoalbuminemia and hypocalcemia, if not recently evaluated, ruling out proteinuria is recommended via urinalysis and, if indicated based on urinalysis results, urine culture is recommended. If protein is present in an otherwise quiet sediment, protein quantification with a urine protein to creatinine ratio is recommended. However, given the concurrent hypocalcemia, protein losing enteropathy is a differential. Recommendations include gastrointestinal malabsorption panel (including cobalamin, folate, TLI and PLI) to Texas A&M GI Laboratory is recommended for further evaluation of GI and pancreatic function.

Ultimately, pending results, patient status, etc., biopsies of the GI tract may be necessary, and if pursued, a fasted recheck ultrasound may be beneficial prior to biopsies. However, in the meantime, empirical medical management with an ultra-low-fat diet, empirical deworming with a 5-day course of Panacur, cobalamin supplementation (unless not indicated based on gastrointestinal malabsorption panel results), and a probiotic (such as Visbiome or ProViable) may be helpful. Calcium supplementation may also be warranted, but an ionized calcium level is recommended prior to that.





The information and recommendations provided are based on the images presented by the referring veterinarian. No evaluation can be communicated regarding pathology that was not visible in the image/video clips provided.

Thank you for this referral. If the clinical or image interpretation does not parallel your findings or if I can be of any further assistance please contact me.

Beth Johnson, DVM DACVIM
Beth.Johnson@SonoPath.com