



**PATIENT**

Peanut Detrolio

**SPECIES**

Canine

**BREED**

Am. Staffordshire  
Terrier

**SEX**

MN

**AGE**

8 years

**WEIGHT**

60 lbs

**INTERPRETED BY**

Beth Johnson, DVM  
DACVIM

**IMAGING PERFORMED BY**

Pamela Harrigan, RDCS,  
Certified Veterinary  
Sonographer

**HOSPITAL NAME**

Norfolk County  
Veterinary Service

**REFERRING VET**

Dr. Aurora Richards

**INVOICE**

11257

**DATE**

2/5/2026

**PRESENTING CLINICAL SIGNS**

- Peanut presented for low RBC count, has been treated for IMHA. Everything bloodwork wise and appetite and energy is improving, but severe muscle wasting and not maintaining weight. Low HCT. On Prednisone 20 mg, 1.5 tab BID, Cyclosporine 150 mg, 1 BID. \*Sedated with torb/dexdomitor.

**ULTRASONOGRAPHIC EXAMINATION OF THE ABDOMEN**

**Urinary System**

The urinary bladder is adequately distended with anechoic contents. No masses, inflammatory changes, echogenic sediment or cystoliths are observed. The urinary bladder, trigone and visible pelvic urethra are normal in thickness with a smooth mucosal surface.

Prostate is normal in size, echotexture, and echogenicity for a neutered male.

The right kidney is normal is size (7.06 cm), shape and echogenicity. It has smooth peripheral margination. There is a normal 1:3 cortex to medulla ratio with appropriate corticomedullary distinction. There is no evidence of pyelectasia, mineral or infarcts observed.

The left kidney is normal is size (7.29 cm), shape and echogenicity. It has smooth peripheral margination. There is a normal 1:3 cortex to medulla ratio with appropriate corticomedullary distinction. There is no evidence of pyelectasia, mineral or infarcts observed.

**Adrenal Glands**

The right adrenal gland is normal in size (0.5 cm at cranial pole and 0.59 cm at caudal pole), shape and overall architecture, echogenicity and echotexture. Visible surrounding vasculature appears normal.

The left adrenal gland is normal in size (0.41 cm at cranial pole and 0.57 cm at caudal pole), shape and overall architecture, echogenicity and echotexture. Visible surrounding vasculature appears normal.

**Spleen**

The spleen is subjectively normal in size with a normal smooth capsular contour. Parenchyma is appropriately finely textured and homogenous with normal echogenicity relative to surrounding tissue (hyperechoic to liver). No focal nodules or masses are observed. Splenic vasculature appears normal.

**Liver**

Liver is subjectively enlarged with mildly irregular margins. Parenchyma is mildly heterogenous characterized by multiple poorly defined hypoechoic nodules within otherwise hyperechoic liver parenchyma. Visible vasculature and biliary tree appear normal without distension or congestion.

Gallbladder is moderately distended with anechoic bile as well as suspended and gravity dependent echogenic debris. The wall is smooth without visible thickening. There is no evidence of cystic or CBD dilation. There is no evidence of effusion or inflammation.

**Gastrointestinal**



**PATIENT**

Peanut Detrolio

The visible stomach wall is normal in thickness and layering. The lumen of the stomach is mildly distended with echogenic non-shadowing luminal contents and gas consistent with normal ingesta. There is no evidence of obstruction or foreign material noted. Pyloric outflow tract appears patent.

**SPECIES**

Canine

The visible small intestines are normal in wall thickness and layering. Small intestinal motility appears adequate (1-3 contractions per min). The lumen of the small intestine is mildly distended with echogenic non-shadowing luminal contents and gas consistent with normal ingesta. There is no evidence of obstruction or foreign material noted.

**BREED**

Am. Staffordshire  
Terrier

The visible colon is normal in wall thickness (< 0.2 cm) and layering. Contents are consistent with normal formed feces and gas.

**SEX**

MN

**Pancreas**

The pancreas that is observed appears appropriately isoechoic to surrounding omental fat. Visible capsule is smooth and normal in contour. Visible pancreatic parenchyma is homogenous and unremarkable. There is no visible pancreatic duct dilation. There is no evidence of active peripancreatic inflammation.

**AGE**

8 years

**Free Abdomen**

**WEIGHT**

60 lbs

There is no visible free peritoneal effusion noted in these images.

Medial iliac lymph nodes are prominent in size with swollen capsular contour. Normal elongated shape (length to width ratio) is maintained. There is no loss of parenchymal detail.

**INTERPRETED BY**

Beth Johnson, DVM  
DACVIM

**ULTRASONOGRAPHIC FINDINGS**

**IMAGING  
PERFORMED BY**

Pamela Harrigan, RDCS,  
Certified Veterinary  
Sonographer

- Mildly heterogenous liver – These changes are most consistent with benign processes such as nodular hyperplasia, steroid (vacuolar) hepatopathy, extramedullary hematopoiesis or possibly chronic inflammatory disease and less commonly infiltrative round cell or metastatic neoplasia.
- Mild gallbladder debris - Cholecystic debris is of unknown clinical significance. It can be seen with biliary stasis from fasting or illness. Cholecystic debris is not necessarily related to hepatobiliary disease. Echogenic bile is most commonly an incidental finding in dogs and should be interpreted in combination with clinical signs such as nausea, inappetence, cranial abdominal discomfort and/or laboratory changes such as increased ALP and/or increased Tbili.
- Mildly reactive medial iliac lymph nodes – infiltrative neoplastic disease cannot be ruled out but is considered less likely.

**HOSPITAL NAME**

Norfolk County  
Veterinary Service

**REFERRING VET**

Dr. Aurora Richards

**INTERPRETATION OF THE FINDINGS & FURTHER RECOMMENDATIONS**

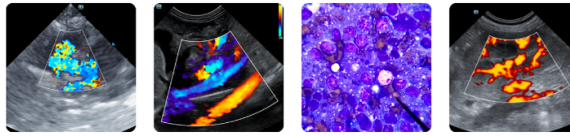
**INVOICE**

11257

This is a largely unremarkable and non-specific study with subtle changes as to be expected in a patient taking steroids. Given patient's history, one differential for the muscle wasting is actually muscle wasting secondary to high steroid doses and if possible, tapering as tolerated the prednisone to the lowest tolerated dose and/or ultimately, discontinuing it altogether for alternative immunosuppressants could be considered and may result in improvement.

**DATE**

2/5/2026



**PATIENT**

Peanut Detrollo

**SPECIES**

Canine

**BREED**

Am. Staffordshire  
Terrier

**SEX**

MN

**AGE**

8 years

**WEIGHT**

60 lbs

**INTERPRETED BY**

Beth Johnson, DVM  
DACVIM

**IMAGING  
PERFORMED BY**

Pamela Harrigan, RDCS,  
Certified Veterinary  
Sonographer

**HOSPITAL NAME**

Norfolk County  
Veterinary Service

**REFERRING VET**

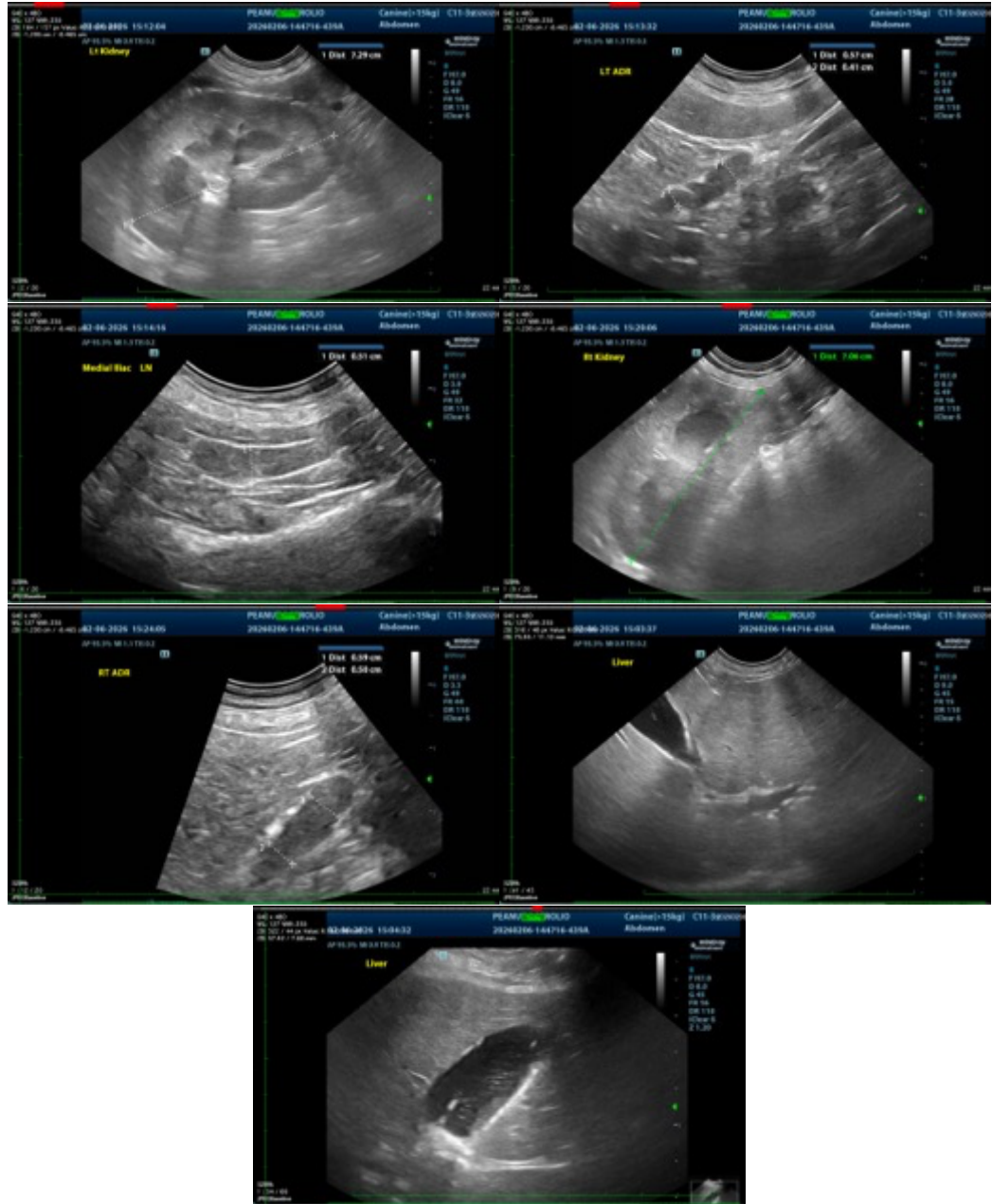
Dr. Aurora Richards

**INVOICE**

11257

**DATE**

2/5/2026



The information and recommendations provided are based on the images presented by the referring veterinarian/sonographer. No evaluation can be communicated regarding pathology that was not visible in the image/video clips provided.

Thank you for this referral. If the clinical or image interpretation does not parallel your findings or if I can be of any further assistance please contact me.

**Beth Johnson, DVM, DACVIM**  
info@sonopath.com