



PATIENT

Delilah Bott

SPECIES

Canine

BREED

Pomeranian

SEX

Spayed Female

AGE

10 Years 4 Months

WEIGHT

8.4

INTERPRETED BY

Beth Johnson, DVM
DACVIM

IMAGING PERFORMED BY

Carissa Hayden

HOSPITAL NAME

Elizabeth Animal
Hospital

REFERRING VET

Jen Redus, DVM

INVOICE

72738

DATE

2/5/26

PRESENTING CLINICAL SIGNS

Liquid since about 2 am today. Appetite has been off since 2-3-2026. Diarrhea started yesterday, turned bloody around 2:00 am 2-5-2026

Abnormal PE/Chem/CBC/UA Results: PE: Oral Cavity: Dental disease grade 4 with advanced tartar and periodontal disease, missing many teeth Musculoskeletal: Bilateral lateral patellar luxations grade 2-3; Muscle condition score grade 2 with moderate loss of muscle mass CBC: RBC 10.12 M/uL, Hematocrit 71.1%, Hemoglobin 23.8 g/dL, RDW 22.5%, Lymphocytes 0.69K/uL, Eosinophils 0.01 KuL CHEM: Glucose 66mg/dL, BUN 30 mg/dL, Phosphorus 7.9 mg/dL

ULTRASONOGRAPHIC EXAMINATION OF THE ABDOMEN

Urinary System

Urinary bladder is adequately distended. It has a normal uniform wall thickness. Contents include primarily anechoic fluid with a moderate amount of echogenic non-shadowing debris, most consistent with exfoliated cells, mucous and/or small blood clots. Both sterile inflammation as well as urinary tract infection can present with echogenic debris. No masses or cystoliths are observed. The trigone and visible pelvic urethra are normal in thickness with a smooth mucosal surface.

The right kidney is normal in size (3.21 cm), shape and echogenicity. It has smooth peripheral margination. There is a normal 1:3 cortex to medulla ratio with appropriate corticomedullary distinction. There is no evidence of pyelectasia, mineral or infarcts observed.

The left kidney is normal in size (3.66 cm), shape and echogenicity. It has smooth peripheral margination. There is a normal 1:3 cortex to medulla ratio with appropriate corticomedullary distinction. There is no evidence of pyelectasia, mineral or infarcts observed.

Adrenal Glands

The right adrenal gland is normal in size (0.51 cm at cranial pole and 0.62 cm at caudal pole), shape and overall architecture, echogenicity and echotexture. Visible surrounding vasculature appears normal.

The left adrenal gland is normal in size (0.47 cm at cranial pole and 0.52 cm at caudal pole), shape and overall architecture, echogenicity and echotexture. Visible surrounding vasculature appears normal.

Spleen

The spleen is subjectively normal in size with a normal smooth capsular contour. Parenchyma is appropriately finely textured and homogenous with normal echogenicity relative to surrounding tissue (hyperechoic to liver). No focal nodules or masses are observed. Splenic vasculature appears normal.

Liver

The liver is subjectively normal in size with normal smooth curvilinear peripheral contour. Parenchyma is appropriately hypoechoic to the spleen in echogenicity and appropriately mildly coarse and homogenous in echotexture. No focal lesions are observed. Visible vasculature and biliary tree appear normal without distension or congestion.

The gallbladder is non-distended in size. The wall is smooth without visible thickening. Luminal contents are primarily anechoic. There is no evidence of cystic or common bile duct dilation.



PATIENT

Delilah Bott

SPECIES

Canine

BREED

Pomeranian

SEX

Spayed Female

AGE

10 Years 4 Months

WEIGHT

8.4

INTERPRETED BY

Beth Johnson, DVM
DACVIM

IMAGING PERFORMED BY

Carissa Hayden

HOSPITAL NAME

Elizabeth Animal
Hospital

REFERRING VET

Jen Redus, DVM

INVOICE

72738

DATE

2/5/26

Gastrointestinal

The visible stomach wall is normal in thickness and layering. The lumen of the stomach is empty with no evidence of obstruction, foreign material or infiltrative disease. Pyloric outflow tract appears patent.

The visible small intestines are normal in wall thickness and layering. Small intestinal motility appears adequate (1-3 contractions per min). The lumen of the small intestine is empty with no evidence of obstruction, foreign material or infiltrative disease.

The visible colon is normal in wall thickness (< 0.2 cm) and layering. Contents are consistent with normal formed feces and gas.

Pancreas

The pancreas that is observed appears appropriately isoechoic to surrounding omental fat. Visible capsule is smooth and normal in contour. Visible pancreatic parenchyma is homogenous and unremarkable. There is no visible pancreatic duct dilation. There is no evidence of active peripancreatic inflammation.

Free Abdomen

There is no visible free peritoneal effusion noted in these images.

There is no apparent pathologic lymphadenopathy noted in these images.

Assessment of heart base images is included when/if a splenic nodule/mass is present (as a complimentary add on). They are also assessed when a specific request is made for assessment of a limited second cavity (heart base and/or thorax) for an additional charge. Images of the heart (and/or) thorax were not assessed for this study. Please contact us if you would like a second cavity.

ULTRASONOGRAPHIC FINDINGS

- Moderate amount of echogenic urinary bladder debris.
- There is not a definitive ultrasonographically visible intraabdominal explanation for patient's reported hematochezia.

INTERPRETATION OF THE FINDINGS & FURTHER RECOMMENDATIONS

A routine fecal/giardia exam is recommended if not recently evaluated.

A gastrointestinal malabsorption panel (including cobalamin, folate, TLI and PLI) to Texas A&M GI Laboratory is recommended for further evaluation of GI and pancreatic function.

A fecal enteropathogen PCR panel to Texas A&M GI Laboratory could be considered for further evaluation of possible infectious disease. Contact lab for recommendations on how long to discontinue antibiotics (if indicated) prior to obtaining a stool sample for submission.

A baseline cortisol is recommended. If baseline cortisol is less than 2, a full ACTH stimulation test is recommended to rule out hypoadrenocorticism.

In the meantime, supportive/symptomatic medical management of clinical signs is recommended, including a probiotic (such as visbiome or proviable), empirical deworming with a 5-day course of Panacur and, if tolerated, a transition in diet, based on trial-and-error response, beginning possibly with



PATIENT

Delilah Bott

SPECIES

Canine

BREED

Pomeranian

SEX

Spayed Female

AGE

10 Years 4 Months

WEIGHT

8.4

INTERPRETED BY

Beth Johnson, DVM
DACVIM

IMAGING PERFORMED BY

Carissa Hayden

HOSPITAL NAME

Elizabeth Animal Hospital

REFERRING VET

Jen Redus, DVM

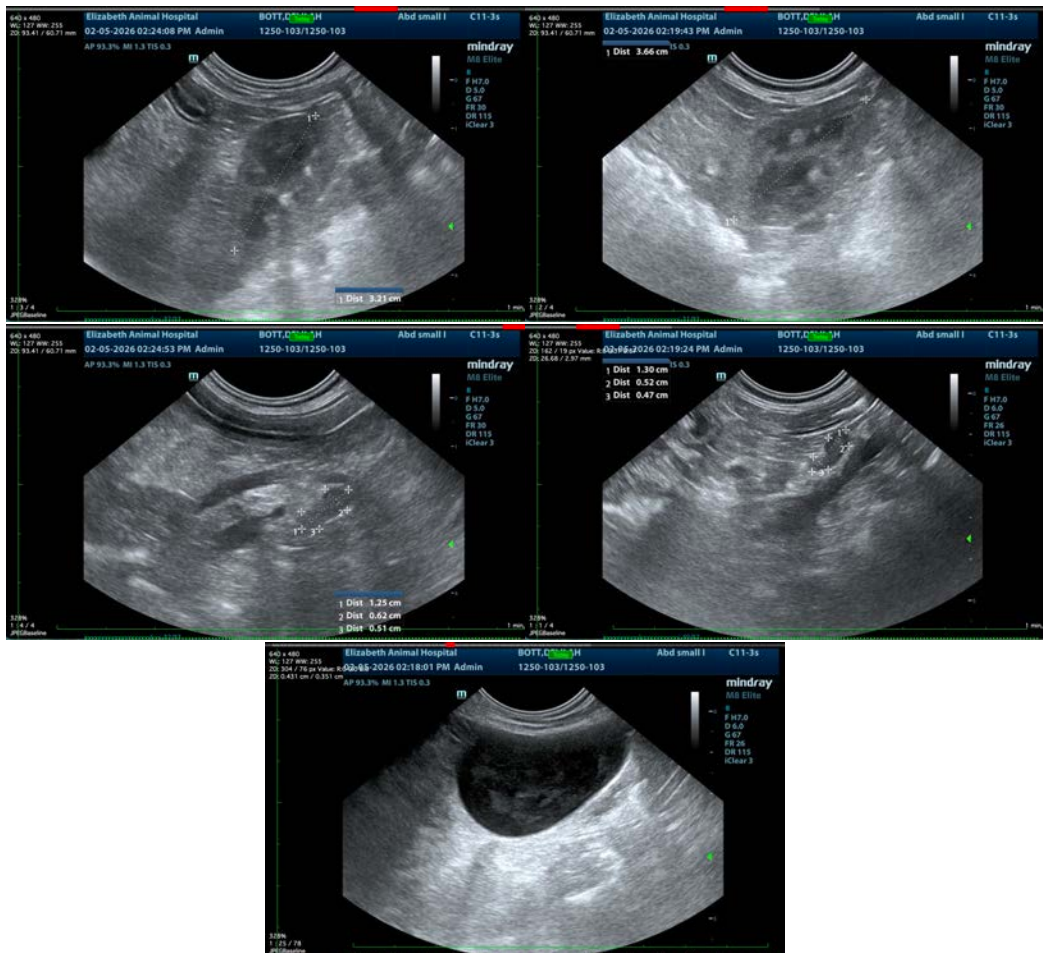
INVOICE

72738

DATE

2/5/26

a gastrointestinal biome diet vs a hydrolyzed protein diet vs other. Some patients respond to one brand/version of a hydrolyzed protein diet better than another brand, so several brand attempts may be required.



The information and recommendations provided are based on the images presented by the referring veterinarian/sonographer. No evaluation can be communicated regarding pathology that was not visible in the image/video clips provided.

Thank you for this referral. If the clinical or image interpretation does not parallel your findings or if I can be of any further assistance please contact me.

Beth Johnson, DVM, DACVIM
info@sonopath.com