



## PATIENT

Chubbs Hoffman

## SPECIES

Feline

## BREED

DSH

## SEX

Neutered Male

## AGE

13 Years

## WEIGHT

4.08 kg

## INTERPRETED BY

Beth Johnson, DVM  
DACVIM

## IMAGING PERFORMED BY

Renee Trionfetti, VMD

## HOSPITAL NAME

Firefly Veterinary  
Urgent Care

## REFERRING VET

Casey Dignan, VMD

## INVOICE

72774

## DATE

2/5/26

## PRESENTING CLINICAL SIGNS

AUS to further evaluate icterus, anemia, liver enzyme LES (ALT), elevated GGT and Tbili and a large fluid filled abdominal mass (drained 2/1/2026). Per owner pet was diagnosed with "thickened bowel disease" in 7/2025 and pet has been yellow for a couple of months. Current Medications at time of Urgent Care visit on Sunday 2/1/26 were: Pred transdermal, chlorambucil and Mirtzapine ointment.

Patient started vomiting 4 days prior to presentation and became lethargic. Tech at rDVM gave SQ fluids and Cerenia. Now patient is unable to defecate and has a poor appetite. On presentation to Urgent Care on 2/1 patient was noticeably jaundice, dehydrated and had a markedly distended abdomen; BCS 2/9

Diagnostics listed below. 23G butterfly needle used to remove 330 mL portwine sticky fluid from mass. No medication changes were made at that time. Enema was given as well. Patient was reported to be doing better the following day.

Meds: Prednisolone transdermal, chlorambucil and Mirtzapine ointment.

Abnormal PE/Chem/CBC/UA Results: CBC: RBC 3.80 (L), HCT 19.4 (L), Hgb 6.6 (L), MCH 17.4 (H), WBC 17.97 (H), Neut 15.08 (H), Monos 0.77 (H), Plt 737 (H), Pltcr1 1.19 (H) - Chem: Glu 192 (H), ALT 358 (H), GGT 8 (H), Tbili 4.3 (H) - Rads: Large soft tissue mass in ventral abdomen, mass effect noted displacing SI and colon, feces present throughout colon with desiccated fecal material in distal colon, thoracic rads show no obvious pulmonary consolidation or metastasis - Cystic fluid: TP 2.9 / PCV 0; Modified transudate Repeat xrays showed marked improvement to mass effect - Repeat Chem drawn at time of AUS: Pending

## ULTRASONOGRAPHIC EXAMINATION OF THE ABDOMEN

### Urinary System

The urinary bladder is adequately distended with anechoic contents. No masses, inflammatory changes, echogenic sediment or cystoliths are observed. The urinary bladder, trigone and visible pelvic urethra are normal in thickness with a smooth mucosal surface.

Kidneys are overall normal in size and shape with smooth peripheral margination. A normal 1:3 cortex to medulla ratio is maintained. The medulla and cortices are uniform in texture with some mild increased cortical echogenicity and mild loss of corticomedullary distinction, expected in this age patient. There is no evidence of pyelectasia, mineral or infarcts observed. Left kidney measures 4.1 cm. Right kidney measures 4.0 cm.

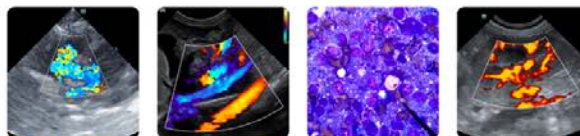
### Adrenal Glands

The right adrenal gland is normal in size (0.22 cm at cranial pole and 0.31 cm at caudal pole), shape and overall architecture, echogenicity and echotexture. Visible surrounding vasculature appears normal.

The left adrenal gland is normal in size (0.21 cm at cranial pole and 0.19 cm at caudal pole), shape and overall architecture, echogenicity and echotexture. Visible surrounding vasculature appears normal.

### Spleen

The spleen is subjectively normal in size with a normal smooth capsular contour. Parenchyma is appropriately finely textured and homogenous with normal echogenicity relative to surrounding tissue (hyperechoic to liver). No focal nodules or masses are observed. Splenic vasculature appears normal.



## PATIENT

Chubbs Hoffman

## SPECIES

Feline

## BREED

DSH

## SEX

Neutered Male

## AGE

13 Years

## WEIGHT

4.08 kg

## INTERPRETED BY

Beth Johnson, DVM  
DACVIM

## IMAGING PERFORMED BY

Renee Trionfetti, VMD

## HOSPITAL NAME

Firefly Veterinary  
Urgent Care

## REFERRING VET

Casey Dignan, VMD

## INVOICE

72774

## DATE

2/5/26

## Liver

Liver is subjectively enlarged (swollen contour) without disruption of architecture. It has a normal homogenous echotexture. Parenchyma is diffusely hyperechoic characterized by less prominent than normal portal vein walls and increased echogenicity relative to the spleen and falciform fat. In the mid to caudal liver there is a 5.7 cm x 7.0 cm, largely fluid filled, thick, hyperechoic, walled off structure that appears to originate from the biliary tract, but liver involvement can't be ruled out. Visible vasculature and biliary tree appear normal without distension or congestion.

The gallbladder is subjectively overdistended with anechoic contents as well as some suspended echogenic debris. It has a thick, irregular, hyperechoic wall and diffusely dilated, tortuous cystic and common bile ducts that appear in some views to attach to or potentially run through or adjacent the large fluid-filled density described above, with dilated tubular structures noted at the level of the duodenal papilla. No mineral is observed.

## Gastrointestinal

The visible stomach wall is normal in thickness and layering. The lumen of the stomach is empty with no evidence of obstruction, foreign material or infiltrative disease. Pyloric outflow tract appears patent.

The visible small intestine demonstrates areas of moderately thick muscularis layer relative to mucosa (disruption of the normal 1:3 muscularis:mucosa ratio). Small intestinal submucosa is slightly irregular, thick and hyperechoic, without evident loss of layering appreciated. The lumen of the small intestine is empty with no evidence of obstruction or foreign material.

The visible colon is normal in wall thickness (< 0.2 cm) and layering. Contents are consistent with normal formed feces and gas.

## Pancreas

Pancreas is prominent (enlarged) in size, hypoechoic to surrounding tissue and has a mildly irregular undulating contour. Parenchyma is coarse with mixed echogenic remodeling noted. A very mildly dilated tortuous pancreatic duct is suspected.

## Free Abdomen

There is no visible free peritoneal effusion noted in these images.

There is no apparent pathologic lymphadenopathy noted in these images.

## PRIMARY FINDINGS

- The biliary changes including the large, fluid-filled density could represent a benign process/cholangiohepatitis, with the large fluid filled structure potentially representing benign cystadenoma, hematoma, even an abscess, etc., although infiltrative neoplasia including carcinoma, round cell neoplasia, other can't be ruled out.
- Concurrent chronic low-grade smoldering pancreatitis is suspected, as is moderate inflammatory bowel disease (IBD) pattern – Thick muscularis has been reported with infiltrative bowel disease including both benign inflammatory disease as well as infiltrative neoplasia such as lymphoma. No loss of layering or distinct characteristics of malignancy are present. Therefore, differentials cannot be further ranked without tissue sampling.



## PATIENT

Chubbs Hoffman

## SPECIES

Feline

## BREED

DSH

## SEX

Neutered Male

## AGE

13 Years

## WEIGHT

4.08 kg

## INTERPRETED BY

Beth Johnson, DVM  
DACVIM

## IMAGING PERFORMED BY

Renee Trionfetti, VMD

## HOSPITAL NAME

Firefly Veterinary  
Urgent Care

## REFERRING VET

Casey Dignan, VMD

## INVOICE

72774

## DATE

2/5/26

## SECONDARY FINDINGS

- Age related kidney changes.

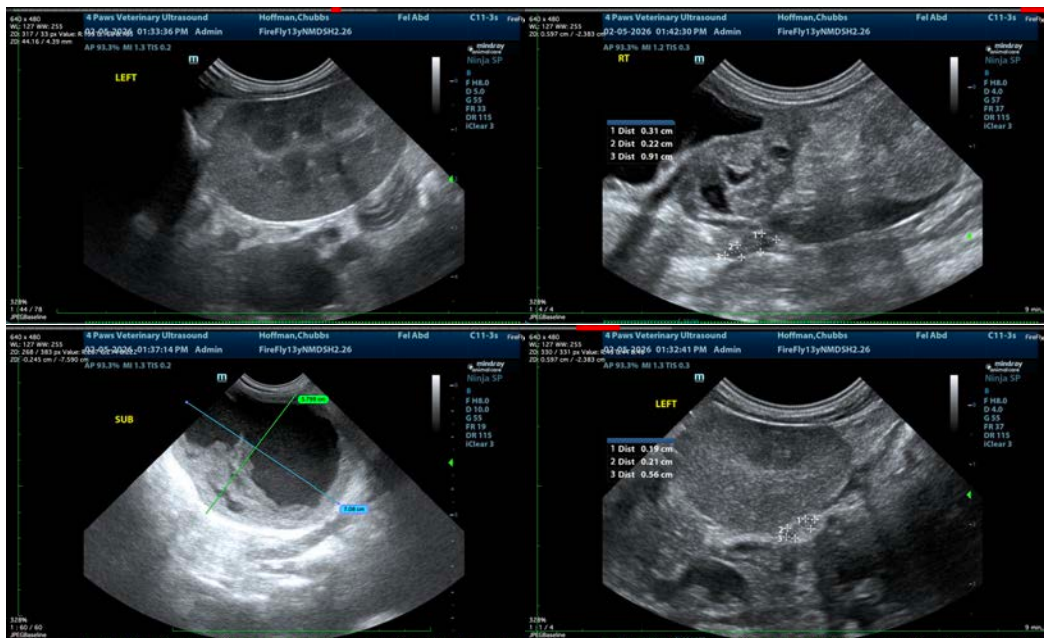
## INTERPRETATION OF THE FINDINGS & FURTHER RECOMMENDATIONS

A gastrointestinal malabsorption panel (including cobalamin, folate, TLI and PLI) to Texas A&M GI Laboratory is recommended for further evaluation of GI and pancreatic function.

Fine needle aspirates of the fluid filled mass for cytology, culture and sensitivity, etc., as well as sampling of the liver +/- pancreas could be considered if patient's coagulation status is appropriate.

In the meantime, treatment recommendations include fluid therapy, anti-emetics, gastroprotectants, hepatic nutraceuticals such as ursodiol and/or Denamarin, and broad-spectrum antibiotics. Nutritional support is critical to prevent/manage concurrent hepatic lipidosis, so appetite stimulants and/or, if indicated, feeding tube placement is also recommended.

If, however, clinical signs don't improve and/or patient negatively progresses, ultimately advanced imaging such as an abdominal contrast CT scan and/or even an exploratory laparotomy for further evaluation/sampling/removal of the fluid filled structure, as well as biopsies of the GI tract, being sure to include ileum, if possible, etc. may be necessary for definitive diagnosis, additional therapeutic intervention, etc.





## PATIENT

Chubbs Hoffman

## SPECIES

Feline

## BREED

DSH

## SEX

Neutered Male

## AGE

13 Years

## WEIGHT

4.08 kg

## INTERPRETED BY

Beth Johnson, DVM  
DACVIM

## IMAGING PERFORMED BY

Renee Trionfetti, VMD

## HOSPITAL NAME

Firefly Veterinary  
Urgent Care

## REFERRING VET

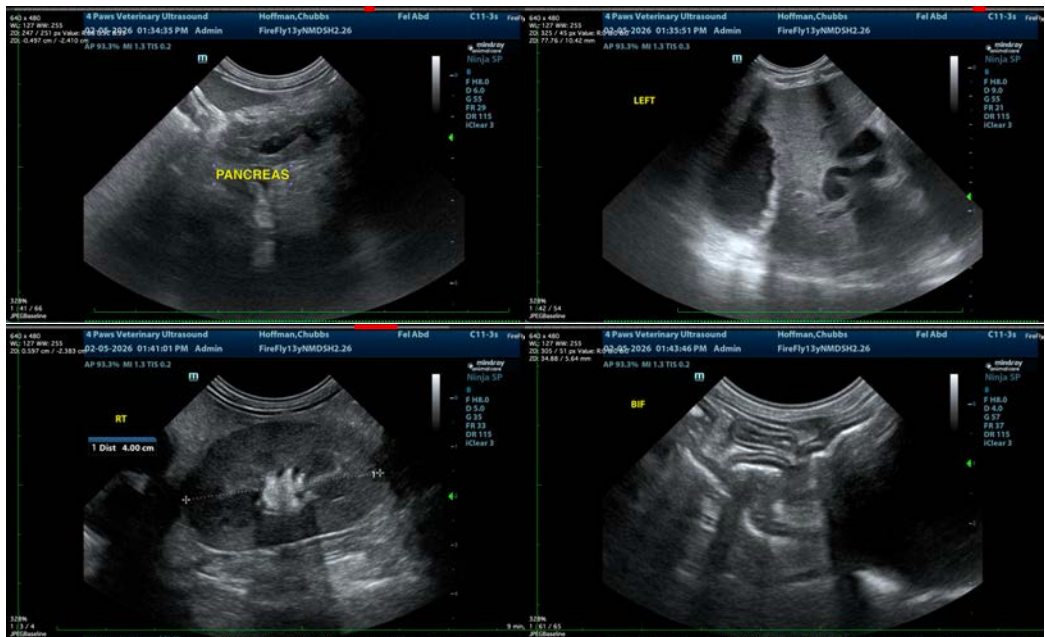
Casey Dignan, VMD

## INVOICE

72774

## DATE

2/5/26



The information and recommendations provided are based on the images presented by the referring veterinarian/sonographer. No evaluation can be communicated regarding pathology that was not visible in the image/video clips provided.

Thank you for this referral. If the clinical or image interpretation does not parallel your findings or if I can be of any further assistance please contact me.

Beth Johnson, DVM, DACVIM  
info@sonopath.com