



PATIENT

Cherie Esmeraldino

SPECIES

Canine

BREED

Pomeranian

SEX

Spayed Female

AGE

10 Years

WEIGHT

11

INTERPRETED BY

Beth Johnson, DVM
DACVIM

IMAGING PERFORMED BY

Dr. Reyes

HOSPITAL NAME

Graceful Paws Pet
Clinic

REFERRING VET

Dr. Reyes

INVOICE

72761

DATE

2/5/26

PRESENTING CLINICAL SIGNS

Off/on diarrhea that is not responding to high fiber or low fat diet. Pet is also losing weight despite good appetite and no vomiting. Pet also has a history of heart murmur and echo showed B2 stage, currently on Pimobendan

Abnormal PE/Chem/CBC/UA Results: GI panel pending today

ULTRASONOGRAPHIC EXAMINATION OF THE ABDOMEN

Urinary System

The urinary bladder is adequately distended with anechoic contents. No masses, inflammatory changes, echogenic sediment or cystoliths are observed. The urinary bladder, trigone and visible pelvic urethra are normal in thickness with a smooth mucosal surface.

Kidneys are overall normal in size and shape with smooth peripheral margination. A normal 1:3 cortex to medulla ratio is maintained. The medulla and cortices are uniform in texture with some mild increased cortical echogenicity and mild loss of corticomedullary distinction, expected in this age patient. There is no evidence of pyelectasia or infarcts observed. Left kidney measures 4.17 cm. Pinpoint non-obstructive mineral densities are noted in the left kidney. Right kidney measures 3.6 cm, no mineral present.

Adrenal Glands

The right adrenal gland is unable to be visualized in these images.

The left adrenal gland is normal in size (0.47 cm at cranial pole and 0.37 cm at caudal pole), shape and overall architecture, echogenicity and echotexture. Visible surrounding vasculature appears normal.

Spleen

The spleen is subjectively normal in size with a normal smooth capsular contour. Parenchyma is appropriately finely textured and homogenous with normal echogenicity relative to surrounding tissue (hyperechoic to liver). No focal nodules or masses are observed. Splenic vasculature appears normal.

Liver

The liver is subjectively normal in size with normal smooth curvilinear peripheral contour. Parenchyma is appropriately hypoechoic to the spleen in echogenicity and appropriately mildly coarse and homogenous in echotexture. No focal lesions are observed. Visible vasculature and biliary tree appear normal without distension or congestion.

The gallbladder is non-distended in size. The wall is smooth without visible thickening. Luminal contents are primarily anechoic. There is no evidence of cystic or common bile duct dilation.

Gastrointestinal

The visible stomach wall is normal in thickness and layering. The stomach is moderately distended with echogenic non-shadowing luminal contents and gas consistent with normal ingesta. There is no evidence of obstruction, foreign material or infiltrative disease. If patient was appropriately fasted, delayed gastric emptying could be considered. Non-shadowing foreign material is considered less likely but cannot be definitively ruled out.



PATIENT

Cherie Esmeraldino

If clinical signs are consistent (vomiting, etc.), recommendations include supportive medical care, 24 hours fasting and re-image.

SPECIES

Canine

The visible small intestines are normal in wall thickness and layering. Small intestinal motility appears adequate (1-3 contractions per min). The lumen is mildly distended with echogenic non-shadowing luminal contents and gas consistent with normal ingesta/chyme. There is no evidence of obstruction, foreign material or infiltrative disease.

BREED

Pomeranian

The visible colon is normal in wall thickness (< 0.2 cm) and layering. Contents are consistent with normal formed feces and gas.

Pancreas

SEX

Spayed Female

The pancreas that is observed appears appropriately isoechoic to surrounding omental fat. Visible capsule is smooth and normal in contour. Visible pancreatic parenchyma is homogenous and unremarkable. There is no visible pancreatic duct dilation. There is no evidence of active peripancreatic inflammation.

AGE

10 Years

Free Abdomen

WEIGHT

11

There is no visible free peritoneal effusion noted in these images.

There is no apparent pathologic lymphadenopathy noted in these images.

ULTRASONOGRAPHIC FINDINGS

INTERPRETED BY

Beth Johnson, DVM
DACVIM

- Mild age related kidney changes with pinpoint non-obstructive mineral densities noted in the left kidney.
- There is no definitive ultrasonographically visible intraabdominal explanation for patient's reported weight loss in the face of a normal appetite or diarrhea.

IMAGING PERFORMED BY

Dr. Reyes

INTERPRETATION OF THE FINDINGS & FURTHER RECOMMENDATIONS

Further gastrointestinal workup recommendations include:

HOSPITAL NAME

Graceful Paws Pet
Clinic

If not recently evaluated, a general metabolic health screen (CBC, chemistry panel with electrolytes and urinalysis) is recommended.

A routine fecal/giardia exam is recommended.

REFERRING VET

Dr. Reyes

A gastrointestinal malabsorption panel (including cobalamin, folate, TLI and PLI) to Texas A&M GI Laboratory is recommended for further evaluation of GI and pancreatic function.

INVOICE

72761

A fecal enteropathogen PCR panel to Texas A&M GI Laboratory could be considered for further evaluation of possible infectious disease. Contact lab for recommendations on how long to discontinue antibiotics (if indicated) prior to obtaining a stool sample for submission.

DATE

2/5/26

In the meantime, supportive/symptomatic medical management of clinical signs is recommended, including a probiotic (such as visbiome or proviable), empirical deworming with a 5-day course of Panacur and, if tolerated, a transition in diet, based on trial-and-error response, beginning possibly with a gastrointestinal biome diet vs a hydrolyzed protein diet vs other. Some patients respond to one brand/version of a hydrolyzed protein diet better than another brand, so several brand attempts may be required.



PATIENT

Cherie Esmeraldino

SPECIES

Canine

BREED

Pomeranian

SEX

Spayed Female

AGE

10 Years

WEIGHT

11

INTERPRETED BY

Beth Johnson, DVM
DACVIM

IMAGING PERFORMED BY

Dr. Reyes

HOSPITAL NAME

Graceful Paws Pet
Clinic

REFERRING VET

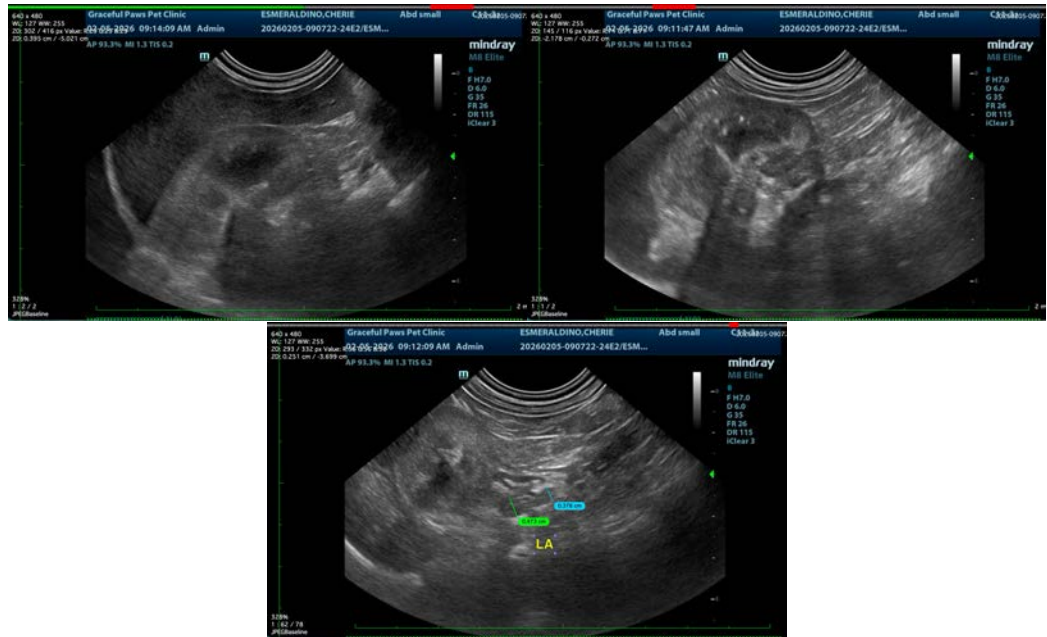
Dr. Reyes

INVOICE

72761

DATE

2/5/26



The information and recommendations provided are based on the images presented by the referring veterinarian/sonographer. No evaluation can be communicated regarding pathology that was not visible in the image/video clips provided.

Thank you for this referral. If the clinical or image interpretation does not parallel your findings or if I can be of any further assistance please contact me.

Beth Johnson, DVM, DACVIM
info@sonopath.com