



PATIENT

Camber Kendree

SPECIES

Canine

BREED

Beagle x

SEX

Spayed Female

AGE

12 Years 10 Months

WEIGHT

43.6

INTERPRETED BY

Beth Johnson, DVM
DACVIM

IMAGING PERFORMED BY

Carissa Hayden

HOSPITAL NAME

Elizabeth Animal
Hospital

REFERRING VET

Jen Redus, DVM

INVOICE

72773

DATE

2/5/26

PRESENTING CLINICAL SIGNS

Not eating for 2 - 3 days. Having yellow bile like diarrhea. She will eat treats; just not her normal food. No vomiting seen but there was some grass like maybe she threw that up. Panting.

Abnormal PE/Chem/CBC/UA Results: PE: Musculoskeletal: Advanced osteoarthritis at both elbows and both stifles. Muscle condition score grade 2 with moderate loss of muscle mass. Nails due for a trim. No recent blood work.

ULTRASONOGRAPHIC EXAMINATION OF THE ABDOMEN

Urinary System

The urinary bladder is adequately distended with anechoic contents. No masses, inflammatory changes, echogenic sediment or cystoliths are observed. The urinary bladder, trigone and visible pelvic urethra are normal in thickness with a smooth mucosal surface.

The right kidney is normal in size (5.37 cm), shape and echogenicity. It has smooth peripheral margination. There is a normal 1:3 cortex to medulla ratio with appropriate corticomedullary distinction. There is no evidence of pyelectasia, mineral or infarcts observed.

The left kidney is normal in size (5.37 cm), shape and echogenicity. It has smooth peripheral margination. There is a normal 1:3 cortex to medulla ratio with appropriate corticomedullary distinction. There is no evidence of pyelectasia, mineral or infarcts observed.

Adrenal Glands

The area of the right adrenal gland is examined without evident adrenal gland pathology.

The left adrenal gland is normal in size (0.61 cm at cranial pole and 0.58 cm at caudal pole), shape and overall architecture, echogenicity and echotexture. Visible surrounding vasculature appears normal.

Spleen

The spleen is subjectively normal in size with a normal smooth capsular contour. Parenchyma is appropriately finely textured and homogenous with normal echogenicity relative to surrounding tissue (hyperechoic to liver). No focal nodules or masses are observed. Splenic vasculature appears normal.

Liver

The liver is subjectively normal in size with normal smooth curvilinear peripheral contour. Parenchyma is appropriately hypoechoic to the spleen in echogenicity and appropriately mildly coarse and homogenous in echotexture. No focal lesions are observed. Visible vasculature and biliary tree appear normal without distension or congestion.

The gallbladder is non-distended in size. The wall is smooth without visible thickening. Luminal contents are primarily anechoic. There is no evidence of cystic or common bile duct dilation.

Gastrointestinal

The visible stomach wall is normal in thickness and layering. The lumen of the stomach is empty with no evidence of obstruction, foreign material or infiltrative disease. Pyloric outflow tract appears patent.

The visible small intestine demonstrates areas of mildly thick muscularis layer relative to mucosa (disruption of the normal 1:3 muscularis:mucosa ratio). Small intestinal submucosa is slightly irregular,



PATIENT

Camber Kendree

SPECIES

Canine

BREED

Beagle x

SEX

Spayed Female

AGE

12 Years 10 Months

WEIGHT

43.6

INTERPRETED BY

Beth Johnson, DVM
DACVIM

IMAGING PERFORMED BY

Carissa Hayden

HOSPITAL NAME

Elizabeth Animal
Hospital

REFERRING VET

Jen Redus, DVM

INVOICE

72773

DATE

2/5/26

thick and hyperechoic, without evident loss of layering appreciated. The lumen of the small intestine is empty with no evidence of obstruction or foreign material.

The visible colon is normal in wall thickness (< 0.2 cm) and layering. Contents are consistent with normal formed feces and gas.

Pancreas

The pancreas that is observed appears appropriately isoechoic to surrounding omental fat. Visible capsule is smooth and normal in contour. Visible pancreatic parenchyma is homogenous and unremarkable. There is no visible pancreatic duct dilation. There is no evidence of active peripancreatic inflammation.

Free Abdomen

There is no visible free peritoneal effusion noted in these images.

There is no apparent pathologic lymphadenopathy noted in these images.

ULTRASONOGRAPHIC FINDINGS

- Mild/emerging inflammatory bowel disease (IBD) pattern – Thick muscularis has been reported with infiltrative bowel disease including both benign inflammatory disease as well as infiltrative neoplasia such as lymphoma. No loss of layering or distinct characteristics of malignancy are present. Therefore, differentials cannot be further ranked without tissue sampling.

INTERPRETATION OF THE FINDINGS & FURTHER RECOMMENDATIONS

The bowel changes described above are very mild/subtle and could be in part normal patient variant in a senior dog, although could indicate early or emerging bowel disease, especially given clinical history. Therefore, further gastrointestinal workup recommendations include:

If not recently evaluated, a general metabolic health screen (CBC, chemistry panel with electrolytes and urinalysis) is recommended.

A routine fecal/giardia exam is recommended.

A gastrointestinal malabsorption panel (including cobalamin, folate, TLI and PLI) to Texas A&M GI Laboratory is recommended for further evaluation of GI and pancreatic function.

A fecal enteropathogen PCR panel to Texas A&M GI Laboratory could be considered for further evaluation of possible infectious disease. Contact lab for recommendations on how long to discontinue antibiotics (if indicated) prior to obtaining a stool sample for submission.

In the meantime, supportive/symptomatic medical management of clinical signs is recommended, including a probiotic (such as visbiome or proviable), empirical deworming with a 5-day course of Panacur and, if tolerated, a transition in diet, based on trial-and-error response, beginning possibly with a gastrointestinal biome diet vs a hydrolyzed protein diet vs other. Some patients respond to one brand/version of a hydrolyzed protein diet better than another brand, so several brand attempts may be required.

If clinical signs persist and a diagnosis is not made, ultimately biopsies of the GI tract, being sure to include ileum, if possible, may be necessary for definitive diagnosis and therefore to further guide medical management.



PATIENT

Camber Kendree

SPECIES

Canine

BREED

Beagle x

SEX

Spayed Female

AGE

12 Years 10 Months

WEIGHT

43.6

INTERPRETED BY

Beth Johnson, DVM
DACVIM

IMAGING PERFORMED BY

Carissa Hayden

HOSPITAL NAME

Elizabeth Animal
Hospital

REFERRING VET

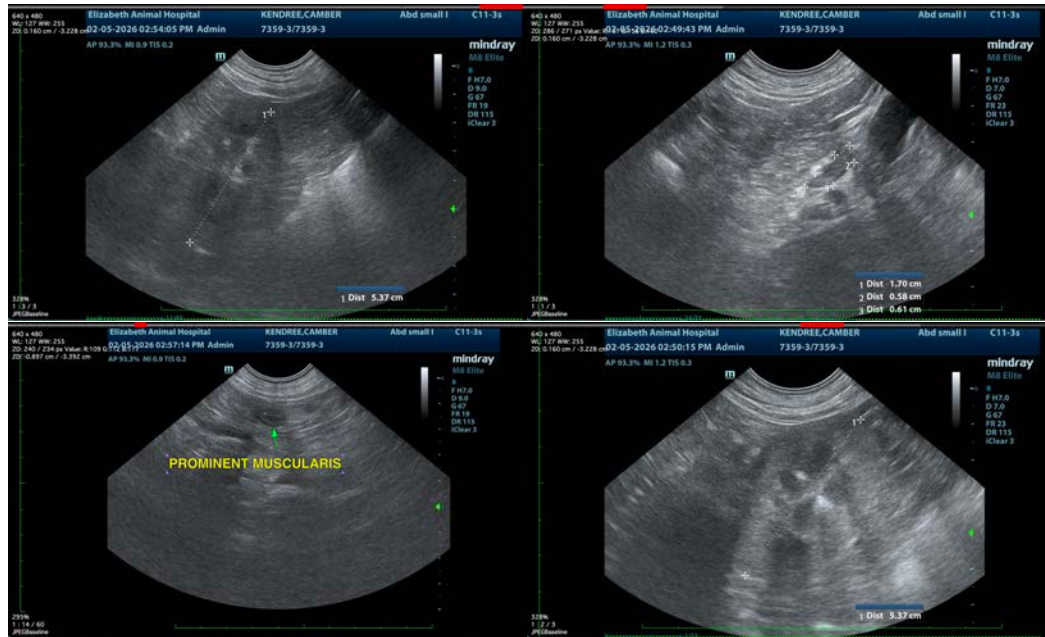
Jen Redus, DVM

INVOICE

72773

DATE

2/5/26



The information and recommendations provided are based on the images presented by the referring veterinarian/sonographer. No evaluation can be communicated regarding pathology that was not visible in the image/video clips provided.

Thank you for this referral. If the clinical or image interpretation does not parallel your findings or if I can be of any further assistance please contact me.

Beth Johnson, DVM, DACVIM
info@sonopath.com