

## PATIENT

Timmy Conlon

## SPECIES

Feline

## BREED

DSH

## SEX

Neutered Male

## AGE

7 Years

## WEIGHT

7.9 lbs

## INTERPRETED BY

Beth Johnson, DVM  
DACVIM

## IMAGING PERFORMED BY

Jill Rumachik

## HOSPITAL NAME

Clarity Imaging LLC

## REFERRING VET

Dr. Kara Hutter

## INVOICE

72692

## DATE

2/4/26

## PRESENTING CLINICAL SIGNS

V/D at home; some inappetence noted. Large abdominal mass palpated.

Abnormal PE/Chem/CBC/UA Results: Mild thrombocytopenia; ALB = 2.0; FELV/FIV = neg. Remainder of chemistry/CBC WNL.

## ULTRASONOGRAPHIC EXAMINATION OF THE ABDOMEN

### Urinary System

Urinary bladder is adequately distended. It has a normal uniform wall thickness. Contents include primarily anechoic fluid with occasional echogenic non-shadowing debris, most consistent with incidental suspended lipid in a cat, possibly combined with exfoliated cells, mucous and/or small blood clots. Both sterile inflammation as well as urinary tract infection can also present with echogenic debris. No masses or definitive cystoliths are observed. The trigone and visible pelvic urethra are normal in thickness with a smooth mucosal surface.

The right kidney is normal in size (3.64 cm), shape and echogenicity. It has smooth peripheral margination. There is a normal 1:3 cortex to medulla ratio with appropriate corticomedullary distinction. There is no evidence of pyelectasia, mineral or infarcts observed.

The left kidney is normal in size (3.29 cm), shape and echogenicity. It has smooth peripheral margination. There is a normal 1:3 cortex to medulla ratio with appropriate corticomedullary distinction. There is no evidence of pyelectasia, mineral or infarcts observed.

### Adrenal Glands

The adrenal glands are unable to be well visualized in these images.

### Spleen

The spleen is subjectively normal in size with a normal smooth capsular contour. Parenchyma is appropriately finely textured and homogenous with normal echogenicity relative to surrounding tissue (hyperechoic to liver). No focal nodules or masses are observed. Splenic vasculature appears normal.

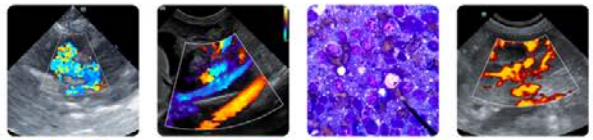
### Liver

The liver is subjectively normal in size with normal smooth curvilinear peripheral contour. Parenchyma is appropriately hypoechoic to the spleen in echogenicity and appropriately mildly coarse and homogenous in echotexture. No focal lesions are observed. Visible vasculature and biliary tree appear normal without distension or congestion.

The gallbladder is non-distended in size. The wall is smooth without visible thickening. Luminal contents are primarily anechoic. There is no evidence of cystic or common bile duct dilation.

### Gastrointestinal

The visible stomach wall is normal in thickness and layering. The lumen of the stomach is mildly distended with a small to moderate amount of echogenic non-shadowing luminal contents and gas consistent with normal ingesta. There is no evidence of obstruction, foreign material or infiltrative disease. Pyloric outflow tract appears patent.



## PATIENT

Timmy Conlon

## SPECIES

Feline

## BREED

DSH

## SEX

Neutered Male

## AGE

7 Yeara

## WEIGHT

7.9 lbs

## INTERPRETED BY

Beth Johnson, DVM  
DACVIM

## IMAGING PERFORMED BY

Jill Rumachik

## HOSPITAL NAME

Clarity Imaging LLC

## REFERRING VET

Dr. Kara Hutter

## INVOICE

72692

## DATE

2/4/26

In the mid abdomen there is a small bowel mass/suspect jejunum measuring 4.6+ cm long x overall 2.1 cm thick, characterized by a hypoechoic 1.0 cm thick bowel wall with complete loss of normal layering. The remaining visible small intestine demonstrates areas of moderately thick muscularis layer relative to mucosa (disruption of the normal 1:3 muscularis:mucosa ratio). Small intestinal submucosa is slightly irregular, thick and hyperechoic, without evident loss of layering appreciated. The lumen of the small intestine is empty with no evidence of obstruction or foreign material.

The visible colon is normal in wall thickness (< 0.2 cm) and layering. Contents are consistent with normal formed feces and gas.

### ***Pancreas***

The pancreas that is observed appears appropriately isoechoic to surrounding omental fat. Visible capsule is smooth and normal in contour. Visible pancreatic parenchyma is homogenous and unremarkable. There is no visible pancreatic duct dilation. There is no evidence of active peripancreatic inflammation.

### ***Free Abdomen***

Mesenteric lymph nodes are enlarged with swollen irregular capsular contour and loss of normal length to width ratio (rounded in shape). Nodes are hypoechoic with loss of normal parenchymal detail.

## **PRIMARY FINDINGS**

- The bowel mass is most concerning for infiltrative neoplasia such as round cell neoplasia i.e., lymphoma versus carcinoma versus other, especially given the concurrent adjacent lymphadenopathy.

## **SECONDARY FINDINGS**

- Mild to moderate amount of echogenic urinary bladder debris.

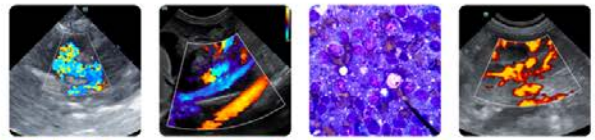
## **INTERPRETATION OF THE FINDINGS & FURTHER RECOMMENDATIONS**

Three view thoracic radiographs are recommended for further assessment of cardio-pulmonary status as well as to further evaluate for any evidence of metastatic disease, if not recently evaluated.

A gastrointestinal malabsorption panel (including cobalamin, folate, TLI and PLI) to Texas A&M GI Laboratory is recommended for further evaluation of GI and pancreatic function.

Fine needle aspirates of the bowel mass +/- adjacent lymph nodes are recommended if patient's coagulation status is appropriate.

Other than supportive/symptomatic medical management of clinical signs, further treatment recommendations are largely dependent on results of the above.



## PATIENT

Timmy Conlon

## SPECIES

Feline

## BREED

DSH

## SEX

Neutered Male

## AGE

7 Years

## WEIGHT

7.9 lbs

## INTERPRETED BY

Beth Johnson, DVM  
DACVIM

## IMAGING PERFORMED BY

Jill Rumachik

## HOSPITAL NAME

Clarity Imaging LLC

## REFERRING VET

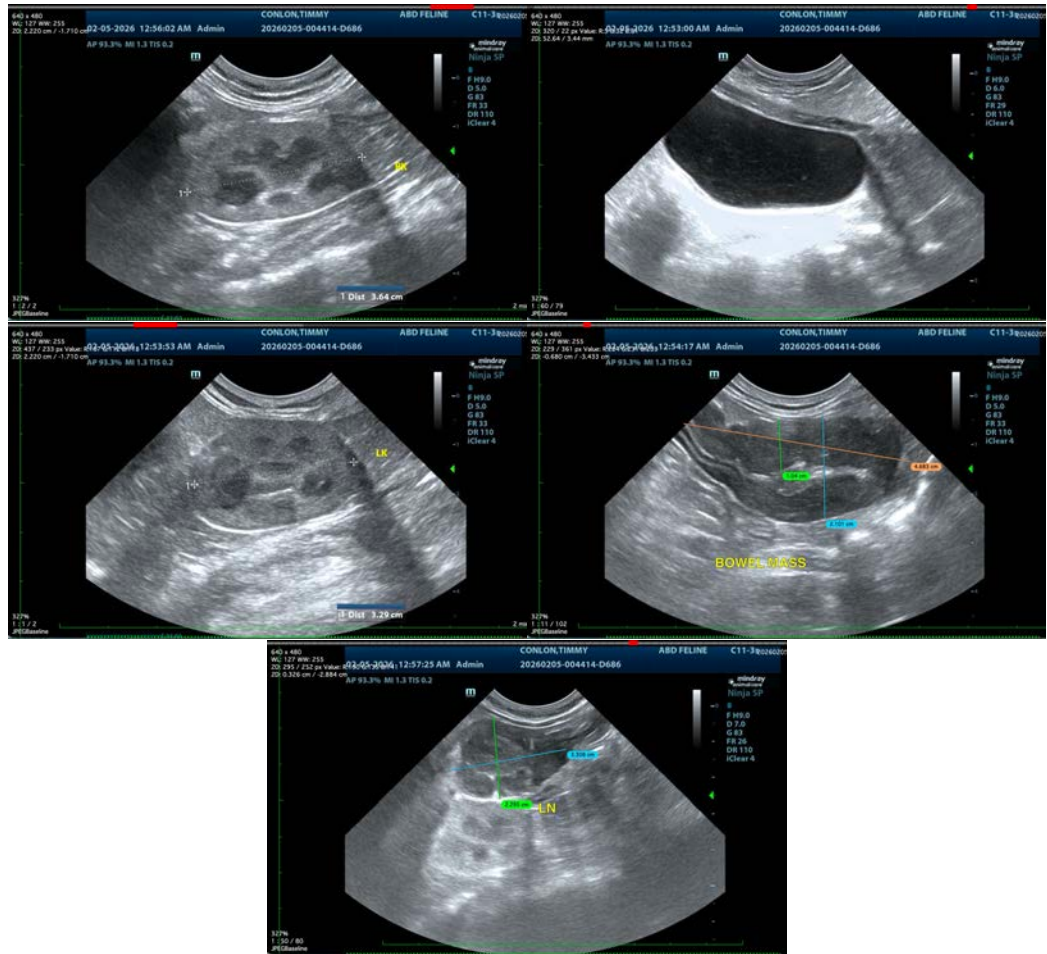
Dr. Kara Hutter

## INVOICE

72692

## DATE

2/4/26



The information and recommendations provided are based on the images presented by the referring veterinarian/sonographer. No evaluation can be communicated regarding pathology that was not visible in the image/video clips provided.

Thank you for this referral. If the clinical or image interpretation does not parallel your findings or if I can be of any further assistance please contact me.

**Beth Johnson, DVM, DACVIM**  
info@sonopath.com