



PATIENT

Princess Lara

SPECIES

Canine

BREED

Poodle

SEX

Spayed Female

AGE

15

WEIGHT

16

INTERPRETED BY

Beth Johnson, DVM
DACVIM

IMAGING PERFORMED BY

Gordon Brackee, DVM

HOSPITAL NAME

Bradenton Veterinary
Hospital

REFERRING VET

Gordon Brackee, DVM

INVOICE

72730

DATE

2/4/26

PRESENTING CLINICAL SIGNS

Patient active and eating well. Routine screen blood work of 2 weeks ago found moderate increase in liver enzymes. O noticed within the last 2 days development of yellow-tinged skin. Blood work today found significant elevation of liver enzymes and tBili. GI parasite screen negative by PCR.

Abnormal PE/Chem/CBC/UA Results: 1-20-2026 : Tpro 7.7 hi, Glob 4.9 hi, AST 130 hi, ALT 817 hi, AP 937 hi, tBili 0.8 hi, WBC 16.3 hi 2-4-2026 : ALB 2.4, Gluc 130, ALT >1000, ALP >993, GGT 112, tBili 2.0

ULTRASONOGRAPHIC EXAMINATION OF THE ABDOMEN

Urinary System

The urinary bladder is adequately distended with anechoic contents. No masses, inflammatory changes, echogenic sediment or cystoliths are observed. The urinary bladder, trigone and visible pelvic urethra are normal in thickness with a smooth mucosal surface.

Kidneys are overall normal in size and shape with smooth peripheral margination. A normal 1:3 cortex to medulla ratio is maintained. The medulla and cortices are uniform in texture with some mild increased cortical echogenicity and mild loss of corticomedullary distinction, expected in this age patient. No mineral or infarcts observed. Mild pyelectasia is noted in the left kidney. Left kidney measures 3.37 cm. Right kidney measures 4.51 cm. A hyperechoic band parallel to the corticomedullary border is present.

Adrenal Glands

The adrenal glands are unable to be well visualized in these images.

Spleen

The spleen is subjectively normal in size with a normal smooth capsular contour. Parenchyma is appropriately finely textured and homogenous with normal echogenicity relative to surrounding tissue (hyperechoic to liver). No focal nodules or masses are observed. Splenic vasculature appears normal.

Liver

Liver is normal to subjectively small in size with slightly undulating or scalloped capsular contour or margins. Parenchyma is diffusely heterogenous with increased portal markings and coarse architecture. No focal nodules or masses are observed. Visible vasculature and biliary tree appear normal without distension or congestion.

Gallbladder is moderately distended with anechoic bile as well as suspended and gravity dependent echogenic debris. The wall is smooth without visible thickening. There is no evidence of cystic or CBD dilation. There is no evidence of effusion or inflammation.

Gastrointestinal

The visible stomach wall is normal in thickness and layering. The lumen of the stomach is empty with no evidence of obstruction, foreign material or infiltrative disease. Pyloric outflow tract appears patent.

The visible small intestines are normal in wall thickness and layering. Small intestinal motility appears adequate (1-3 contractions per min). The lumen of the small intestine is empty with no evidence of obstruction, foreign material or infiltrative disease.



PATIENT

Princess Lara

SPECIES

Canine

BREED

Poodle

SEX

Spayed Female

AGE

15

WEIGHT

16

INTERPRETED BY

Beth Johnson, DVM
DACVIM

IMAGING PERFORMED BY

Gordon Brackee, DVM

HOSPITAL NAME

Bradenton Veterinary
Hospital

REFERRING VET

Gordon Brackee, DVM

INVOICE

72730

DATE

2/4/26

The colon is very mildly thick in the distal descending area, measuring 0.25 cm thick, with normal intact layering present. The lumen is empty.

Pancreas

The area of the pancreas contains irregular hyperechoic pancreatic remodeling.

Free Abdomen

There is no visible free peritoneal effusion noted in these images.

There is no apparent pathologic lymphadenopathy noted in these images.

ULTRASONOGRAPHIC FINDINGS

- An obvious cause for the liver changes is not identified in these images. Microscopic disease such as Leptospirosis, bacterial cholangiohepatitis, chronic active hepatitis, copper-associated hepatotoxicity, other hepatotoxicity, other reactive hepatopathy, infiltrative neoplasia, etc. cannot be definitively ruled out.
- Hyperechoic pancreas – This finding is suggestive of pancreatic fibrosis, possibly secondary to chronic pancreatitis. A TLI is recommended to rule out exocrine pancreatic insufficiency (EPI), especially if clinical signs (weight loss, diarrhea, etc.) are present.
- Mild gallbladder debris - Cholecystic debris is of unknown clinical significance. It can be seen with biliary stasis from fasting or illness. Cholecystic debris is not necessarily related to hepatobiliary disease. Echogenic bile is most commonly an incidental finding in dogs and should be interpreted in combination with clinical signs such as nausea, inappetence, cranial abdominal discomfort and/or laboratory changes such as increased ALP and/or increased Tbili.
- Bilateral medullary rim sign - This finding is of unknown clinical significance and can be a normal variant, often idiopathic. Medullary rim sign can be present with renal disease including lymphoma, hypercalcemic nephropathy, Leptospirosis, tubular disease, other and should be interpreted in combination with other more specific indications of kidney disease such as isosthenuria, proteinuria, azotemia, etc. This is a common incidental finding in patients with diabetes mellitus.
- Mild pyelectasia in the left kidney.
- Mildly thick distal descending colon – Trends in appearance toward benign. Infiltrative neoplasia can't be ruled out but is considered less likely.

INTERPRETATION OF THE FINDINGS & FURTHER RECOMMENDATIONS

Given the subtle pancreatic changes, a gastrointestinal malabsorption panel (including cobalamin, folate, TLI and PLI) to Texas A&M GI Laboratory is recommended for further evaluation of GI and pancreatic function.

In the meantime, further workup of the suspected underlying hepatopathy is recommended. Comprehensive infectious disease evaluation including testing for Leptospirosis could be considered, but ultimately biopsies of the liver, being sure to include copper level assessment, are likely indicated for a definitive diagnosis and therefore to further guide medical management.



PATIENT

Princess Lara

SPECIES

Canine

BREED

Poodle

SEX

Spayed Female

AGE

15

WEIGHT

16

INTERPRETED BY

Beth Johnson, DVM
DACVIM

IMAGING PERFORMED BY

Gordon Brackee, DVM

HOSPITAL NAME

Bradenton Veterinary
Hospital

REFERRING VET

Gordon Brackee, DVM

INVOICE

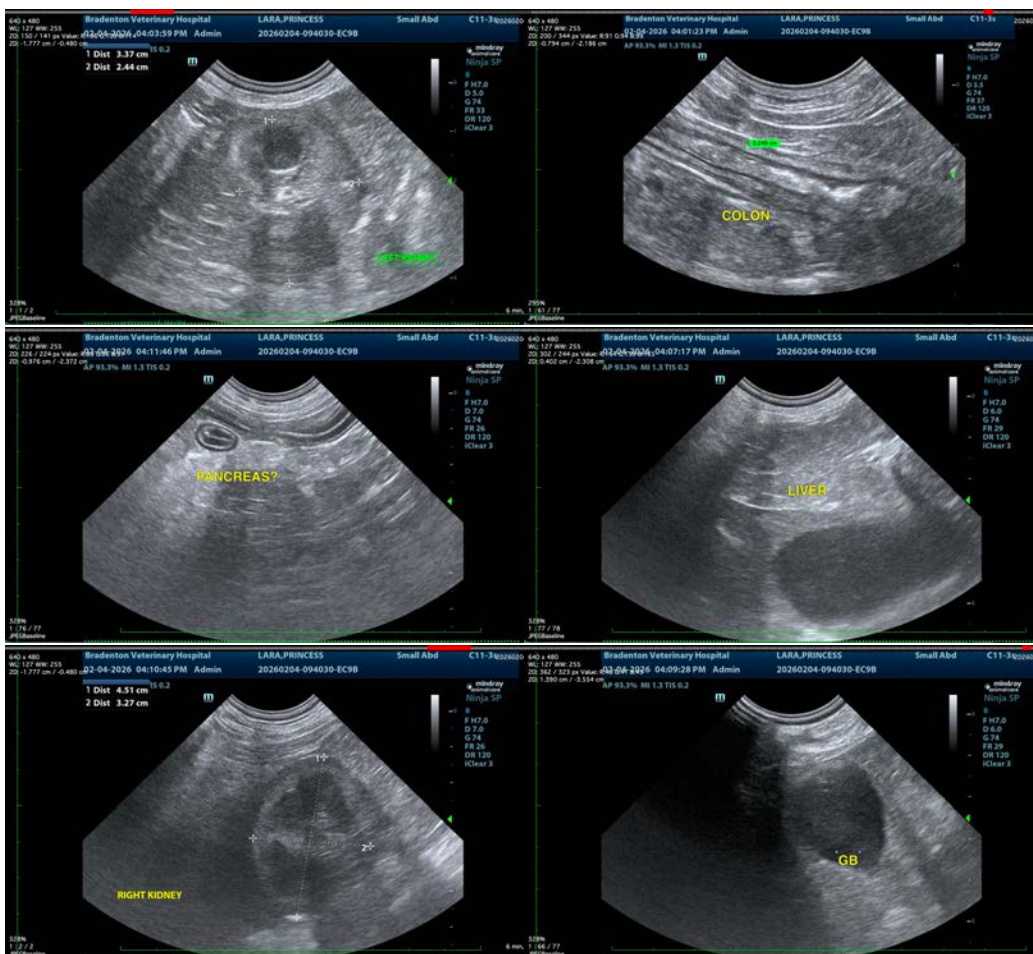
72730

DATE

2/4/26

Additionally, if not recently evaluated, a urinalysis and, if indicated based on urinalysis results, urine culture is recommended. If protein is present in an otherwise quiet sediment, protein quantification with a urine protein to creatinine ratio is recommended.

Other than supportive/symptomatic medical management of clinical signs, further diagnostic and treatment recommendations are largely dependent on results of the above.



The information and recommendations provided are based on the images presented by the referring veterinarian/sonographer. No evaluation can be communicated regarding pathology that was not visible in the image/video clips provided.

Thank you for this referral. If the clinical or image interpretation does not parallel your findings or if I can be of any further assistance please contact me.

Beth Johnson, DVM, DACVIM
info@sonopath.com