



**PATIENT**

Mittens Torpey

**SPECIES**

Feline

**BREED**

DSH

**SEX**

Spayed Female

**AGE**

12 Years

**WEIGHT**

8 lbs

**INTERPRETED BY**

Beth Johnson, DVM  
DACVIM

**IMAGING PERFORMED BY**

Kerri Becker

**HOSPITAL NAME**

Glen Rock Veterinary  
Hospital

**REFERRING VET**

Dr. Stekler

**INVOICE**

72718

**DATE**

2/4/26

**PRESENTING CLINICAL SIGNS**

Wt loss, decr. appetite, possible abd. mass.

Abnormal PE/Chem/CBC/UA Results: Calc-12.5 usg-1.025

**ULTRASONOGRAPHIC EXAMINATION OF THE ABDOMEN**

**Urinary System**

The urinary bladder is adequately distended with anechoic contents. No masses, inflammatory changes, echogenic sediment or cystoliths are observed. The urinary bladder, trigone and visible pelvic urethra are normal in thickness with a smooth mucosal surface.

Kidneys are overall normal in size and shape with smooth peripheral margination. A normal 1:3 cortex to medulla ratio is maintained. The medulla and cortices are uniform in texture with some mild increased cortical echogenicity and mild loss of corticomedullary distinction, expected in this age patient. There is no evidence of pyelectasia, mineral or infarcts observed. Left measures 4.46 cm. Right measures 4.69 cm.

**Adrenal Glands**

The right adrenal gland is normal in size (0.42 cm), shape and overall architecture, echogenicity and echotexture. Visible surrounding vasculature appears normal.

The left adrenal gland is normal in size (0.45 cm), shape and overall architecture, echogenicity and echotexture. Visible surrounding vasculature appears normal.

**Spleen**

The spleen is subjectively normal in size with a normal smooth capsular contour. Parenchyma is appropriately finely textured and homogenous with normal echogenicity relative to surrounding tissue (hyperechoic to liver). No focal nodules or masses are observed. Splenic vasculature appears normal.

**Liver**

Liver is subjectively enlarged (swollen contour) without disruption of architecture. It has a normal homogenous echotexture. Parenchyma is diffusely hyperechoic characterized by less prominent than normal portal vein walls and increased echogenicity relative to the spleen and falciform fat. No focal lesions are observed. Visible vasculature and biliary tree appear normal without distension or congestion.

The gallbladder is non-distended in size. The wall is smooth without visible thickening. Luminal contents are primarily anechoic. There is no evidence of cystic or common bile duct dilation.

**Gastrointestinal**

The visible stomach wall is normal in thickness and layering. The lumen of the stomach is empty with no evidence of obstruction, foreign material or infiltrative disease. Pyloric outflow tract appears patent.

In the mid to caudal abdomen is an approximately 5.5 cm x 3.4 cm bowel mass characterized by a thick, hypoechoic wall and complete loss of normal layering concentrically. The remaining small intestines are normal in wall thickness and layering. Small intestinal motility appears adequate (1-3 contractions per



<b>PATIENT</b>	min). The lumen of the small intestine is empty with no evidence of obstruction, foreign material or infiltrative disease.
Mittens Torpey	
<b>SPECIES</b>	The visible colon is normal in wall thickness (< 0.2 cm) and layering. Contents are consistent with normal formed feces and gas.
Feline	<b><i>Pancreas</i></b>
<b>BREED</b>	The pancreas that is observed appears appropriately isoechoic to surrounding omental fat. Visible capsule is smooth and normal in contour. Visible pancreatic parenchyma is homogenous and unremarkable. There is no visible pancreatic duct dilation. There is no evidence of active peripancreatic inflammation.
DSH	
<b>SEX</b>	<b><i>Free Abdomen</i></b>
Spayed Female	There is no visible free peritoneal effusion noted in these images.
<b>AGE</b>	There is no apparent pathologic lymphadenopathy noted in these images.
12 Years	<b>PRIMARY FINDINGS</b>
<b>WEIGHT</b>	<ul style="list-style-type: none"> <li>The small bowel mass is concerning for infiltrative neoplasia such as round cell neoplasia i.e., lymphoma, given the loss of layering, etc. Having said that, a benign inflammatory process cannot be definitively ruled out without tissue sampling.</li> <li>Hyperechoic hepatomegaly – This appearance is most consistent with benign hepatic lipidosis or endocrine/DM hepatopathy. Infiltrative disease such as amyloidosis or round cell neoplasia, such as mast cell tumor or less likely, lymphoma, is also possible.</li> </ul>
8 lbs	
<b>INTERPRETED BY</b>	<b>SECONDARY FINDINGS</b>
Beth Johnson, DVM DACVIM	<ul style="list-style-type: none"> <li>Age related kidney changes.</li> </ul>
<b>IMAGING PERFORMED BY</b>	<b><u>INTERPRETATION OF THE FINDINGS &amp; FURTHER RECOMMENDATIONS</u></b>
Kerri Becker	Three view thoracic radiographs are recommended for further assessment of cardio-pulmonary status as well as to further evaluate for any evidence of metastatic disease, if not recently evaluated.
<b>HOSPITAL NAME</b>	A gastrointestinal malabsorption panel (including cobalamin, folate, TLI and PLI) to Texas A&M GI Laboratory is recommended for further evaluation of GI and pancreatic function.
Glen Rock Veterinary Hospital	Given the patient's hypercalcemia, a malignancy panel (PTH, PTHrP, iCa) to Michigan State College of Veterinary Medicine is recommended for further investigation of the reported hypercalcemia.
<b>REFERRING VET</b>	Fine needle aspirates of the bowel mass +/- liver are recommended if patient's coagulation status is appropriate.
Dr. Stekler	Other than supportive/symptomatic medical management of clinical signs, further treatment recommendations are largely dependent on results of the above.
<b>INVOICE</b>	
72718	
<b>DATE</b>	
2/4/26	



**PATIENT**

Mittens Torpey

**SPECIES**

Feline

**BREED**

DSH

**SEX**

Spayed Female

**AGE**

12 Years

**WEIGHT**

8 lbs

**INTERPRETED BY**

Beth Johnson, DVM  
 DACVIM

**IMAGING PERFORMED BY**

Kerri Becker

**HOSPITAL NAME**

Glen Rock Veterinary  
 Hospital

**REFERRING VET**

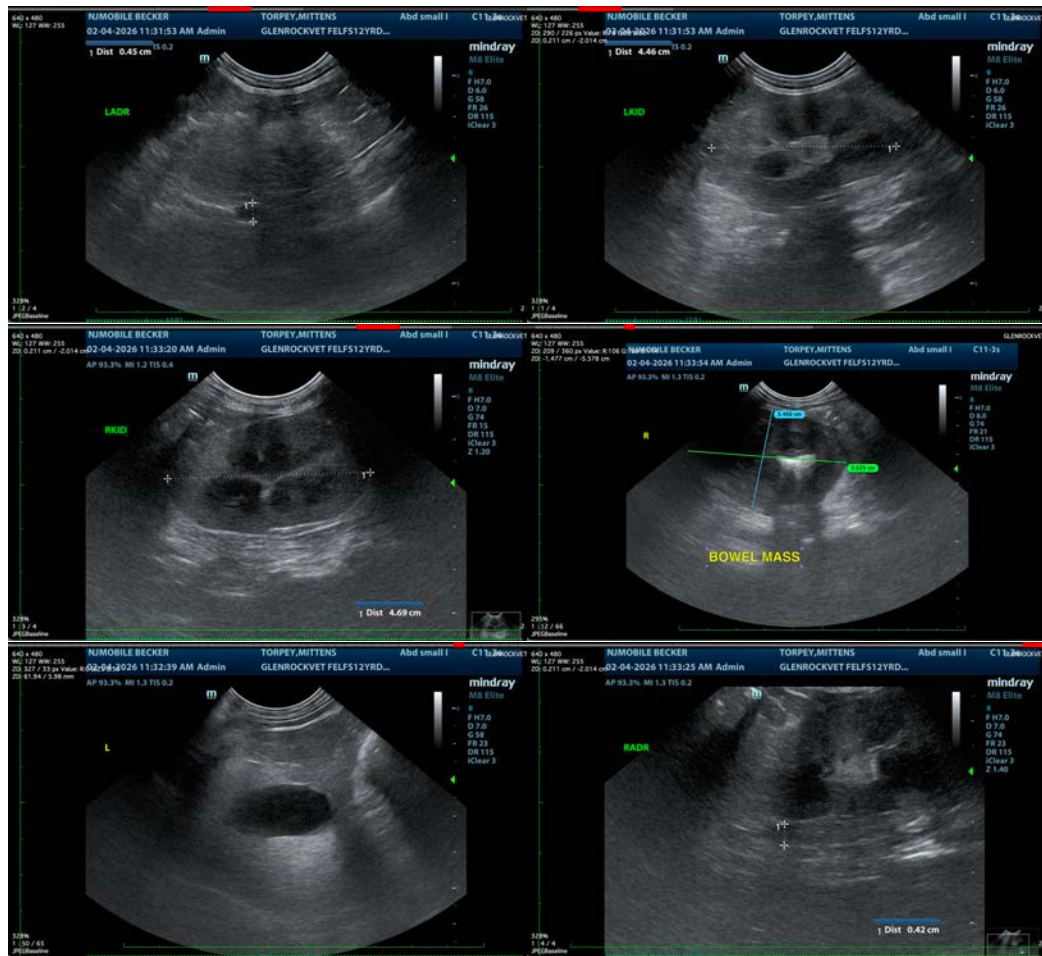
Dr. Stekler

**INVOICE**

72718

**DATE**

2/4/26



The information and recommendations provided are based on the images presented by the referring veterinarian/sonographer. No evaluation can be communicated regarding pathology that was not visible in the image/video clips provided.

Thank you for this referral. If the clinical or image interpretation does not parallel your findings or if I can be of any further assistance please contact me.

**Beth Johnson, DVM, DACVIM**  
 info@sonopath.com