



PATIENT

Coal Harris

SPECIES

Canine

BREED

Nova Scotia Duck
Tolling Retriever

SEX

MN

AGE

4 years

WEIGHT

20.4 kg

INTERPRETED BY

Beth Johnson, DVM
DACVIM

IMAGING PERFORMED BY

Dr. Sarah Barthelemy

HOSPITAL NAME

Southwood Veterinary
Hospital

REFERRING VET

Dr. Harris

INVOICE

11244

DATE

2/4/2026

PRESENTING CLINICAL SIGNS

- Recheck AUS from June 2025. Has been on budesonide low dose and doing extremely well.

ULTRASONOGRAPHIC EXAMINATION OF THE ABDOMEN

Urinary System

The urinary bladder is adequately distended with anechoic contents. No masses, inflammatory changes, echogenic sediment or cystoliths are observed. The urinary bladder, trigone and visible pelvic urethra are normal in thickness with a smooth mucosal surface.

Prostate is normal in size, echotexture, and echogenicity for a neutered male.

The right kidney is normal in size (5.45 cm), shape and echogenicity. It has smooth peripheral margination. There is a normal 1:3 cortex to medulla ratio with appropriate corticomedullary distinction. There is no evidence of pyelectasia, mineral or infarcts observed.

The left kidney is normal in size (5.72 cm), shape and echogenicity. It has smooth peripheral margination. There is a normal 1:3 cortex to medulla ratio with appropriate corticomedullary distinction. There is no evidence of pyelectasia, mineral or infarcts observed.

Adrenal Glands

Adrenal glands are small (flattened contour). Corticomedullary structure is unremarkable. Visible surrounding vasculature appears normal. Left adrenal measures 0.3 cm at the cranial pole and 0.3 cm at the caudal pole. Right adrenal measures 0.4 cm at the cranial pole and 0.39 cm at the caudal pole.

Spleen

The spleen is subjectively normal in size with a normal smooth capsular contour. Parenchyma is appropriately finely textured and homogenous with normal echogenicity relative to surrounding tissue (hyperechoic to liver). A 0.4 cm x 0.6 cm non-capsular disrupting, hypo- to anechoic nodule is noted mid spleen. Splenic vasculature appears normal.

Liver

The liver is subjectively normal in size with normal smooth curvilinear peripheral contour. Parenchyma is appropriately hypoechoic to the spleen in echogenicity and appropriately mildly coarse and homogenous in echotexture. No focal lesions are observed. Visible vasculature and biliary tree appear normal without distension or congestion.

The gallbladder is non-distended in size. The wall is smooth without visible thickening. Luminal contents are primarily anechoic. There is no evidence of cystic or common bile duct dilation.

Gastrointestinal

The visible stomach wall is normal in thickness and layering. The lumen of the stomach is empty with no evidence of obstruction, foreign material or infiltrative disease. Pyloric outflow tract appears patent.



PATIENT

Coal Harris

SPECIES

Canine

BREED

Nova Scotia Duck
Tolling Retriever

SEX

MN

AGE

4 years

WEIGHT

20.4 kg

INTERPRETED BY

Beth Johnson, DVM
DACVIM

IMAGING PERFORMED BY

Dr. Sarah Barthelemy

HOSPITAL NAME

Southwood Veterinary
Hospital

REFERRING VET

Dr. Harris

INVOICE

11244

DATE

2/4/2026

The visible small intestines are normal in wall thickness and layering. Small intestinal motility appears adequate (1-3 contractions per min). The lumen of the small intestine is empty with no evidence of obstruction, foreign material or infiltrative disease.

The visible colon is normal in wall thickness (< 0.2 cm) and layering. Contents are consistent with normal formed feces and gas.

Pancreas

The pancreas that is observed appears appropriately isoechoic to surrounding omental fat. Visible capsule is smooth and normal in contour. Visible pancreatic parenchyma is homogenous and unremarkable. There is no visible pancreatic duct dilation. There is no evidence of active peripancreatic inflammation.

Free Abdomen

There is no visible free peritoneal effusion noted in these images.

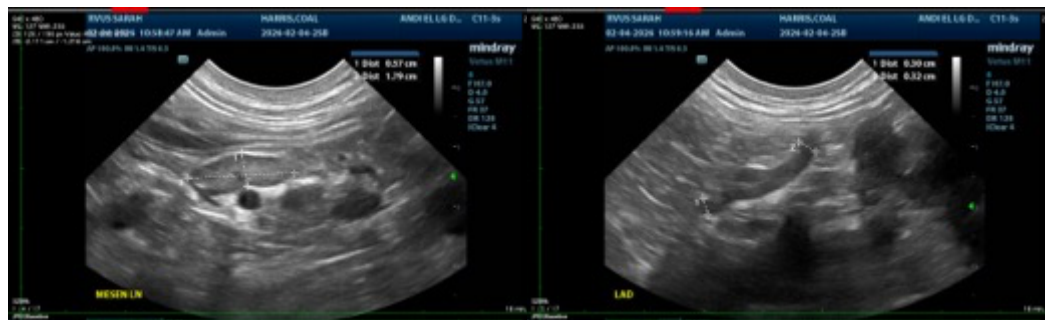
Mesenteric lymph nodes are prominent in size with swollen capsular contour. Normal elongated shape (length to width ratio) is maintained. There is no loss of parenchymal detail.

ULTRASONOGRAPHIC FINDINGS

- Moderately reactive mesenteric lymph nodes – infiltrative neoplastic disease cannot be ruled out but is considered less likely.
- Hypo to anechoic splenic nodules – likely represents a benign lesion such as a cyst, hematoma, nodular hyperplasia, extramedullary hematopoiesis, etc., however while considered less likely, infiltrative neoplasia can mimic benign lesions, and cannot be ruled out.
- The flat adrenal glands are likely secondary to patient's reported steroid history.

INTERPRETATION OF THE FINDINGS & FURTHER RECOMMENDATIONS

This is a static study in terms of the changes described above, the lymphadenopathy and the splenic nodule. However markedly improved study in terms of the appearance of the GI tract. Given patient's concurrent reported clinical improvement, continued supportive/symptomatic medical management of the suspected IBD/gastritis is recommended, as is reportedly already in place.





PATIENT

Coal Harris

SPECIES

Canine

BREED

Nova Scotia Duck
Tolling Retriever

SEX

MN

AGE

4 years

WEIGHT

20.4 kg

INTERPRETED BY

Beth Johnson, DVM
DACVIM

IMAGING PERFORMED BY

Dr. Sarah Barthelemy

HOSPITAL NAME

Southwood Veterinary
Hospital

REFERRING VET

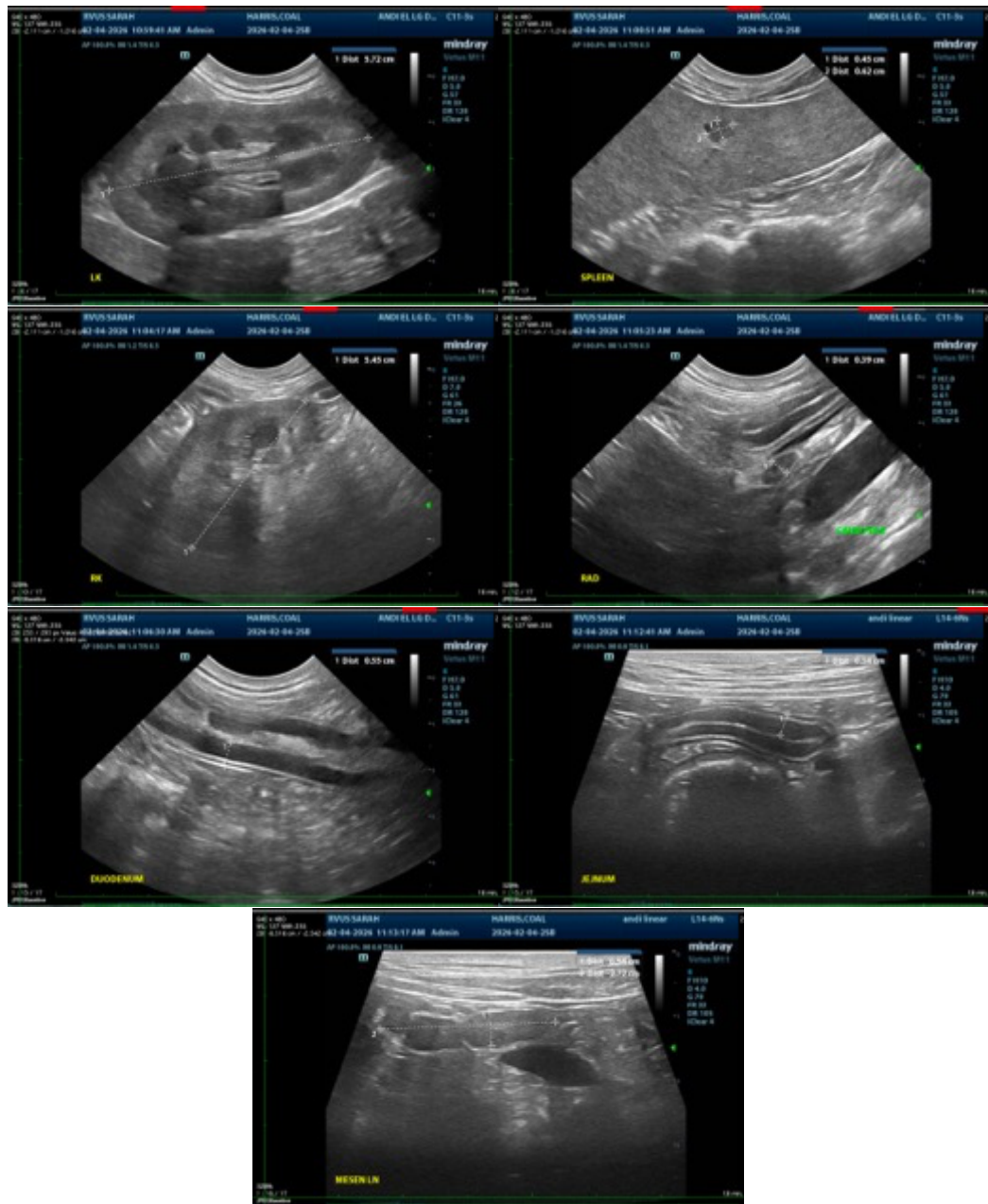
Dr. Harris

INVOICE

11244

DATE

2/4/2026



The information and recommendations provided are based on the images presented by the referring veterinarian/sonographer. No evaluation can be communicated regarding pathology that was not visible in the image/video clips provided.

Thank you for this referral. If the clinical or image interpretation does not parallel your findings or if I can be of any further assistance please contact me.

Beth Johnson, DVM, DACVIM
info@sonopath.com