



## PATIENT

Archer LoCastro

## SPECIES

Canine

## BREED

Boxer Mix

## SEX

MN

## AGE

11 years 2 months

## WEIGHT

71 lbs

## INTERPRETED BY

Beth Johnson, DVM  
DACVIM

## IMAGING PERFORMED BY

Dr. Kristen Carpenter

## HOSPITAL NAME

Pennridge Animal  
Hospital

## REFERRING VET

Dr. Peters

## INVOICE

11245

## DATE

2/4/2026

## PRESENTING CLINICAL SIGNS

- Patient sedated with Butorphanol.
- Splenectomy 10/2024 -- biopsy consistent with splenic hematoma and nodular hyperplasia.
- Patient here for pre-surgical screening for large SQ mass L ventral chest and abdomen. ALT and ALP elevations noted on bloodwork. PU/PD was noted by owner as the only recent clinical sign. Here for AUS prior to anesthesia/mass removal.
- Diagnostics: Bloodwork 1/14/26: HCT 40% ( 41-60), Phos 2.3 ( 2.5-6.1), ALT 345 ( 18-121), ALP 224 ( 5-160), T4 normal. 4dx neg x4. Fecal NOS. UA- USG 1.006, quiet sediment.

## ULTRASONOGRAPHIC EXAMINATION OF THE ABDOMEN

### Urinary System

The urinary bladder is adequately distended with anechoic contents. No masses, inflammatory changes, echogenic sediment or cystoliths are observed. The urinary bladder, trigone and visible pelvic urethra are normal in thickness with a smooth mucosal surface.

Prostate is normal in size, echotexture, and echogenicity for a neutered male.

The right kidney is normal is size (6.29 cm), shape and echogenicity. It has smooth peripheral margination. There is a normal 1:3 cortex to medulla ratio with appropriate corticomedullary distinction. There is no evidence of pyelectasia, mineral or infarcts observed.

The left kidney is normal is size (7.31 cm), shape and echogenicity. It has smooth peripheral margination. There is a normal 1:3 cortex to medulla ratio with appropriate corticomedullary distinction. There is no evidence of pyelectasia, mineral or infarcts observed.

### Adrenal Glands

The right adrenal gland is normal in size (1.3 cm at cranial pole and 0.7 cm at caudal pole), shape and overall architecture, echogenicity and echotexture. Visible surrounding vasculature appears normal.

The left adrenal gland is normal in size (0.7 cm at cranial pole and 0.6 cm at caudal pole), shape and overall architecture, echogenicity and echotexture. Visible surrounding vasculature appears normal.

### Spleen

The spleen has been previously removed.

### Liver

The liver is subjectively normal in size with normal smooth curvilinear peripheral contour. Parenchyma is appropriately hypoechoic to the spleen in echogenicity and appropriately mildly coarse and homogenous in echotexture. No focal lesions are observed. Visible vasculature and biliary tree appear normal without distension or congestion.

Gallbladder is moderately distended with anechoic bile as well as suspended and gravity dependent echogenic debris. The wall is smooth without visible thickening. There is no evidence of cystic or CBD dilation. There is no evidence of effusion or inflammation.

### Gastrointestinal



## PATIENT

Archer LoCastro

## SPECIES

Canine

## BREED

Boxer Mix

## SEX

MN

## AGE

11 years 2 months

## WEIGHT

71 lbs

## INTERPRETED BY

Beth Johnson, DVM  
DACVIM

## IMAGING PERFORMED BY

Dr. Kristen Carpenter

## HOSPITAL NAME

Pennridge Animal  
Hospital

## REFERRING VET

Dr. Peters

## INVOICE

11245

## DATE

2/4/2026

The visible stomach wall is normal in thickness and layering. The lumen of the stomach is mildly distended with very echogenic reverberation artifact from intraluminal gas. There is no evidence of obstruction, foreign material, or infiltrative disease; however, visualization is partially inhibited by gas. Pyloric outflow tract appears patent.

The visible small intestines are normal in wall thickness and layering. Small intestinal motility appears adequate (1-3 contractions per min). The lumen of the small intestine is empty with no evidence of obstruction, foreign material or infiltrative disease.

The visible colon is normal in wall thickness (< 0.2 cm) and layering. Contents are consistent with normal formed feces and gas.

### *Pancreas*

The pancreas that is observed appears appropriately isoechoic to surrounding omental fat. Visible capsule is smooth and normal in contour. Visible pancreatic parenchyma is homogenous and unremarkable. There is no visible pancreatic duct dilation. There is no evidence of active peripancreatic inflammation.

### *Free Abdomen*

There is no visible free peritoneal effusion noted in these images.

There is no apparent pathologic lymphadenopathy noted in these images.

## ULTRASONOGRAPHIC FINDINGS

- Moderate gallbladder debris - Cholecystic debris is of unknown clinical significance. It can be seen with biliary stasis from fasting or illness. Cholecystic debris is not necessarily related to hepatobiliary disease. Echogenic bile is most commonly an incidental finding in dogs and should be interpreted in combination with clinical signs such as nausea, inappetence, cranial abdominal discomfort and/or laboratory changes such as increased ALP and/or increased Tbili.
- Patient's spleen has previously been removed.
- An obvious cause for the reported increased liver enzymes is not identified in these images. Microscopic disease such as Leptospirosis, bacterial cholangiohepatitis, chronic active hepatitis, copper-associated hepatotoxicity, other hepatotoxicity, other reactive hepatopathy, infiltrative neoplasia (considered unlikely), etc. cannot be definitively ruled out.

## INTERPRETATION OF THE FINDINGS & FURTHER RECOMMENDATIONS

Differentials for a primary hepatocellular injury liver enzyme pattern (increased ALT) depend partially on the level of increase. Mild increases (less than 2 times normal) are often a "reactive hepatopathy" or the liver's response to an insult elsewhere in the body including, but not limited to, pancreatitis, gastroenteritis, parasitic disease, dental disease, vacuolar or endocrine hepatopathy from diabetes mellitus or hyperadrenocorticism (steroid-induced), hypoadrenocorticism, certain drugs (e.g. phenobarbital, corticosteroids, azathioprine, etc.), and muscle ALT (more likely if AST and CK concurrently increased).

It is a good indicator of active liver damage (cell membrane disruption, cellular necrosis), however, if the value is increased by at least 3-4 times normal. Differentials include infectious disease, including



**PATIENT**

Archer LoCastro

**SPECIES**

Canine

**BREED**

Boxer Mix

**SEX**

MN

**AGE**

11 years 2 months

**WEIGHT**

71 lbs

**INTERPRETED BY**

Beth Johnson, DVM  
DACVIM

**IMAGING PERFORMED BY**

Dr. Kristen Carpenter

**HOSPITAL NAME**

Pennridge Animal  
Hospital

**REFERRING VET**

Dr. Peters

**INVOICE**

11245

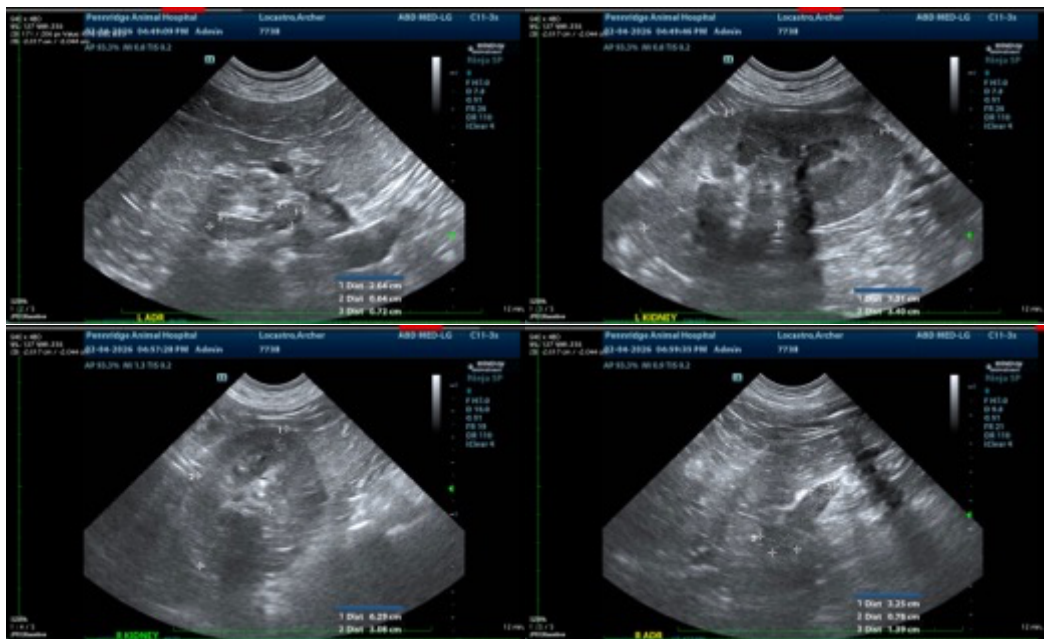
**DATE**

2/4/2026

Leptospirosis, inflammatory disease (ie. active hepatitis, copper, other), toxic insult as well as infiltrative neoplasia.

ALT levels vary in cases of vascular anomalies such as microvascular dysplasia and portosystemic shunts (PSS), but are often less significantly increased.

- Testing for Leptospirosis could be considered.
- Bile acids could be considered, if tbili is not increased.
- An empirical course of antibiotics and empirical hepatic nutraceuticals may be tried, with monitoring of ALT for improvement. If improvement is noted, antibiotics should be continued until liver enzymes either normalize or plateau (recheck every 2-3 weeks); however, if improvement is not noted and/or enzyme increase progresses, antibiotics should not be continued long term and liver tissue sampling is recommended.
- FNA of the liver can be performed to assess inflammatory cell type, rule in/out round cell neoplasia, etc. (if patient's coagulation status is appropriate).
- If round cell neoplasia is not diagnosed, a liver biopsy (including copper level assessment) may be required to definitively diagnose the underlying hepatopathy.





## PATIENT

Archer LoCastro

## SPECIES

Canine

## BREED

Boxer Mix

## SEX

MN

## AGE

11 years 2 months

## WEIGHT

71 lbs

## INTERPRETED BY

Beth Johnson, DVM  
DACVIM

## IMAGING PERFORMED BY

Dr. Kristen Carpenter

## HOSPITAL NAME

Pennridge Animal  
Hospital

## REFERRING VET

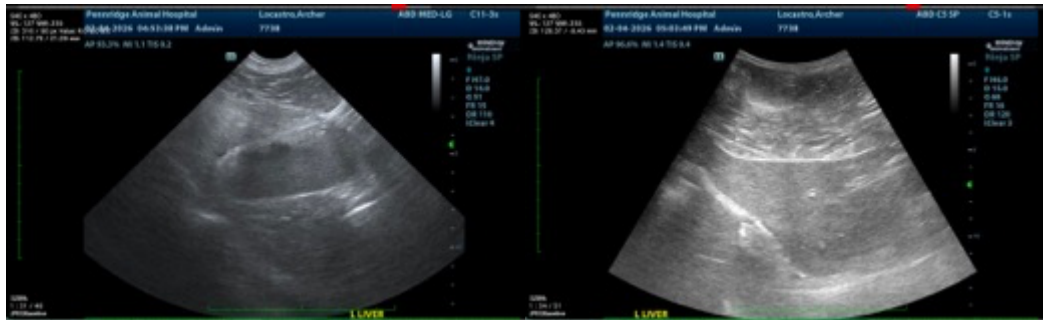Dr. Peters

## INVOICE

11245

## DATE

2/4/2026



The information and recommendations provided are based on the images presented by the referring veterinarian/sonographer. No evaluation can be communicated regarding pathology that was not visible in the image/video clips provided.

Thank you for this referral. If the clinical or image interpretation does not parallel your findings or if I can be of any further assistance please contact me.

**Beth Johnson, DVM, DACVIM**  
info@sonopath.com