



**PATIENT**

Bennie Sandt

**SPECIES**

Canine

**BREED**

St. Bernard

**SEX**

Neutered Male

**AGE**

7 Years

**WEIGHT**

153 lbs

**INTERPRETED BY**

Beth Johnson, DVM  
DACVIM

**IMAGING PERFORMED BY**

Rebecca Hamilton

**HOSPITAL NAME**

Nazareth Veterinary  
Center

**REFERRING VET**

Dr. Bankowski

**INVOICE**

72676

**DATE**

2/3/26

**PRESENTING CLINICAL SIGNS**

Weight loss, hyporexia. Sudden behavior changes at home

Meds: Gaba/Traz/ Domitor for scan

Abnormal PE/Chem/CBC/UA Results: Borderline anemia 39 %, USG 1.050, all else wnl

**ULTRASONOGRAPHIC EXAMINATION OF THE ABDOMEN**

**Urinary System**

The urinary bladder is adequately distended with anechoic contents. No masses, inflammatory changes, echogenic sediment or cystoliths are observed. The urinary bladder, trigone and visible pelvic urethra are normal in thickness with a smooth mucosal surface.

Prostate is normal in size, echotexture and echogenicity for a neutered male.

The right kidney is normal is size (7.98 cm), shape and echogenicity. It has smooth peripheral margination. There is a normal 1:3 cortex to medulla ratio with appropriate corticomedullary distinction. There is no evidence of pyelectasia, mineral or infarcts observed.

The left kidney is normal is size (7.43 cm), shape and echogenicity. It has smooth peripheral margination. There is a normal 1:3 cortex to medulla ratio with appropriate corticomedullary distinction. There is no evidence of pyelectasia, mineral or infarcts observed.

**Adrenal Glands**

The right adrenal gland is normal in size (1.0 cm at cranial pole and 0.57 cm at caudal pole), shape and overall architecture, echogenicity and echotexture. Visible surrounding vasculature appears normal.

The left adrenal gland is normal in size (0.76 cm at cranial pole and 0.66 cm at caudal pole), shape and overall architecture, echogenicity and echotexture. Visible surrounding vasculature appears normal.

**Spleen**

Spleen is subjectively large in size (2.7 cm thick at the hilus) with normal smooth margins. Parenchyma is normal in echogenicity with a diffusely coarse/heterogenous echotexture. No discrete sizable focal nodules or masses are observed. Splenic vasculature appears normal.

**Liver**

The liver is subjectively normal in size with normal smooth curvilinear peripheral contour. Parenchyma is appropriately hypoechoic to the spleen in echogenicity and appropriately mildly coarse and homogenous in echotexture. No focal lesions are observed. Visible vasculature and biliary tree appear normal without distension or congestion.

The gallbladder is non-distended in size. The wall is smooth without visible thickening. Luminal contents are primarily anechoic. There is no evidence of cystic or common bile duct dilation.

**Gastrointestinal**

The visible stomach wall is normal in thickness and layering. The lumen of the stomach is empty with no evidence of obstruction, foreign material or infiltrative disease. Pyloric outflow tract appears patent.



**PATIENT**

Bennie Sandt

The visible small intestines are normal in wall thickness and layering. Small intestinal motility appears adequate (1-3 contractions per min). The lumen of the small intestine is empty with no evidence of obstruction, foreign material or infiltrative disease.

**SPECIES**

Canine

The visible colon is normal in wall thickness (< 0.2 cm) and layering. Contents are consistent with normal formed feces and gas.

**BREED**

St. Bernard

***Pancreas***

The pancreas that is observed appears appropriately isoechoic to surrounding omental fat. Visible capsule is smooth and normal in contour. Visible pancreatic parenchyma is homogenous and unremarkable. There is no visible pancreatic duct dilation. There is no evidence of active peripancreatic inflammation.

**SEX**

Neutered Male

***Free Abdomen***

There is no visible free peritoneal effusion noted in these images.

**AGE**

7 Years

There is no apparent pathologic lymphadenopathy noted in these images.

**WEIGHT**

153 lbs

The visible heart base (RA) and pericardium are unremarkable without obvious pathology noted in these images at this time. If cardiac function evaluation is desired, a full echocardiogram is recommended.

**ULTRASONOGRAPHIC FINDINGS**

- Coarse splenomegaly – can be associated with congestion caused by sedation (if sedated) but can also be associated with diffuse infiltrative disease. Both benign conditions such as extramedullary hematopoiesis, lymphoid hyperplasia, as well as infiltrative neoplastic diseases such as round cell neoplasia should be considered.

**INTERPRETED BY**

Beth Johnson, DVM  
DACVIM

**INTERPRETATION OF THE FINDINGS & FURTHER RECOMMENDATIONS**

**IMAGING PERFORMED BY**

Rebecca Hamilton

The patient's clinical history is non-specific behavior change, hyporexia, etc. with a wide list of differentials. Therefore, a pathologic process involving the spleen may or may not be present and/or related. Fine needle aspirates of the spleen could be considered if patient's coagulation status is appropriate. Otherwise, further workup recommendations could include examination outside the abdomen for potential sources of pain, concurrent cardiac or pulmonary disease, neurologic disease, etc. Part of this workup could include:

**HOSPITAL NAME**

Nazareth Veterinary  
Center

Three view thoracic radiographs are recommended for further assessment of cardio-pulmonary status as well as to further evaluate for any evidence of metastatic disease, if not recently evaluated.

**REFERRING VET**

Dr. Bankowski

A gastrointestinal malabsorption panel (including cobalamin, folate, TLI and PLI) to Texas A&M GI Laboratory is recommended for further evaluation of GI and pancreatic function.

**INVOICE**

72676

A baseline cortisol is recommended. If baseline cortisol is less than 2, a full ACTH stimulation test is recommended to rule out hypoadrenocorticism.

**DATE**

2/3/26



**PATIENT**

Bennie Sandt

**SPECIES**

Canine

**BREED**

St. Bernard

**SEX**

Neutered Male

**AGE**

7 Years

**WEIGHT**

153 lbs

**INTERPRETED BY**

Beth Johnson, DVM  
 DACVIM

**IMAGING PERFORMED BY**

Rebecca Hamilton

**HOSPITAL NAME**

Nazareth Veterinary  
 Center

**REFERRING VET**

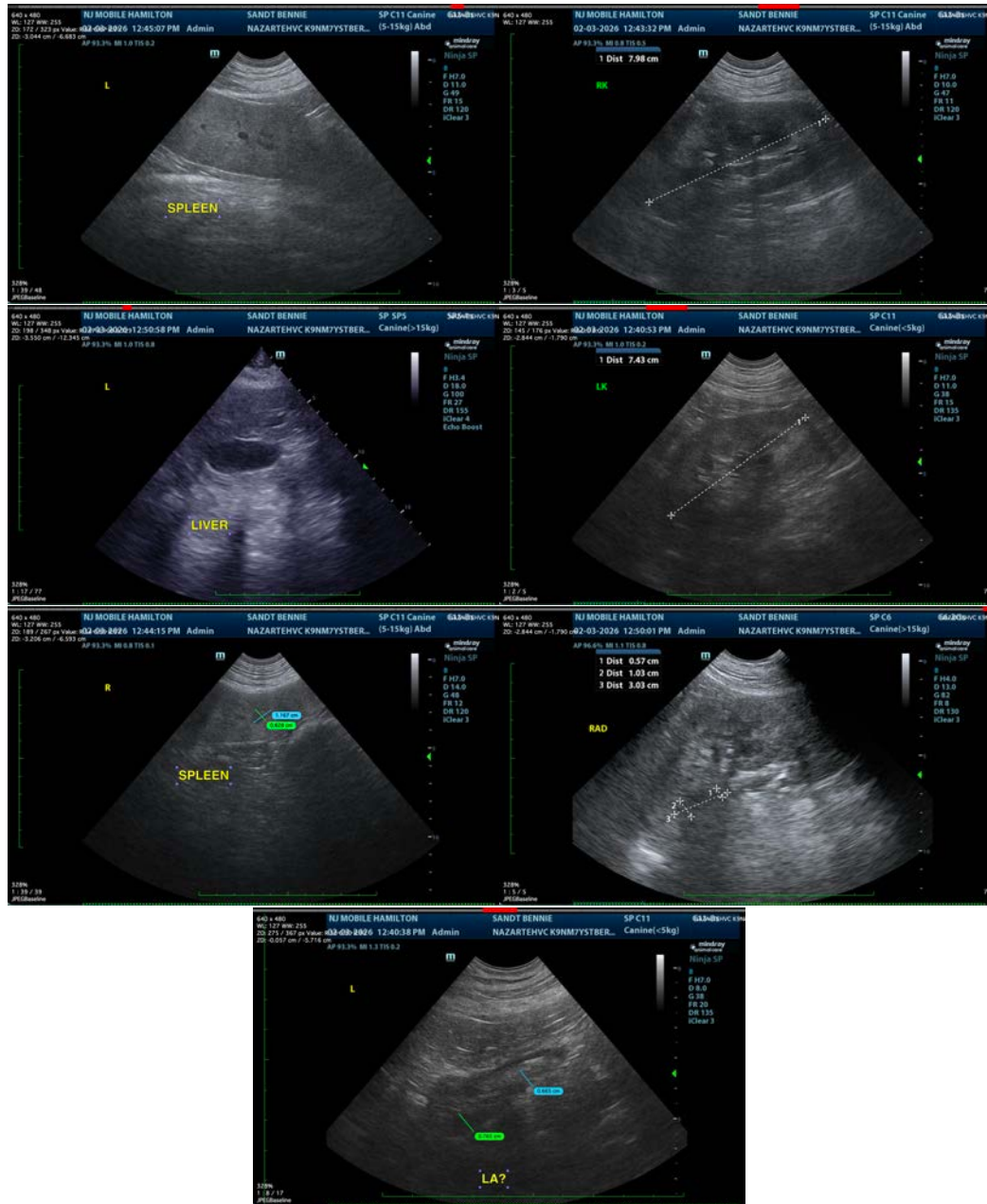
Dr. Bankowski

**INVOICE**

72676

**DATE**

2/3/26



The information and recommendations provided are based on the images presented by the referring veterinarian/sonographer. No evaluation can be communicated regarding pathology that was not visible in the image/video clips provided.

Thank you for this referral. If the clinical or image interpretation does not parallel your findings or if I can be of any further assistance please contact me.

**Beth Johnson, DVM, DACVIM**  
 info@sonopath.com