



<b>PATIENT</b>	<b>PRESENTING CLINICAL SIGNS</b>
Denver Pasheek	Lethargy, anemia, possible mass cranial abdomen.
<b>SPECIES</b>	<b>ULTRASONOGRAPHIC EXAMINATION OF THE ABDOMEN</b>
Canine	<b>Urinary System</b>
<b>BREED</b>	Urinary bladder is adequately distended with primarily anechoic contents and occasional echogenic non-shadowing debris. Apical urinary bladder wall is diffusely thick (0.84 cm). Mucosa is hyperechoic and irregular. No masses or cystoliths are observed. The trigone and visible pelvic urethra are normal thickness with a smooth mucosal surface.
Lab X	
<b>SEX</b>	Prostate is normal in size, echotexture and echogenicity for a neutered male.
Neutered Male	The right kidney is normal in size (8.34 cm), shape and echogenicity. It has smooth peripheral margination. There is a normal 1:3 cortex to medulla ratio with appropriate corticomedullary distinction. There is no evidence of pyelectasia, mineral or infarcts observed.
<b>AGE</b>	
8 Years	The left kidney is normal in size (8.23 cm), shape and echogenicity. It has smooth peripheral margination. There is a normal 1:3 cortex to medulla ratio with appropriate corticomedullary distinction. There is no evidence of pyelectasia, mineral or infarcts observed.
<b>WEIGHT</b>	<b>Adrenal Glands</b>
100 Pounds	The right adrenal gland is normal in size (2.55 cm long x 1.92 cm at the cranial pole and 1.16 cm at the caudal pole), shape and contour. Corticomedullary structure is unremarkable. Visible surrounding vasculature appears normal.
<b>INTERPRETED BY</b>	The left adrenal gland is normal in size (3.33 cm long x 0.67 cm at the cranial pole and 0.70 cm at the caudal pole), shape and contour. Corticomedullary structure is unremarkable. Visible surrounding vasculature appears normal.
Beth Johnson, DVM DACVIM	<b>Spleen</b>
<b>IMAGING PERFORMED BY</b>	The spleen is subjectively normal in size with a normal smooth capsular contour. Parenchyma is appropriately finely textured and homogenous with normal echogenicity relative to surrounding tissue (hyperechoic to liver). No focal nodules or masses are observed. Splenic vasculature appears normal.
Kelly Reschny	<b>Liver</b>
<b>HOSPITAL NAME</b>	The liver is subjectively normal in size with normal smooth curvilinear peripheral contour. Parenchyma is appropriately hypoechoic to the spleen in echogenicity and appropriately mildly coarse and homogenous in echotexture. In the deep mid liver, there is an approximately 4.0 cm x 5.0 cm heterogeneous, partially cavitated mass. Visible vasculature and biliary tree appear normal without distension or congestion.
AH of Stoney Creek	
<b>REFERRING VET</b>	<b>INVOICE</b>
Dr. Ozimok	44728
<b>INVOICE</b>	<b>DATE</b>
	2/3/23
	<b>Gastrointestinal</b>
	The visible stomach wall is normal in thickness and layering. The lumen of the stomach is mildly distended with very echogenic reverberation artifact from intraluminal gas. There is no evidence of obstruction, foreign material or infiltrative disease; however, complete visualization of far wall is partially inhibited by gas. Pyloric outflow tract appears patent.



**PATIENT**

Denver Pasheek

The visible small intestines are normal in wall thickness and layering (canine duodenum < 0.5 cm and feline duodenum < 0.4 cm; other < 0.3 cm). Small intestinal motility appears adequate (1-3 contractions per min). The lumen of the small intestine is empty with no evidence of obstruction, foreign material or infiltrative disease.

**SPECIES**

Canine

The visible colon is normal in wall thickness (< 0.2 cm) and layering. Contents are consistent with normal formed feces and gas.

**BREED**

***Pancreas***

Lab X

The pancreatic parenchyma is appropriately isoechoic to surrounding tissue. Visible capsule is smooth and normal in contour. There is no visible pancreatic duct dilation. There is no evidence of active peripancreatic inflammation.

**SEX**

Neutered Male

***Free Abdomen***

**AGE**

8 Years

There is a large amount of echogenic appearing free fluid.

There is no apparent lymphadenopathy noted in these images.

**WEIGHT**

100 Pounds

**PRIMARY FINDINGS**

- **Heterogeneous cavitated liver mass** – Concerning for infiltrative neoplasia such as sarcoma versus other. A benign hematoma is possible but considered much less likely, especially given the concurrent free fluid, which is presumably blood but should be confirmed with sampling.

**INTERPRETED BY**

Beth Johnson, DVM  
DACVIM

**ULTRASONOGRAPHIC FINDINGS**

- **Chronic Cystitis** - Urinary bladder wall changes are most consistent with chronic cystitis. Infiltrative neoplasia cannot be ruled out but is considered less likely give the location and diffuse nature of the changes.

**IMAGING PERFORMED BY**

Kelly Reschny

**INTERPRETATION OF THE FINDINGS & FURTHER RECOMMENDATIONS**

Sampling of the free abdominal fluid is recommended to help diagnose hemoabdomen versus other.

**HOSPITAL NAME**

AH of Stoney Creek

Three view thoracic radiographs are recommended for further assessment of cardio-pulmonary status as well as to further evaluate for any evidence of metastatic disease, if not recently evaluated.

A fine needle aspirate of the liver mass could be considered if patient's coagulation status is appropriate. However, if the mass has resulted in a hemoabdomen, alternatively an exploratory laparotomy for planned liver lobectomy/mass excision should be considered. The liver mass appears deep but focal with normal appearing parenchyma surrounding it, making full excision likely possible. However, full resectability of course cannot be guaranteed, and a pre-surgical planning abdominal CT scan could be considered.

**REFERRING VET**

Dr. Ozimok

**INVOICE**

44728

**DATE**

2/3/23



**PATIENT**

Denver Pasheek

**SPECIES**

Canine

**BREED**

Lab X

**SEX**

Neutered Male

**AGE**

8 Years

**WEIGHT**

100 Pounds

**INTERPRETED BY**

Beth Johnson, DVM  
DACVIM

**IMAGING PERFORMED BY**

Kelly Reschny

**HOSPITAL NAME**

AH of Stoney Creek

**REFERRING VET**

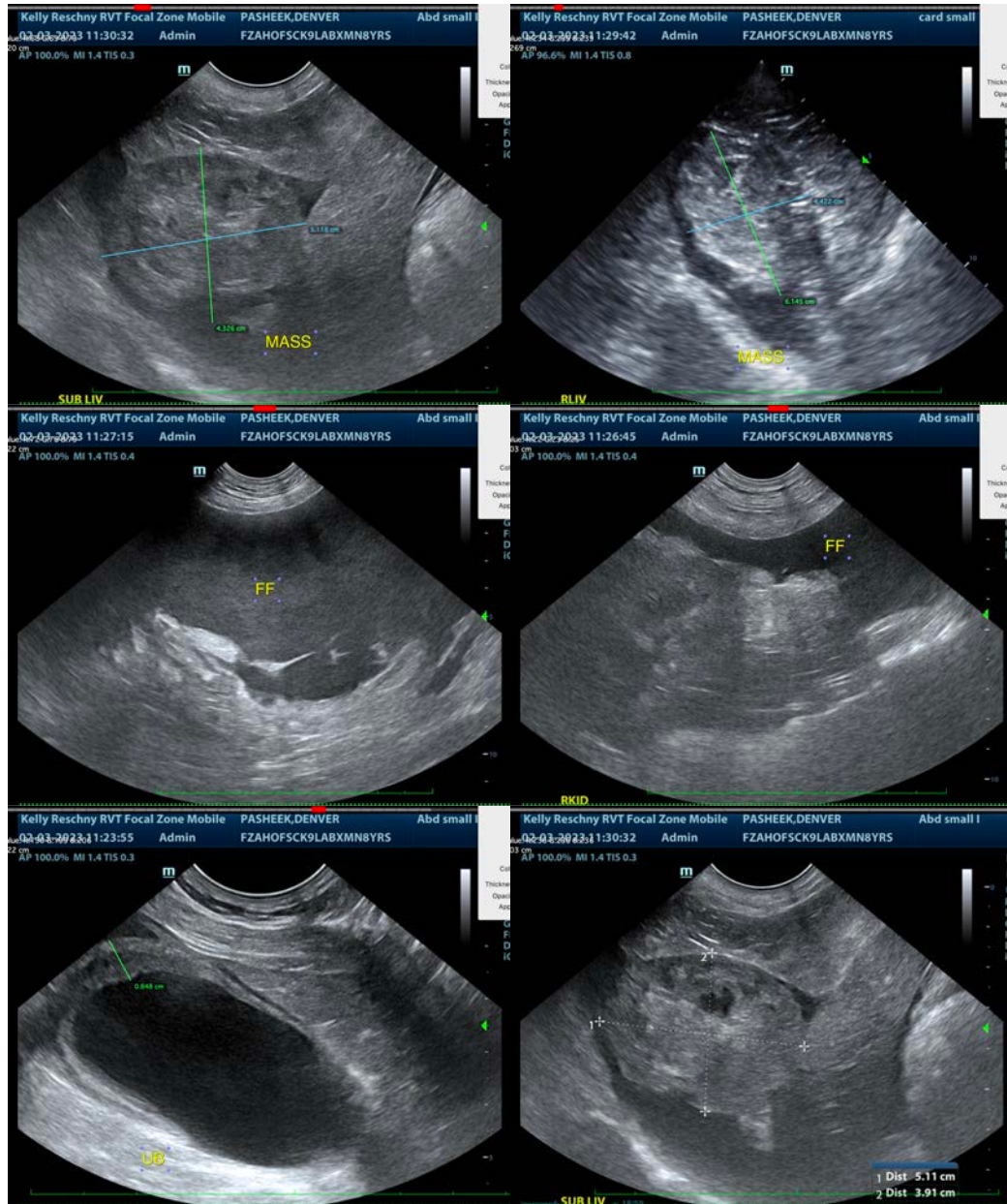
Dr. Ozimok

**INVOICE**

44728

**DATE**

2/3/23





**PATIENT**

Denver Pasheek

**SPECIES**

Canine

**BREED**

Lab X

**SEX**

Neutered Male

**AGE**

8 Years

**WEIGHT**

100 Pounds

**INTERPRETED BY**

Beth Johnson, DVM  
DACVIM

**IMAGING PERFORMED BY**

Kelly Reschny

**HOSPITAL NAME**

AH of Stoney Creek

**REFERRING VET**

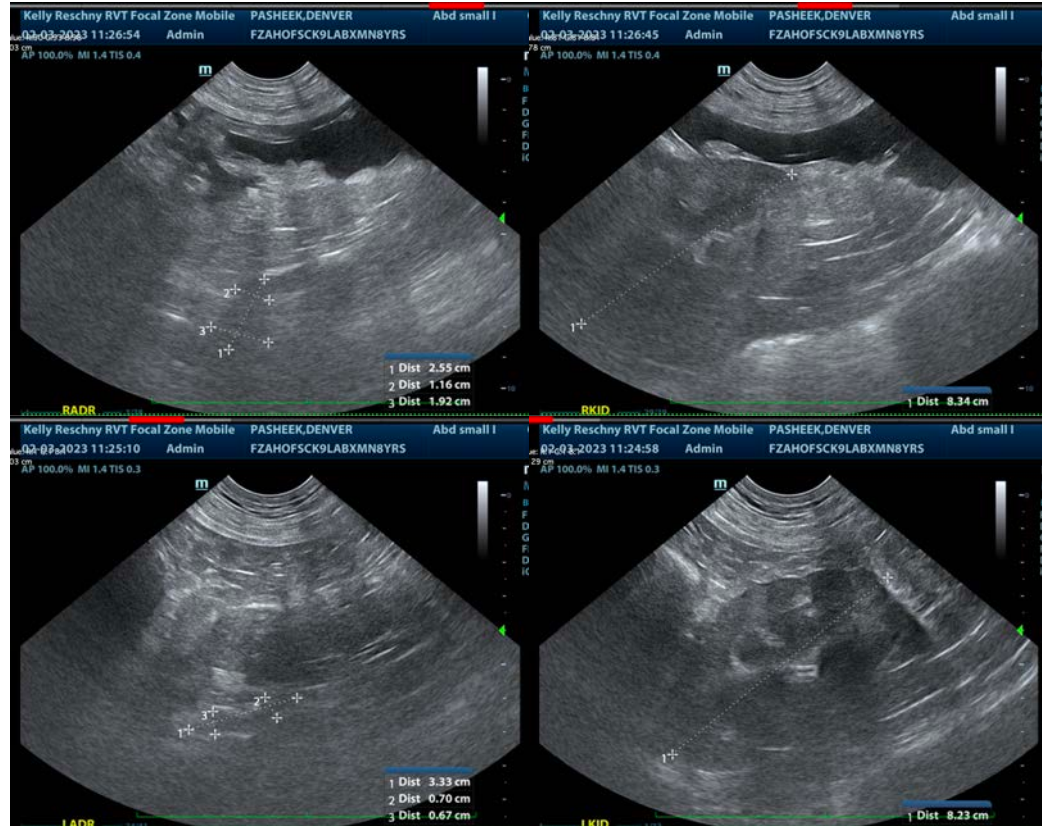
Dr. Ozimok

**INVOICE**

44728

**DATE**

2/3/23



The information and recommendations provided are based on the images presented by the referring veterinarian/sonographer. No evaluation can be communicated regarding pathology that was not visible in the image/video clips provided.

Thank you for this referral. If the clinical or image interpretation does not parallel your findings or if I can be of any further assistance please contact me.

**Beth Johnson, DVM, DACVIM**  
Beth.Johnson@sonopath.com