



PATIENT	PRESENTING CLINICAL SIGNS
Fritz Benton	weight loss ~1lb over the last several months. Bloodwork performed and hypoalbuminemia noted. No clinical symptoms at home (no diarrhea, inappetence) and no proteinuria. History of cystotomy to remove calcium oxalate stones in July 2021. Ultrasound to further explore cause for hypoalbuminemia.
SPECIES	
Canine	ULTRASONOGRAPHIC EXAMINATION OF THE ABDOMEN
BREED	Urinary System
Yorkie	Urinary bladder is moderately distended with anechoic contents combined with both gravity dependent and suspended echogenic, non-shadowing debris within the fluid. Along the dependent wall there is a solitary, broad based opacity and measures 0.7 cm across and extends for 0.77 cm into the lumen of the bladder. The opacity is heterogenous in echotexture and hyperechoic in echogenicity. It has normal uniform wall thickness (< 0.2 cm). No masses or cystoliths are observed.
SEX	
Neutered male	The prostate is normal for a neutered dog.
AGE	
14 years	Left kidney is normal in size (3.38 cm), shape with smooth peripheral margination. A normal 1:3 cortex to medulla ratio is maintained. The medulla and cortices are uniform in texture with some mild increased echogenicity and mild loss of corticomedullary distinction. Renal pelvis is dilated (pyelectasia), measuring (0.34 cm). No visible obstruction is observed, but cannot be ruled out. Non-obstructive areas of mineralization/nephroliths are noted, primarily in the diverticular of the kidney. There is no evidence of infarcts observed.
WEIGHT	
4.7 lbs	Right kidney is normal in size (3.87 cm), shape with smooth peripheral margination. A normal 1:3 cortex to medulla ratio is maintained. The medulla and cortices are uniform in texture with some mild increased echogenicity and mild loss of corticomedullary distinction. Renal pelvis is dilated (pyelectasia), measuring (0.3 cm). No visible obstruction is observed, but cannot be ruled out. Non-obstructive areas of mineralization/nephroliths are noted, primarily in the diverticular of the kidney. There is no evidence of infarcts observed.
INTERPRETED BY	
Beth Johnson, DVM DACVIM	
IMAGING PERFORMED BY	Adrenal Glands
Dr. Harris	Left adrenal gland is normal in size (0.48 cm at caudal pole), shape and contour. The cranial pole could not be measured, but the area was examined without evidence of pathology. Corticomedullary structure is unremarkable.
HOSPITAL NAME	
TotalBon VH	Right adrenal gland is normal in size (0.43 cm at cranial pole), shape and contour. The cranial pole could not be measured, but the area was examined without evidence of pathology. Corticomedullary structure is unremarkable.
REFERRING VET	Spleen
Dr. Harris	Spleen is subjectively normal in size with normal smooth margins. Parenchyma is normal in echogenicity and echotexture. No focal nodules or masses are observed. Splenic vasculature appears normal.
INVOICE	
95809	
DATE	
2/3/22	



PATIENT	Liver
Fritz Benton	Liver is subjectively normal in size. Margins are sharp and smooth. It has normal homogenous echotexture and normal echogenicity. No focal lesions are observed. Visible vasculature appears normal. GB is moderately distended with anechoic bile and gravity dependent echogenic sediment. The wall is smooth without visible thickening. There is no evidence of cystic or CBD dilation. There is no evidence of effusion or inflammation.
SPECIES	
Canine	
BREED	Gastrointestinal
Yorkie	The visible gastric wall is normal in thickness (canine < 0.5 cm and feline < 0.4 cm). The lumen of the stomach is mildly distended with echogenic non-shadowing luminal contents and gas consistent with normal ingesta. There is no evidence of obstruction, foreign material or infiltrative disease. Pyloric outflow tract appears patent.
SEX	
Neutered male	The small intestines are normal in wall thickness and layering. Small intestinal motility appears adequate (1-3 contractions per min). The small intestinal lumen is mildly distended with echogenic non-shadowing luminal contents and gas consistent with normal ingesta. Occasionally there is some hyperechoic speckling in the mucosa. There is no evidence of obstruction, foreign material or infiltrative disease.
AGE	
14 years	Colon is normal in wall thickness (< 0.2 cm) and layering.
WEIGHT	
4.7 lbs	Pancreas
	Pancreas has normal homogenous echotexture and is normal in echogenicity and smooth margination. There is no evidence of peripancreatic inflammation.
INTERPRETED BY	
Beth Johnson, DVM DACVIM	Free Abdomen
	Lymph nodes are normal with no observed enlargement.
IMAGING PERFORMED BY	
Dr. Harris	ULTRASONOGRAPHIC FINDINGS
HOSPITAL NAME	Primary Findings
TotalBon VH	Mild occasional hyperechoic speckling in the small bowel mucosa. This is a finding that can be seen with dogs with inflammatory bowel disease, but is not specific to the type of inflammatory disease.
REFERRING VET	Opacity in urinary bladder of undifferentiated origin. Differentials being inflammatory debris/mucous/crystals/ etc. versus a bladder mass. Differentials for a mass include infiltrative neoplasia.
Dr. Harris	Age related kidney change – This finding is expected/consistent with age-related mild degenerative disease and should be interpreted clinically in combination with laboratory changes. Pyelectasia – Differentials for pyelectasia include pyelonephritis, diuresis, congenital malformation or ureteral or lower urinary tract obstruction. Non-obstructive nephrolithiasis.
INVOICE	Canine Gallbladder debris – Cholecystic debris is of unknown clinical significance. It can be seen with biliary stasis from fasting or illness. Cholecystic debris is not necessarily related to hepatobiliary disease. Echogenic bile is most commonly an incidental finding in dogs and should be interpreted in
95809	
DATE	
2/3/22	



PATIENT

combination with clinical signs such as nausea, inappetence, cranial abdominal discomfort and/or laboratory changes such as increased ALP and/or increased Tbili.

Fritz Benton

SPECIES

INTERPRETATION OF THE FINDINGS & FURTHER RECOMMENDATIONS

Canine

Recommendations to further assess the patient's urinary bladder opacity include color flow Doppler over the area to help determine tissue versus debris. Other recommendations include a urine culture if not already performed. If the opacity appears to be tissue based on color flow submission of urine to look for BRAF gene mutation, which is associated with urinary bladder cancer should be submitted. Given the presence of bacteria on urinalysis and lack of urinary signs management of a presumed urinary tract infection and recheck of the urinary bladder is a reasonable management approach.

BREED

Yorkie

SEX

Neutered male

Given the weight loss, hypoalbuminemia and mild bowel speckling combined with patients breed there is a concern for protein losing enteropathy +/- lymphangectasia. Therefore, I recommend gastrointestinal malabsorption panel including TLI, PLI, folate and cobalamin to Texas A&M GI laboratory. Empirical therapies can include a transition to a low fat diet +/- steroid administration or biopsies of the bowel can be obtained for a definitive diagnosis.

AGE

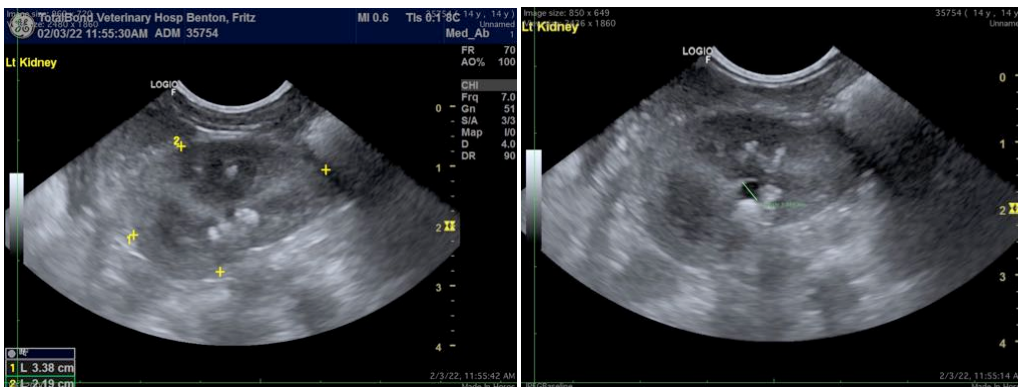
14 years

WEIGHT

4.7 lbs

INTERPRETED BY

Beth Johnson, DVM
DACVIM

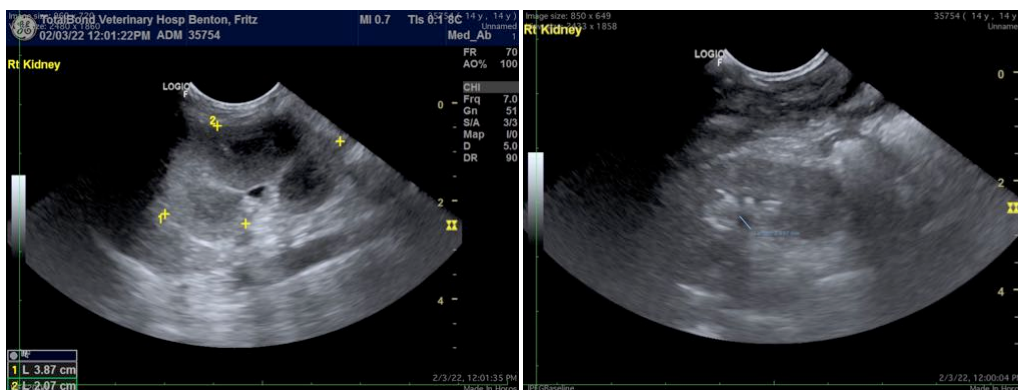


IMAGING PERFORMED BY

Dr. Harris

HOSPITAL NAME

TotalBon VH



REFERRING VET

Dr. Harris

INVOICE

95809

DATE

2/3/22



PATIENT

Fritz Benton

SPECIES

Canine

BREED

Yorkie

SEX

Neutered male

AGE

14 years

WEIGHT

4.7 lbs

INTERPRETED BY

Beth Johnson, DVM
DACVIM

IMAGING PERFORMED BY

Dr. Harris

HOSPITAL NAME

TotalBon VH

REFERRING VET

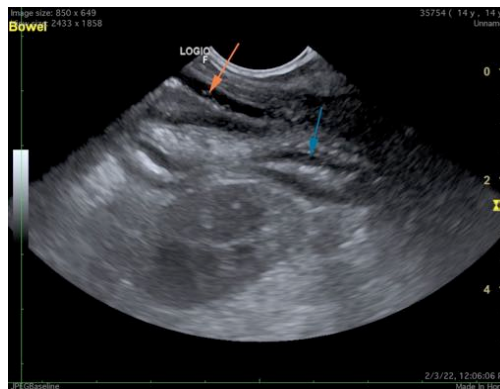
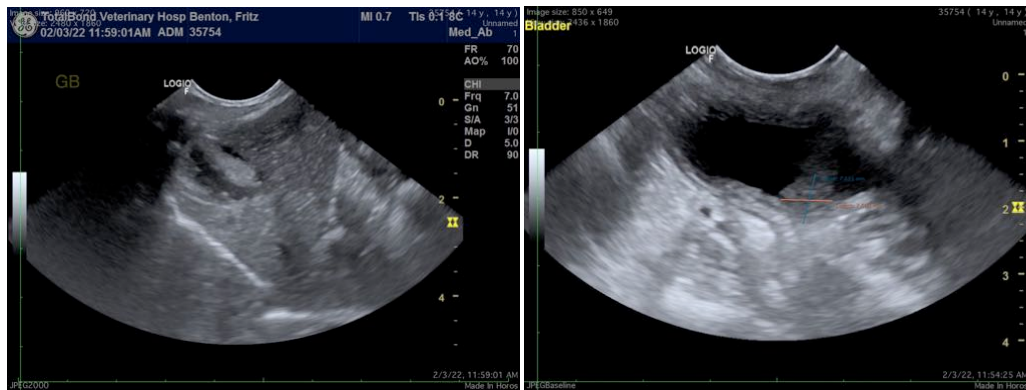
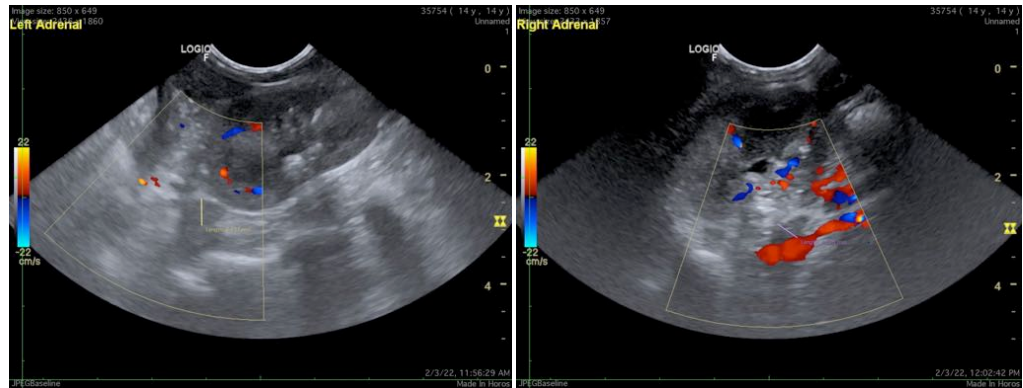
Dr. Harris

INVOICE

95809

DATE

2/3/22



The information and recommendations provided are based on the images presented by the referring veterinarian/sonographer. No evaluation can be communicated regarding pathology that was not visible in the image/video clips provided.

Thank you for this referral. If the clinical or image interpretation does not parallel your findings or if I can be of any further assistance please contact me.

Beth Johnson, DVM DACVIM

Beth.Johnson@SonoPath.com



PATIENT

Fritz Benton

SPECIES

Canine

BREED

Yorkie

SEX

Neutered male

AGE

14 years

WEIGHT

4.7 lbs

INTERPRETED BY

Beth Johnson, DVM
DACVIM

**IMAGING
PERFORMED BY**

Dr. Harris

HOSPITAL NAME

TotalBon VH

REFERRING VET

Dr. Harris

INVOICE

95809

DATE

2/3/22