

**DATE PRESENTING CLINICAL SIGNS**

2/2823 Recent hx of vomiting, hyporexia and lethargy- resolved but AFAST suspect for GI thickening/mass. PE unremarkable.

PATIENT

Nicky Nizzardini

Current Medications: Prednisolone 5mg SID x 7 days (started 2/22) then tapering to 2.5mg SID.

Lab Results: Mostly unremarkable. Mild lymphopenia 0.82 (>0.92).

Date of Previous IntraPet Ultrasound: No previous.

Sedation: Patient sedated with Dexdomitor.

SPECIES

Feline

Stat Report: Not requested.

Imaging Performed By: Andi Parkinson, BS, RDMS.

BREED

DSH

Urinary System

Urinary bladder is adequately distended. It has a normal uniform wall thickness. Contents include primarily anechoic fluid with occasional echogenic non-shadowing debris, most consistent with incidental suspended lipid in a cat, possibly combined with exfoliated cells, mucous and/or small blood clots. Both sterile inflammation as well as urinary tract infection can also present with echogenic debris. No masses or cystoliths are observed. The trigone and visible pelvic urethra are normal in thickness with a smooth mucosal surface.

SEX

Neutered Male

AGE

6/24/13

The right kidney is normal in size (3.61 cm), shape and echogenicity. It has smooth peripheral margination. There is a normal 1:3 cortex to medulla ratio with appropriate corticomedullary distinction. There is no evidence of pyelectasia or infarcts observed. Small non-obstructive nephroliths noted.

WEIGHT

8.7 Pounds

The left kidney is normal in size (3.39 cm), shape and echogenicity. It has smooth peripheral margination. There is a normal 1:3 cortex to medulla ratio with appropriate corticomedullary distinction. There is no evidence of pyelectasia or infarcts observed. Small non-obstructive nephroliths noted.

INTERPRETED BYBeth Johnson, DVM
DACVIM**Adrenal Glands**

The right adrenal gland is normal in size (0.36 cm), shape and contour. Corticomedullary structure is unremarkable. Visible surrounding vasculature appears normal.

HOSPITAL NAME

Timonium AH

The left adrenal gland is normal in size (0.41 cm), shape and contour. Corticomedullary structure is unremarkable. Visible surrounding vasculature appears normal.

REFERRING VET

Dr. Montessi

Spleen

The spleen is subjectively normal in size with a normal smooth capsular contour. Parenchyma is appropriately finely textured and homogenous with normal echogenicity relative to surrounding tissue (hyperechoic to liver). No focal nodules or masses are observed. Splenic vasculature appears normal.

INVOICE

45586

Liver

The liver is subjectively normal in size with normal smooth curvilinear peripheral contour. Parenchyma is appropriately hypoechoic to the spleen in echogenicity and appropriately mildly coarse and homogenous in echotexture. No focal lesions are observed. Visible vasculature and biliary tree appear normal without distension or congestion.

The gallbladder is non-distended in size. The wall is smooth without visible thickening. Luminal contents are primarily anechoic. There is no evidence of cystic or common bile duct dilation.

Gastrointestinal

The stomach wall is normal in thickness (canine < 0.5 cm and feline < 0.4 cm) and layering. The lumen of the stomach is empty with no evidence of obstruction, foreign material or infiltrative disease. Pyloric outflow tract appears patent.

The visible small intestine demonstrates areas of thick muscularis layer relative to mucosa (disruption of the normal 1:3 muscularis:mucosa ratio). Small intestinal submucosa is slightly irregular, thick and hyperechoic, without evident loss of layering appreciated. The lumen is empty with no evidence of obstruction or foreign material.

The visible colon is normal in wall thickness (< 0.2 cm) and layering. Contents are consistent with normal formed feces and gas.

Pancreas

Pancreas is prominent (enlarged) in size, hypoechoic to surrounding tissue and has a mildly irregular undulating contour. Parenchyma is coarse with mixed echogenic remodeling noted. Pancreatic duct dilation is noted.

Free Abdomen

There is no evidence of free peritoneal effusion noted in these images.

The mesenteric lymph nodes are prominent in size with swollen capsular contour. Normal elongated shape (length to width ratio) is maintained. There is no loss of parenchymal detail.

PRIMARY FINDINGS

- **Inflammatory bowel disease (IBD) pattern** – Thick muscularis has been reported with infiltrative bowel disease including both benign inflammatory disease as well as infiltrative neoplasia such as lymphoma. No aggressive lymphadenopathy, loss of layering, etc. is noted to make lymphoma more probable, but lymphoma cannot be definitively ruled out without tissue sampling.
- Chronic active pancreatitis
- **Reactive mesenteric lymph nodes** – infiltrative neoplastic disease cannot be ruled out but is considered less likely.

SECONDARY FINDINGS

- Urinary bladder debris
- Non-obstructive nephroliths bilaterally

INTERPRETATION OF THE FINDINGS & FURTHER RECOMMENDATIONS

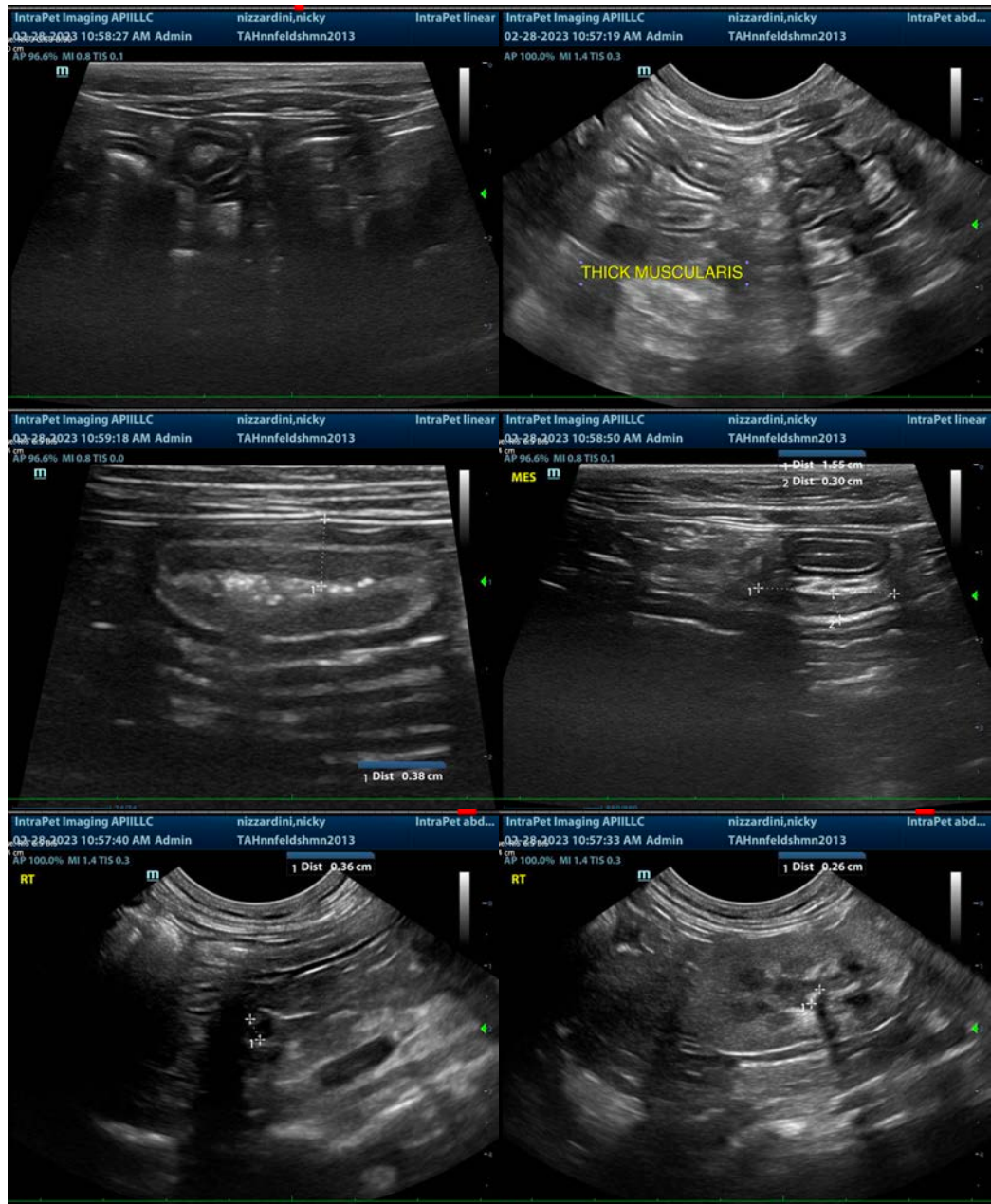
A gastrointestinal malabsorption panel (including cobalamin, folate, TLI and PLI) to Texas A&M GI Laboratory is recommended for further evaluation of GI and pancreatic function.

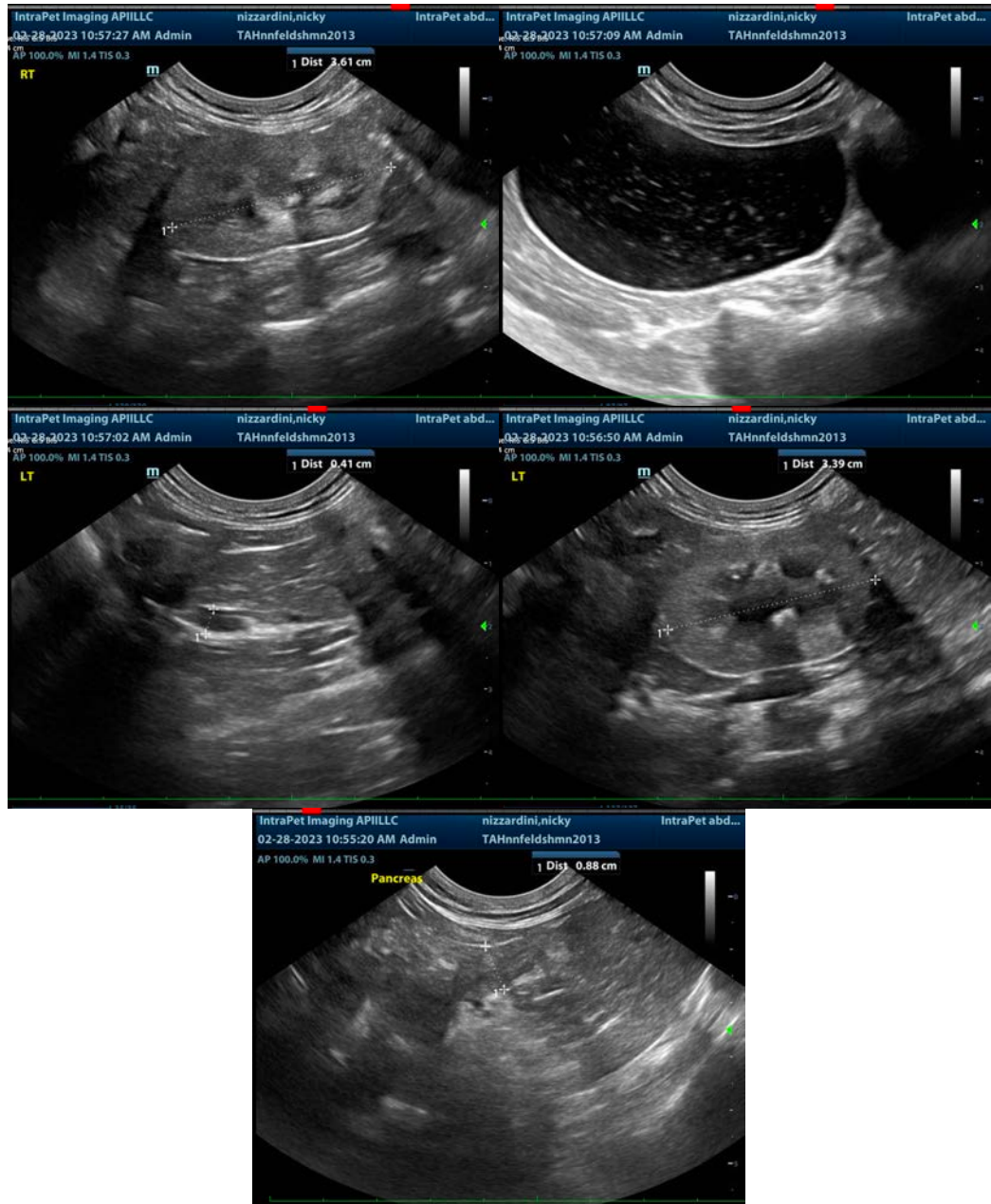
Ideally, biopsies of the GI tract, being sure to include ileum if possible, are recommended to definitively diagnose and therefore manage the infiltrative bowel disease.

If biopsies cannot be obtained, empirical therapies could include diet change, empirical deworming with a 5 day course of Panacur, cobalamin supplementation (unless cobalamin level is evaluated and supplementation is not warranted) and prednisolone (if not contraindicated based on patient contraindications, co-

morbidities, etc.). Other supportive therapeutic considerations could include fiber supplementation, especially with large bowel diarrhea and/or a probiotic.

Additionally, if not recently evaluated, a urinalysis and, if indicated based on urinalysis results, urine culture are recommended. If protein is present in an otherwise quiet sediment, protein quantification with a urine protein to creatinine ration is recommended.





The information and recommendations provided are based on the images presented by the referring veterinarian/sonographer. No evaluation can be communicated regarding pathology that was not visible in the image/video clips provided.

Thank you for this referral. If the clinical or image interpretation does not parallel your findings or if I can be of any further assistance please contact me.

Beth Johnson, DVM, DACVIM
Beth.Johnson@sonopath.com