

IMAGING PERFORMED BY

SVS Mobile Imaging MI 734-637-7711
svsimagingmi@gmail.com



EDUCATIONAL TELECONSULTATION SERVICES™
1-800-838-4268 info@sonopath.com SonoPath.com

PATIENT

Boone Bergh

SPECIES

Canine

BREED

Lab

SEX

Neutered Male

AGE

13 Years

WEIGHT

70 Pounds

INTERPRETED BYBeth Johnson, DVM
DACVIM**IMAGING PERFORMED BY**

Amy Mayhew, LVT

HOSPITAL NAME

SVS Imaging MI

REFERRING VET

Dr. Angela Lusty

INVOICE

45588

DATE

2/28/23

PRESENTING CLINICAL SIGNS

Vomited Thursday and Friday of last week. Saturday and Sunday improved. Was eating and drinking with no vomiting. Yesterday presented for vomiting, lethargy, and decreased appetite. Current medications include gabapentin and alprazolam.

Abnormal PE/Chem/CBC/UA Results: Depressed. Rough harsh lung sounds. Seemed uncomfortable in abdomen. Peripheral LNs enlarged. Rads showed generalized gas in large and small intestine. Stomach distended with abnormal positioning with mix of gas and soft tissue opacity. Owners declined BW.

ULTRASONOGRAPHIC EXAMINATION OF THE ABDOMEN**Urinary System**

Urinary bladder is adequately distended with primarily anechoic contents and occasional echogenic non-shadowing debris. Apical urinary bladder wall is diffusely thick (0.39 cm). Mucosa is hyperechoic and irregular. No masses or cystoliths are observed. The trigone and visible pelvic urethra are normal thickness with a smooth mucosal surface.

Prostate is normal in size, echotexture and echogenicity for a neutered male.

The right kidney is normal in size (7.57 cm), shape and echogenicity. It has smooth peripheral margination. There is a normal 1:3 cortex to medulla ratio with appropriate corticomedullary distinction. There is no evidence of pyelectasia, mineral or infarcts observed.

The left kidney is normal in size (7.46 cm), shape and echogenicity. It has smooth peripheral margination. There is a normal 1:3 cortex to medulla ratio with appropriate corticomedullary distinction. There is no evidence of pyelectasia, mineral or infarcts observed.

Adrenal Glands

The right adrenal gland is normal in size (0.51 cm at the caudal pole and 0.65 cm at the cranial pole), shape and contour. Corticomedullary structure is unremarkable. Visible surrounding vasculature appears normal.

The left adrenal gland is normal in size (0.71 cm at the cranial pole and 0.70 cm at the caudal pole), shape and contour. Corticomedullary structure is unremarkable. Visible surrounding vasculature appears normal.

Spleen

The spleen is generally normal in size and shape with a normal smooth capsular contour. Parenchyma is diffusely nodular in appearance characterized by small discrete hypoechoic nodules. Splenic vasculature appears normal.

Liver

The liver is subjectively normal in size with normal smooth curvilinear peripheral contour. Parenchyma is appropriately hypoechoic to the spleen in echogenicity and appropriately mildly coarse and homogenous in echotexture. No focal lesions are observed. Visible vasculature and biliary tree appear normal without distension or congestion.

The gallbladder is subjectively mildly to moderately over distended in size with anechoic bile as well as suspended and gravity dependent echogenic debris. The wall is mildly thick measuring 0.37 cm, and mildly irregular and hyperechoic. There is no evidence of cystic or common bile duct dilation. There is enhanced hyperechoic mesenteric fat surrounding the gallbladder within the fossa.

IMAGING PERFORMED BY

SVS Mobile Imaging MI 734-637-7711
svsimagingmi@gmail.com

**PATIENT**

Boone Bergh

SPECIES

Canine

BREED

Lab

SEX

Neutered Male

AGE

13 Years

WEIGHT

70 Pounds

INTERPRETED BY

Beth Johnson, DVM
DACVIM

IMAGING PERFORMED BY

Amy Mayhew, LVT

HOSPITAL NAME

SVS Imaging MI

REFERRING VET

Dr. Angela Lusty

INVOICE

45588

DATE

2/28/23

Gastrointestinal

The visible stomach wall is normal in thickness and layering. The lumen of the stomach is mildly distended with very echogenic reverberation artifact from intraluminal gas. There is no evidence of obstruction, foreign material or infiltrative disease; however, complete visualization of far wall is partially inhibited by gas. Pyloric outflow tract appears patent.

The visible small intestines are normal in wall thickness and layering (canine duodenum < 0.5 cm and feline duodenum < 0.4 cm; other < 0.3 cm). Small intestinal motility appears adequate (1-3 contractions per min). The lumen of the small intestine is mildly distended with very echogenic reverberation artifact from intraluminal gas. There is no evidence of obstruction, foreign material or infiltrative disease.

The visible colon is normal in wall thickness (< 0.2 cm) and layering. Contents are consistent with normal formed feces and gas.

Pancreas

The pancreatic parenchyma is appropriately isoechoic to surrounding tissue. Visible capsule is smooth and normal in contour. There is no visible pancreatic duct dilation. There is no evidence of active peripancreatic inflammation.

Free Abdomen

There is no evidence of free peritoneal effusion noted in these images.

There is no apparent lymphadenopathy noted in these images.

ULTRASONOGRAPHIC FINDINGS

- **Nodular spleen** – This finding is concerning for infiltrative neoplasia such as round cell neoplasia. Benign disease, however, including extramedullary hematopoiesis, micronodular hyperplasia, etc. can mimic round cell neoplasia and cannot be ruled out without tissue sampling.
- **Gallbladder debris** - Cholecystic debris is of unknown clinical significance. It can be seen with biliary stasis from fasting or illness. However, given the wall changes and inflammatory changes surrounding the pancreas, cholangitis or potentially chronic cholangitis with an acute flare up, etc. is suspected. This finding should be interpreted in combination with clinical signs such as nausea, inappetence, cranial abdominal discomfort and/or laboratory changes such as increased ALP and/or increased Tbili.
- **Chronic Cystitis** - Urinary bladder wall changes are most consistent with chronic cystitis. Infiltrative neoplasia cannot be ruled out but is considered less likely give the location and diffuse nature of the changes.

INTERPRETATION OF THE FINDINGS & FURTHER RECOMMENDATIONS

Ultrasonographically, the gallbladder is the most significant change that could be likely contributing to this patient's reported vomiting, especially if concurrent cranial abdominal pain exists. However, given the reported peripheral lymphadenopathy as well as the splenic changes, other infiltrative disease (even neoplastic disease such as lymphoma) could be present as well.

Recommendations include further assessment of the hepatobiliary system, beginning with a general metabolic health screen including CBC/Chem panel, electrolytes, a urinalysis and, if indicated based on urinalysis results, urine culture. If protein is present in an otherwise quiet sediment, protein quantification with a urine protein to creatinine ration is recommended.

IMAGING PERFORMED BY

SVS Mobile Imaging MI 734-637-7711
svsimagingmi@gmail.com



EDUCATIONAL TELECONSULTATION SERVICES™
1-800-838-4268 info@sonopath.com SonoPath.com

PATIENT

Boone Bergh

SPECIES

Canine

BREED

Lab

SEX

Neutered Male

AGE

13 Years

WEIGHT

70 Pounds

INTERPRETED BY

Beth Johnson, DVM
DACVIM

IMAGING PERFORMED BY

Amy Mayhew, LVT

HOSPITAL NAME

SVS Imaging MI

REFERRING VET

Dr. Angela Lusty

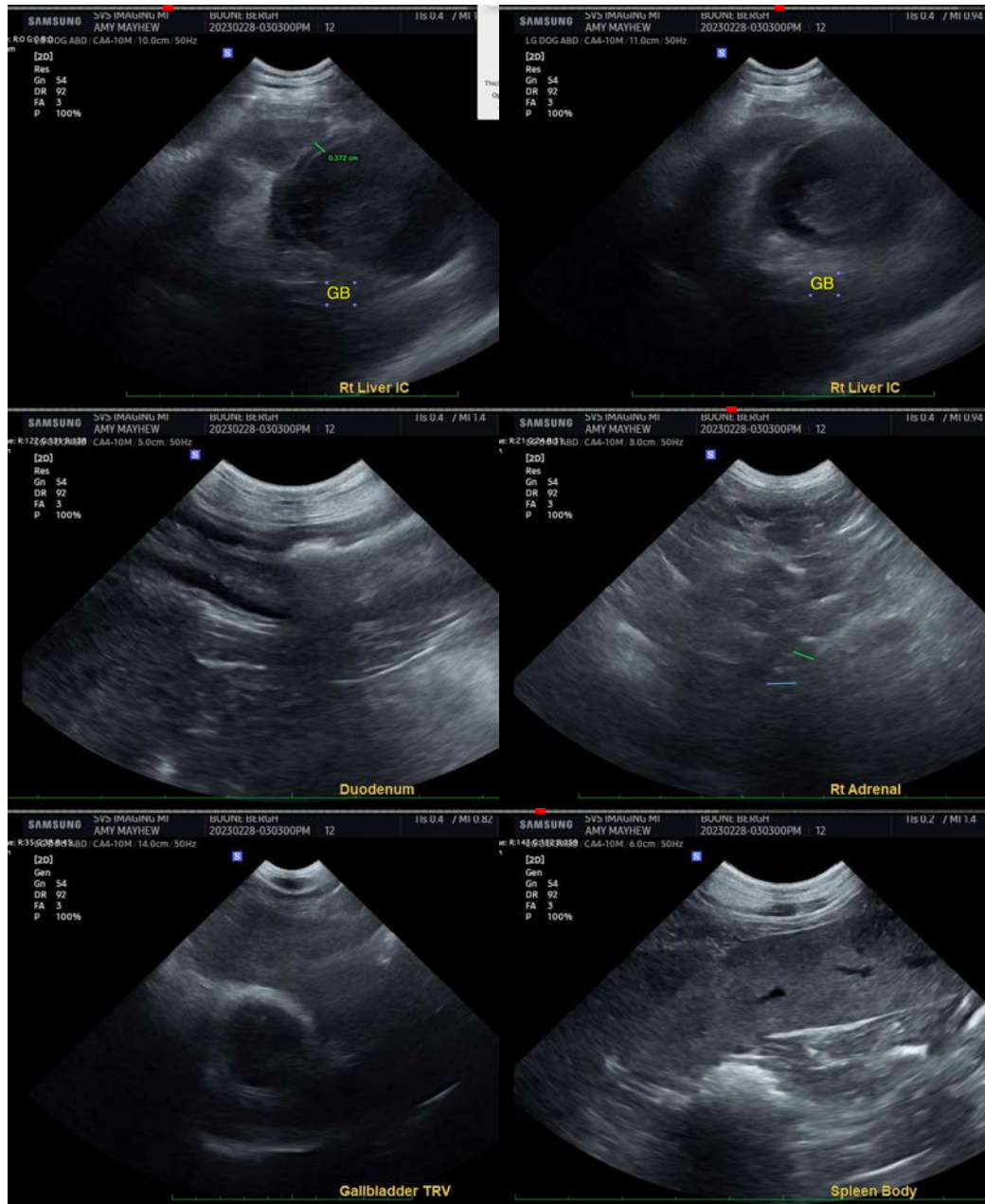
INVOICE

45588

DATE

2/28/23

Additionally, fine needle aspirates of the enlarged peripheral lymph nodes as well as the spleen could be considered if patient's coagulation status is appropriate. Specific management recommendations are dependent on those results. However, in the meantime, supportive/symptomatic therapy is recommended in the form of antiemetics, gastroprotectants, appetite stimulant if needed, fluid therapy if needed, etc.



IMAGING PERFORMED BY

SVS Mobile Imaging MI 734-637-7711
svsimagingmi@gmail.com



PATIENT

Boone Bergh

SPECIES

Canine

BREED

Lab

SEX

Neutered Male

AGE

13 Years

WEIGHT

70 Pounds

INTERPRETED BY

Beth Johnson, DVM
DACVIM

IMAGING PERFORMED BY

Amy Mayhew, LVT

HOSPITAL NAME

SVS Imaging MI

REFERRING VET

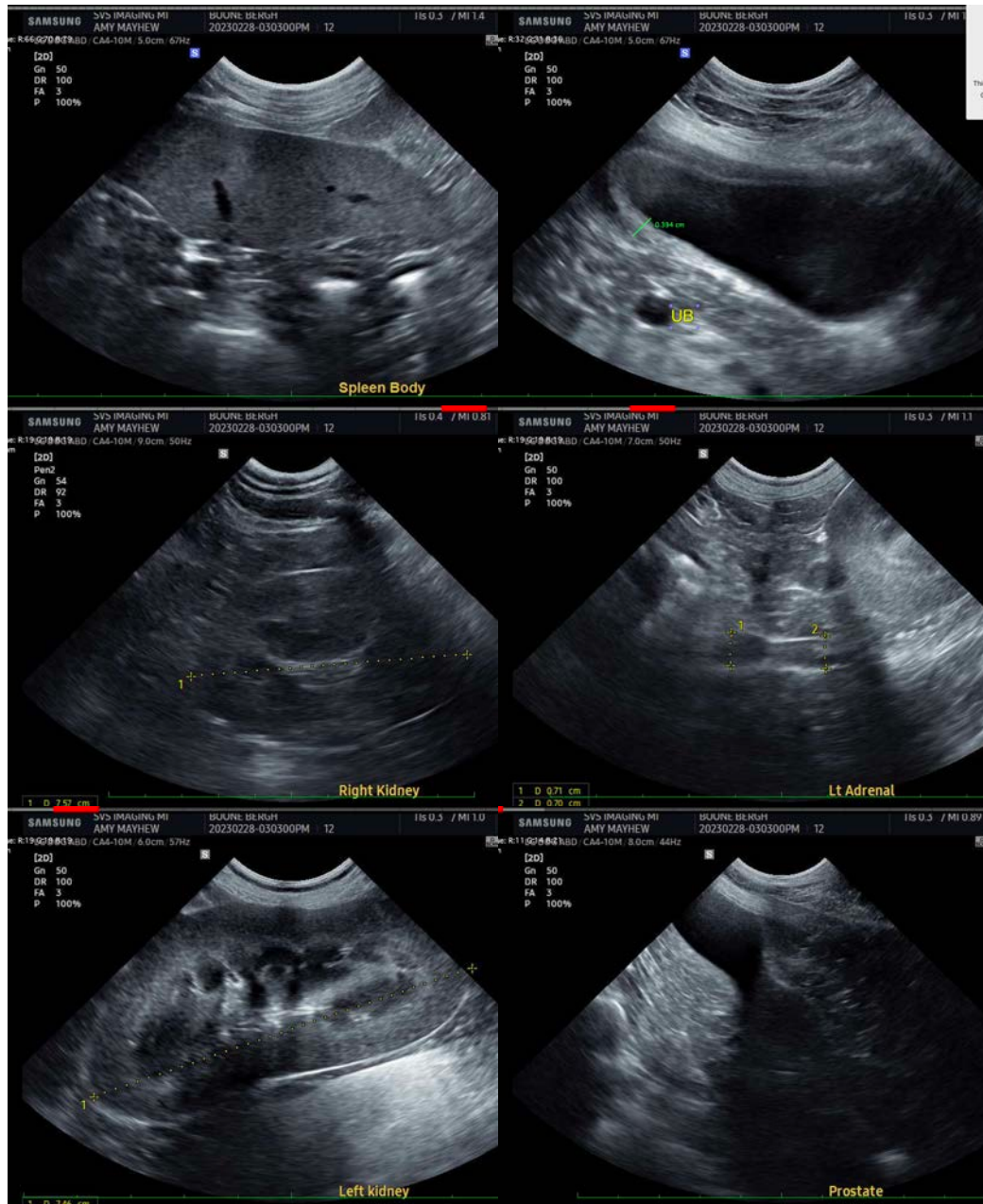
Dr. Angela Lusty

INVOICE

45588

DATE

2/28/23



The information and recommendations provided are based on the images presented by the referring veterinarian/sonographer. No evaluation can be communicated regarding pathology that was not visible in the image/video clips provided.

Thank you for this referral. If the clinical or image interpretation does not parallel your findings or if I can be of any further assistance please contact me.

Beth Johnson, DVM, DACVIM
Beth.Johnson@sonopath.com