

**DATE PRESENTING CLINICAL SIGNS**

2/28/23 Elevated ALT 540.

PATIENT

Bella Shimmel

Current Medications: None listed.
 Date of Previous IntraPet Ultrasound: No previous.
 Sedation: Not required to complete full diagnostic ultrasound.
 Stat Report: Not requested.
 Imaging Performed By: Stephanie Warga RDCS, RVT.

SPECIES

Feline

ULTRASONOGRAPHIC EXAMINATION OF THE ABDOMEN**BREED**

DSH

SEX

Spayed Female

AGE

1/15/16

WEIGHT

9.13 Pounds

INTERPRETED BYBeth Johnson, DVM
DACVIM**HOSPITAL NAME**

Banfield White Marsh

REFERRING VET

Dr. Racz

INVOICE

45581

Urinary System

Urinary bladder is adequately distended. It has a normal uniform wall thickness. Contents include primarily anechoic fluid with occasional echogenic non-shadowing debris, most consistent with incidental suspended lipid in a cat, possibly combined with exfoliated cells, mucous and/or small blood clots. Both sterile inflammation as well as urinary tract infection can also present with echogenic debris. No masses or cystoliths are observed. The trigone and visible pelvic urethra are normal in thickness with a smooth mucosal surface.

The right kidney is normal in size (3.5 cm), shape and echogenicity. It has smooth peripheral margination. There is a normal 1:3 cortex to medulla ratio with appropriate corticomedullary distinction. There is no evidence of pyelectasia, mineral or infarcts observed.

The left kidney is normal in size (3.58 cm), shape and echogenicity. It has smooth peripheral margination. There is a normal 1:3 cortex to medulla ratio with appropriate corticomedullary distinction. There is no evidence of pyelectasia, mineral or infarcts observed.

Adrenal Glands

The right adrenal gland is normal in size (0.28 cm), shape and contour. Corticomedullary structure is unremarkable. Visible surrounding vasculature appears normal.

The left adrenal gland is normal in size (0.41 cm), shape and contour. Corticomedullary structure is unremarkable. Visible surrounding vasculature appears normal.

Spleen

Spleen is subjectively large in size (1.0 cm thick at the hilus) with a mildly swollen but smooth capsule. Parenchyma is normal and homogenous in echogenicity and echotexture. No focal nodules or masses are observed. Splenic vasculature appears normal.

Liver

The liver is subjectively normal in size with normal smooth curvilinear peripheral contour. Parenchyma is appropriately hypoechoic to the spleen in echogenicity and appropriately mildly coarse and homogenous in echotexture. No focal lesions are observed. Visible vasculature and biliary tree appear normal without distension or congestion.

The gallbladder is non-distended in size. The wall is smooth without visible thickening. Luminal contents are primarily anechoic. The cystic and common bile duct are mildly tortuous in appearance but not pathologically distended. This is often a normal anatomic variant in a cat. Consequence of chronic or resolved or even ongoing cholangitis can't be ruled out, and this finding should be interpreted in combination with clinical signs and/or laboratory changes that support cholangitis.

Gastrointestinal

The visible stomach wall is normal in thickness and layering. The lumen of the stomach is mildly distended with echogenic non-shadowing luminal contents and gas consistent with normal ingesta. There is no evidence of obstruction, foreign material or infiltrative disease. Pyloric outflow tract appears patent.

The visible small intestines are normal in wall thickness and layering. Small intestinal motility appears adequate (1-3 contractions per min). The lumen of the small intestine is mildly distended with echogenic non-shadowing luminal contents and gas consistent with normal ingesta. There is no evidence of obstruction, foreign material or infiltrative disease.

The visible colon is normal in wall thickness (< 0.2 cm) and layering. Contents are consistent with normal formed feces and gas.

Pancreas

Pancreas is prominent (enlarged) in size, hypoechoic to surrounding tissue and has a mildly irregular undulating contour. Parenchyma is coarse with mixed echogenic remodeling noted. Pancreatic duct dilation is noted.

Free Abdomen

There is no evidence of free peritoneal effusion noted in these images.

The mesenteric lymph nodes are prominent in size with swollen capsular contour. Normal elongated shape (length to width ratio) is maintained. There is no loss of parenchymal detail.

PRIMARY FINDINGS

- **Hypersplenism** – can be associated with congestion caused by sedation (if sedated) but can also be associated with diffuse infiltrative disease. Both benign conditions such as extramedullary hematopoiesis, lymphoid hyperplasia, amyloidosis, as well as infiltrative neoplastic diseases such as round cell neoplasia should be considered.
- Chronic active pancreatitis
- **Reactive mesenteric lymph nodes** – infiltrative neoplastic disease cannot be ruled out but is considered less likely.
- Tortuous common bile duct as described above

SECONDARY FINDINGS

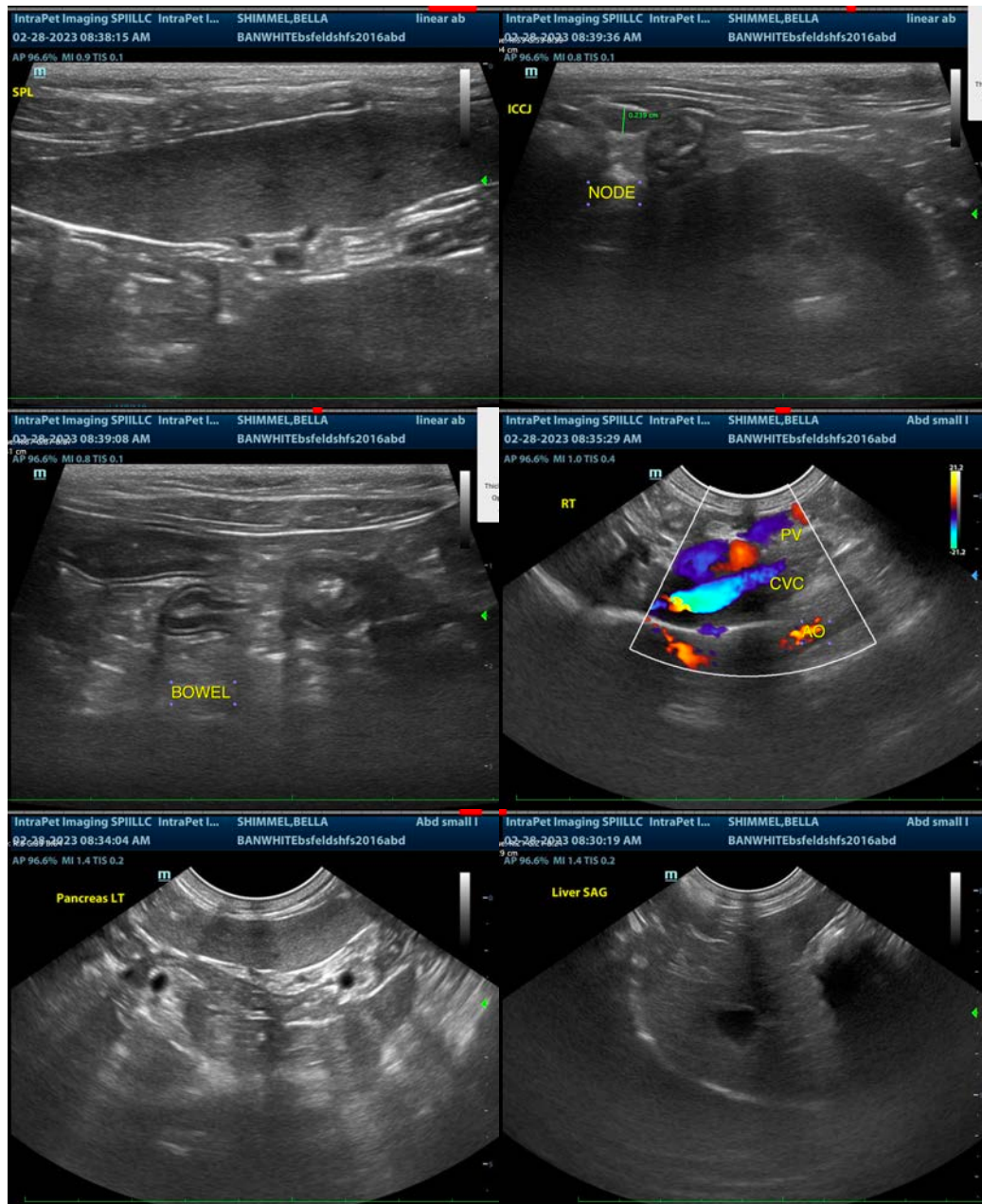
- Urinary bladder debris

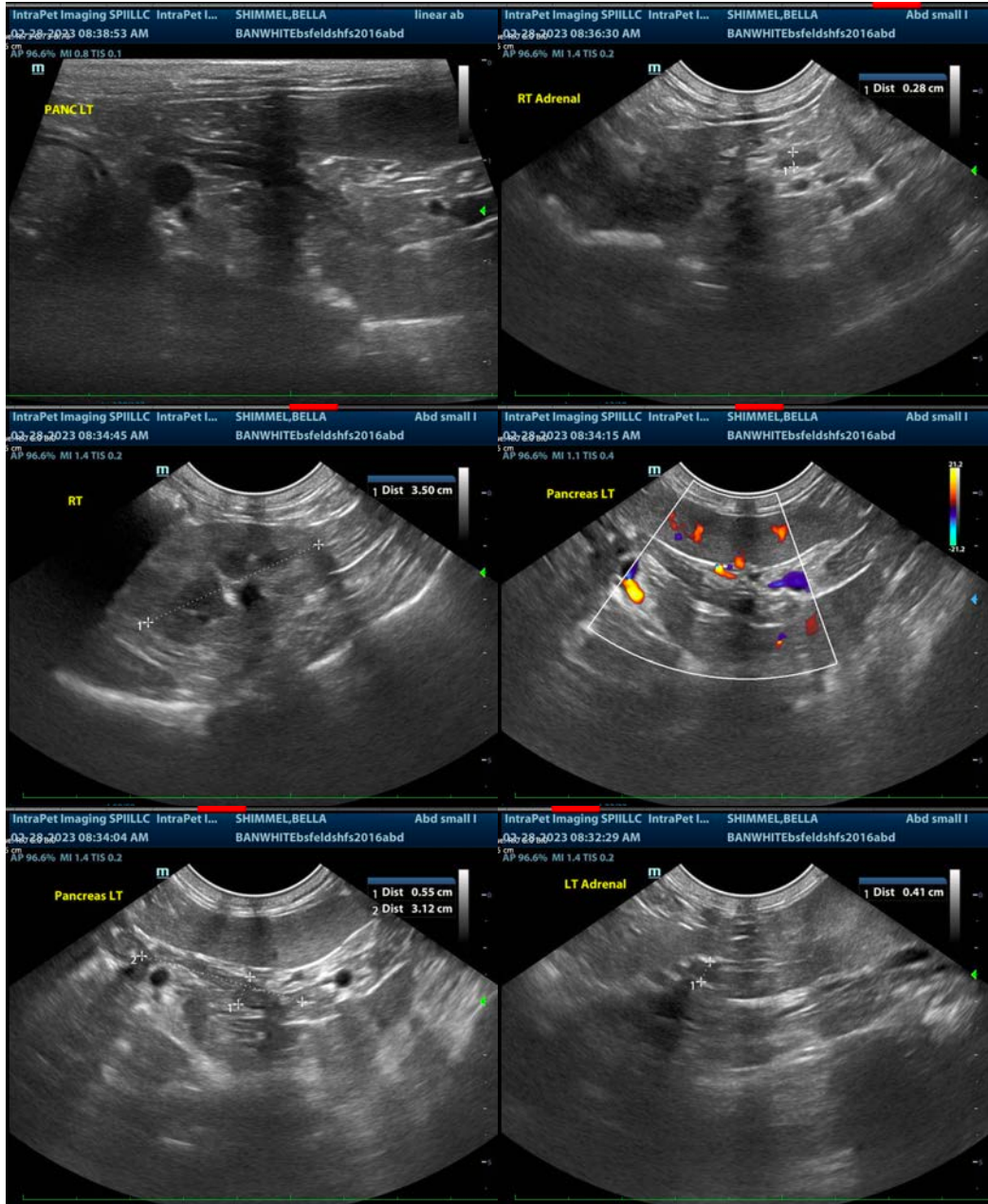
INTERPRETATION OF THE FINDINGS & FURTHER RECOMMENDATIONS

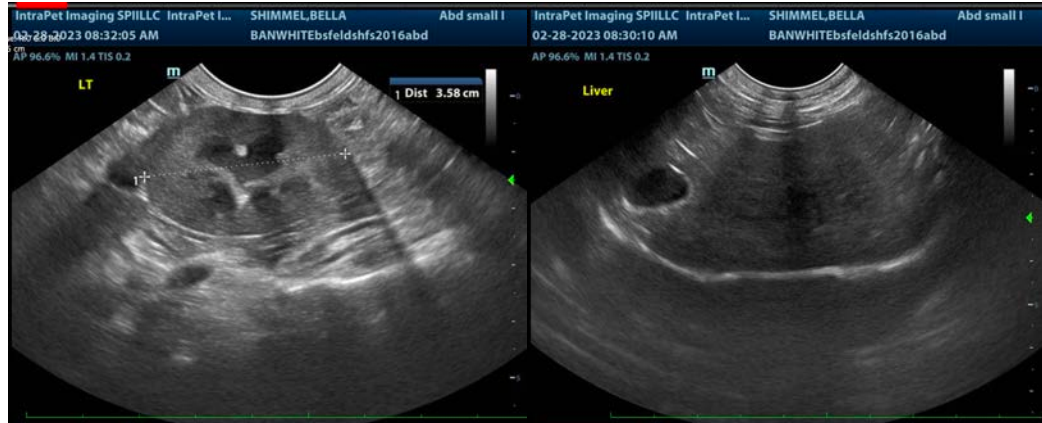
There is not an ultrasonographically visible explanation for this patient's reported increased ALT. Recommendations include comprehensive infectious disease testing including potentially toxoplasma. Additionally, fine needle aspirates of the liver and spleen are recommended if patient's coagulation status is appropriate.

If a diagnosis is not obtained cytologically, further evaluation of gastrointestinal and pancreatic health could be considered, beginning with a gastrointestinal malabsorption panel (including cobalamin, folate, TLI and PLI) to Texas A&M GI Laboratory in case smoldering or subclinical gastrointestinal disease is contributing to ascending cholangiohepatitis, etc.

In the meantime, treatment recommendations include fluid therapy, anti-emetics, gastroprotectants, hepatic nutraceuticals such as ursodiol and/or Denamarin, and broad spectrum antibiotics. Nutritional support is critical to prevent/manage concurrent hepatic lipidosis, so appetite stimulants and/or, if indicated, feeding tube placement is also recommended.







The information and recommendations provided are based on the images presented by the referring veterinarian/sonographer. No evaluation can be communicated regarding pathology that was not visible in the image/video clips provided.

Thank you for this referral. If the clinical or image interpretation does not parallel your findings or if I can be of any further assistance please contact me.

Beth Johnson, DVM, DACVIM
Beth.Johnson@sonopath.com