



## PATIENT

Jed Foltz

## SPECIES

Feline

## BREED

DSH

## SEX

Neutered Male

## AGE

9 Years 10 Months

## WEIGHT

3.6 kg

## INTERPRETED BY

Beth Johnson, DVM  
DACVIM

## IMAGING PERFORMED BY

Renee Trionfetti, VMD

## HOSPITAL NAME

Blue Pearl Wyomissing

## REFERRING VET

VCA Bridgeport AH

## INVOICE

73272

## DATE

2/25/26

## PRESENTING CLINICAL SIGNS

AUS to further evaluate chronic vomiting, weight loss, suspected discomfort after eating. Will eat a small amount and then stop. Acute vomiting on Friday 2/20/26- vomiting all day, unable to hold down food, palpable firm structure palpated in abdomen on exam at that time that is now not appreciated on recheck exam. Also has diarrhea. In the summer, will eat grass.

Meds: Prednisolone 5mg- 1/2 T PO Q12- started 2/23/26. Diet: Hydrolyzed, Hills Z/D - stated 2/23/26

O noted at time of AUS, stopped giving Omeprazole when started Prednisolone as he wasn't sure if he should also continue Omeprazole. O did note that did seems to eat better when he gave Omeprazole prior to eating.

Abnormal PE/Chem/CBC/UA Results: UA: USG 1.045, Pro 1+, inactive sediment - CBC/Chem: NSF, Hct 41%, Plts 258, Alb 3.2-n, Cr 1.7, SDMA 12.8, normal LES - T4: 2.6 -n - GI malabsorption panel: normal - AXR: no obstruction noted, mod amount of gas in SI/colon, no other findings, AIS report pending

## ULTRASONOGRAPHIC EXAMINATION OF THE ABDOMEN

### Urinary System

The urinary bladder is adequately distended with anechoic contents. No masses, inflammatory changes, echogenic sediment or cystoliths are observed. The urinary bladder, trigone and visible pelvic urethra are normal in thickness with a smooth mucosal surface.

The right kidney is normal is size (3.96 cm), shape and echogenicity. It has smooth peripheral margination. There is a normal 1:3 cortex to medulla ratio with appropriate corticomedullary distinction. There is no evidence of pyelectasia, mineral or infarcts observed.

The left kidney is normal is size (3.15 cm), shape and echogenicity. It has smooth peripheral margination. There is a normal 1:3 cortex to medulla ratio with appropriate corticomedullary distinction. There is no evidence of pyelectasia, mineral or infarcts observed.

### Adrenal Glands

The right adrenal gland is normal in size (0.32 cm at cranial pole and 0.34 cm at caudal pole), shape and overall architecture, echogenicity and echotexture. Visible surrounding vasculature appears normal.

The left adrenal gland is normal in size (0.35 cm at cranial pole and 0.34 cm at caudal pole), shape and overall architecture, echogenicity and echotexture. Visible surrounding vasculature appears normal.

### Spleen

The spleen is subjectively normal in size with a normal smooth capsular contour. Parenchyma is appropriately finely textured and homogenous with normal echogenicity relative to surrounding tissue (hyperechoic to liver). No focal nodules or masses are observed. Splenic vasculature appears normal.

### Liver

The liver is subjectively normal in size with normal smooth curvilinear peripheral contour. Parenchyma is appropriately hypoechoic to the spleen in echogenicity and appropriately mildly coarse and homogenous in echotexture. No focal lesions are observed. Visible vasculature and biliary tree appear normal without distension or congestion.



## PATIENT

Jed Foltz

## SPECIES

Feline

## BREED

DSH

## SEX

Neutered Male

## AGE

9 Years 10 Months

## WEIGHT

3.6 kg

## INTERPRETED BY

Beth Johnson, DVM  
DACVIM

## IMAGING PERFORMED BY

Renee Trionfetti, VMD

## HOSPITAL NAME

Blue Pearl Wyomissing

## REFERRING VET

VCA Bridgeport AH

## INVOICE

73272

## DATE

2/25/26

The gallbladder is non-distended in size. The wall is smooth without visible thickening. Luminal contents are primarily anechoic. There is no evidence of cystic or common bile duct dilation.

### **Gastrointestinal**

The visible stomach wall is normal in thickness and layering. The lumen is mildly distended with primarily fluid as well as some echogenic non-shadowing luminal contents and gas consistent with normal chyme. There is no evidence of obstruction, foreign material, or infiltrative disease. Pyloric outflow tract appears patent.

The visible small intestine demonstrates areas of markedly/significantly thick muscularis layer relative to mucosa (disruption of the normal 1:3 muscularis:mucosa ratio). Small intestinal submucosa is slightly irregular, thick and hyperechoic, without evident loss of layering appreciated. The lumen of the small intestine is empty with no evidence of obstruction or foreign material.

The visible colon is normal in wall thickness (< 0.2 cm) and layering. Contents are consistent with normal formed feces and gas.

### **Pancreas**

The pancreas that is observed appears appropriately isoechoic to surrounding omental fat. Visible capsule is smooth and normal in contour. Visible pancreatic parenchyma is homogenous and unremarkable. There is no visible pancreatic duct dilation. There is no evidence of active peripancreatic inflammation.

### **Free Abdomen**

There is no visible free peritoneal effusion noted in these images.

There is no apparent pathologic lymphadenopathy noted in these images.

## **ULTRASONOGRAPHIC FINDINGS**

- Marked/significant inflammatory bowel disease (IBD) pattern – Thick muscularis has been reported with infiltrative bowel disease including both benign inflammatory disease as well as infiltrative neoplasia such as lymphoma. No loss of layering or distinct characteristics of malignancy are present. Therefore, differentials cannot be further ranked without tissue sampling. *\*This change is diffuse but especially prominent in the ileum.*

## **INTERPRETATION OF THE FINDINGS & FURTHER RECOMMENDATIONS**

Recommendations include:

- As is reportedly already evaluated, a gastrointestinal malabsorption panel (including cobalamin, folate, TLI and PLI) to Texas A&M GI Laboratory is recommended for further evaluation of GI and pancreatic function.
- A fecal enteropathogen PCR panel to Texas A&M GI Laboratory could be considered for further evaluation of possible infectious disease. Contact lab for recommendations on how long to discontinue antibiotics (if indicated) prior to obtaining a stool sample for submission.
- Ideally, biopsies of the GI tract, being sure to include ileum if possible, are recommended to definitively diagnose and therefore manage the infiltrative bowel disease.



**PATIENT**

Jed Foltz

**SPECIES**

Feline

**BREED**

DSH

**SEX**

Neutered Male

**AGE**

9 Years 10 Months

**WEIGHT**

3.6 kg

**INTERPRETED BY**

Beth Johnson, DVM  
DACVIM

**IMAGING PERFORMED BY**

Renee Trionfetti, VMD

**HOSPITAL NAME**

Blue Pearl Wyomissing

**REFERRING VET**

VCA Bridgeport AH

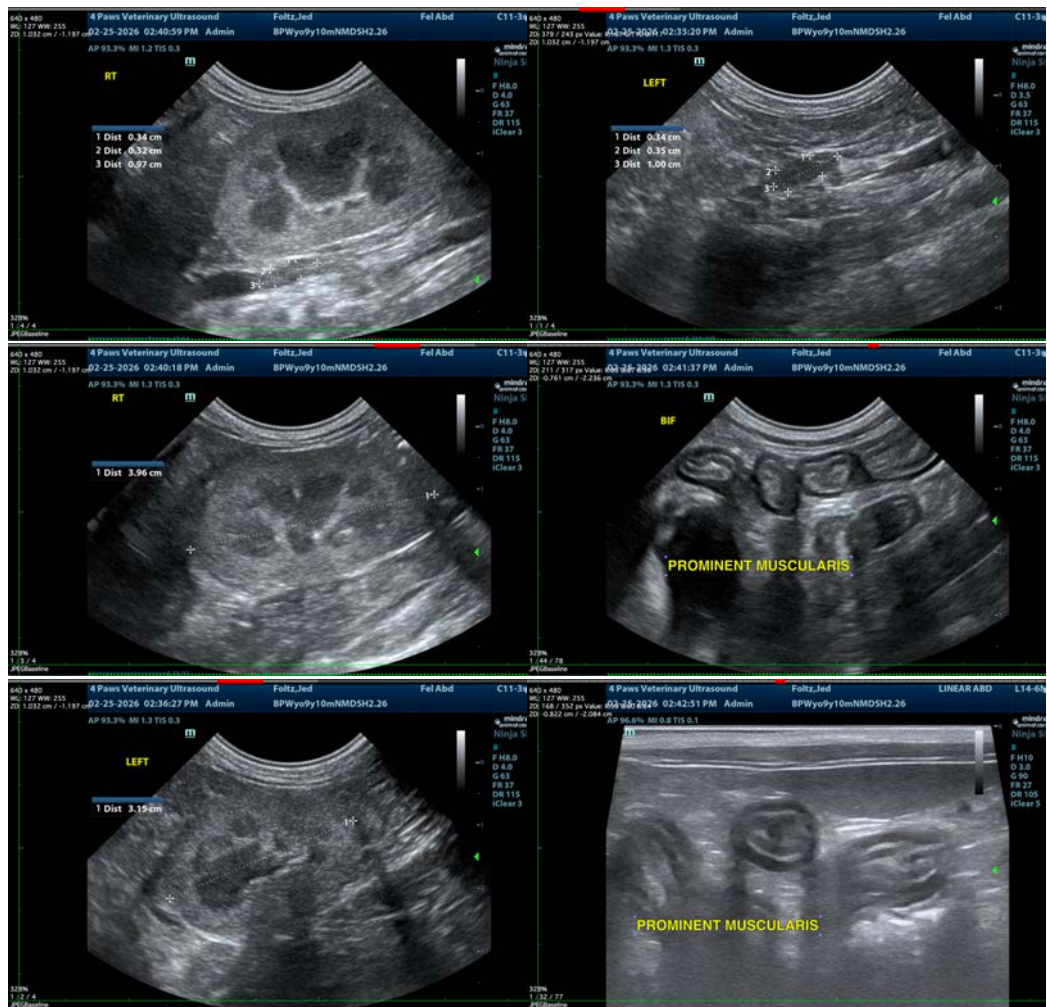
**INVOICE**

73272

**DATE**

2/25/26

- If biopsies cannot be obtained, empirical therapies could include a probiotic (if diarrhea is present, such as visbiome or proviable), empirical deworming with a 5-day course of Panacur and, if tolerated, a transition in diet, based on trial-and-error response, beginning with a hydrolyzed protein diet. Some patients respond to one brand/version of a hydrolyzed protein diet better than another brand, so several trials may be required.
- Additional considerations could include cobalamin supplementation (unless cobalamin level is evaluated and supplementation is not warranted) and prednisolone (if not contraindicated based on patient contraindications, co-morbidities, etc.).





## PATIENT

Jed Foltz

## SPECIES

Feline

## BREED

DSH

## SEX

Neutered Male

## AGE

9 Years 10 Months

## WEIGHT

3.6 kg

## INTERPRETED BY

Beth Johnson, DVM  
DACVIM

## IMAGING PERFORMED BY

Renee Trionfetti, VMD

## HOSPITAL NAME

Blue Pearl Wyomissing

## REFERRING VET

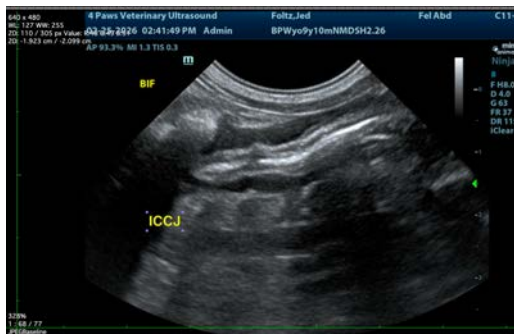VCA Bridgeport AH

## INVOICE

73272

## DATE

2/25/26



The information and recommendations provided are based on the images presented by the referring veterinarian/sonographer. No evaluation can be communicated regarding pathology that was not visible in the image/video clips provided.

Thank you for this referral. If the clinical or image interpretation does not parallel your findings or if I can be of any further assistance please contact me.

**Beth Johnson, DVM, DACVIM**  
info@sonopath.com