

**PATIENT**

Apollo Cruz

**SPECIES**

Canine

**BREED**

Labrador Retriever

**SEX**

Castrated Male

**AGE**

9 Years 5 Months

**WEIGHT**

57.7

**INTERPRETED BY**Beth Johnson, DVM  
DACVIM**IMAGING  
PERFORMED BY**

Dr. Christensen

**HOSPITAL NAME**Tranquility Veterinary  
Clinic**REFERRING VET**

Dr. Christensen

**INVOICE**

73279

**DATE**

2/25/26

**PRESENTING CLINICAL SIGNS**

Presented for COHAT. Abnormal PE/Chem/CBC/UA Results: BNP= 7309.1, BP= 104/47, MAP= 59. Mild increase in Creatinine= 1.6. UA pending.

**ULTRASONOGRAPHIC EXAMINATION OF THE ABDOMEN****Urinary System**

The urinary bladder is adequately distended with anechoic contents. No masses, inflammatory changes, echogenic sediment or cystoliths are observed. The urinary bladder, trigone and visible pelvic urethra are normal in thickness with a smooth mucosal surface.

The area of the prostate is examined without evident prostatic pathology.

The right kidney is normal in size (6.33 cm), shape and echogenicity. It has smooth peripheral margination. There is a normal 1:3 cortex to medulla ratio with appropriate corticomedullary distinction. There is no evidence of pyelectasia, mineral or infarcts observed. A very subtle hyperechoic band parallel to the corticomedullary border is present.

The left kidney is normal in size (6.05 cm), shape and echogenicity. It has smooth peripheral margination. There is a normal 1:3 cortex to medulla ratio with appropriate corticomedullary distinction. There is no evidence of pyelectasia, mineral or infarcts observed. A very subtle hyperechoic band parallel to the corticomedullary border is present.

**Adrenal Glands**

The right adrenal gland is normal in size (0.64 cm at cranial pole and 0.68 cm at caudal pole), shape and overall architecture, echogenicity and echotexture. Visible surrounding vasculature appears normal.

The left adrenal gland is normal in size (0.47 cm at cranial pole and 0.61 cm at caudal pole), shape and overall architecture, echogenicity and echotexture. Visible surrounding vasculature appears normal.

**Spleen**

The spleen is subjectively normal in size with a normal smooth capsular contour. Parenchyma is appropriately finely textured and homogenous with normal echogenicity relative to surrounding tissue (hyperechoic to liver). No focal nodules or masses are observed. Splenic vasculature appears normal.

**Liver**

The liver is subjectively normal in size with normal smooth curvilinear peripheral contour. Parenchyma is appropriately hypoechoic to the spleen in echogenicity and appropriately mildly coarse and homogenous in echotexture. No focal lesions are observed. Visible vasculature and biliary tree appear normal without distension or congestion.

The gallbladder is non-distended in size. The wall is smooth without visible thickening. Luminal contents are primarily anechoic. There is no evidence of cystic or common bile duct dilation.

**Gastrointestinal**

The visible stomach wall is normal in thickness and layering. The lumen of the stomach is empty with no evidence of obstruction, foreign material or infiltrative disease. Pyloric outflow tract appears patent.



## PATIENT

Apollo Cruz

## SPECIES

Canine

## BREED

Labrador Retriever

## SEX

Castrated Male

## AGE

9 Years 5 Months

## WEIGHT

57.7

## INTERPRETED BY

Beth Johnson, DVM  
DACVIM

## IMAGING PERFORMED BY

Dr. Christensen

## HOSPITAL NAME

Tranquility Veterinary  
Clinic

## REFERRING VET

Dr. Christensen

## INVOICE

73279

## DATE

2/25/26

The visible small intestines are normal in wall thickness and layering. Small intestinal motility appears adequate (1-3 contractions per min). The lumen of the small intestine is empty with no evidence of obstruction, foreign material or infiltrative disease.

The visible colon is normal in wall thickness (< 0.2 cm) and layering. Contents are consistent with normal formed feces and gas.

### **Pancreas**

The pancreas that is observed appears appropriately isoechoic to surrounding omental fat. Visible capsule is smooth and normal in contour. Visible pancreatic parenchyma is homogenous and unremarkable. There is no visible pancreatic duct dilation. There is no evidence of active peripancreatic inflammation.

### **Free Abdomen**

There is no visible free peritoneal effusion noted in these images.

There is no apparent pathologic lymphadenopathy noted in these images.

## ULTRASONOGRAPHIC FINDINGS

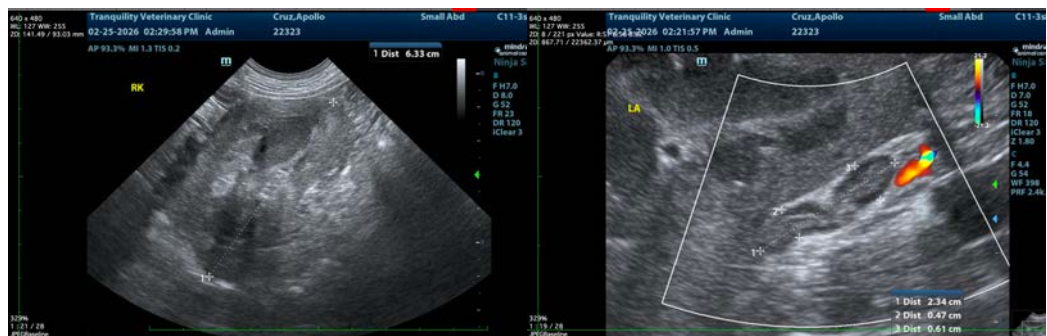- Very mild/subtle bilateral medullary rim sign - This finding is of unknown clinical significance and can be a normal variant, often idiopathic. Medullary rim sign can be present with renal disease including lymphoma, hypercalcemic nephropathy, Leptospirosis, tubular disease, other and should be interpreted in combination with other more specific indications of kidney disease such as isosthenuria, proteinuria, azotemia, etc. This is a common incidental finding in patients with diabetes mellitus.

## INTERPRETATION OF THE FINDINGS & FURTHER RECOMMENDATIONS

As is reportedly already pending, a urinalysis and, if indicated based on urinalysis results, urine culture is recommended. If protein is present in an otherwise quiet sediment, protein quantification with a urine protein to creatinine ratio is recommended.

A baseline cortisol is recommended. If baseline cortisol is less than 2, a full ACTH stimulation test is recommended to rule out hypoadrenocorticism.

In the meantime, as is reportedly already in place, a full cardiac evaluation is recommended.





## PATIENT

Apollo Cruz

## SPECIES

Canine

## BREED

Labrador Retriever

## SEX

Castrated Male

## AGE

9 Years 5 Months

## WEIGHT

57.7

## INTERPRETED BY

Beth Johnson, DVM  
DACVIM

## IMAGING PERFORMED BY

Dr. Christensen

## HOSPITAL NAME

Tranquility Veterinary  
Clinic

## REFERRING VET

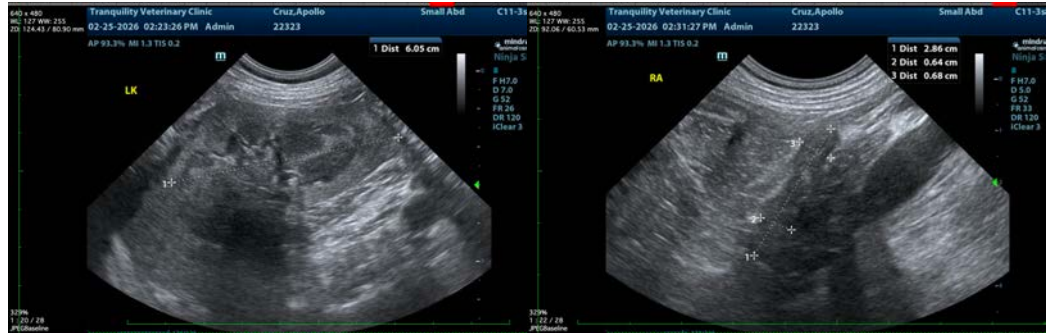
Dr. Christensen

## INVOICE

73279

## DATE

2/25/26



The information and recommendations provided are based on the images presented by the referring veterinarian/sonographer. No evaluation can be communicated regarding pathology that was not visible in the image/video clips provided.

Thank you for this referral. If the clinical or image interpretation does not parallel your findings or if I can be of any further assistance please contact me.

**Beth Johnson, DVM, DACVIM**  
info@sonopath.com