



PATIENT

Zoomi Brennan

SPECIES

Feline

BREED

DSH

SEX

Spayed Female

AGE

1

WEIGHT

12

INTERPRETED BY

Beth Johnson, DVM,
DACVIM (SAIM)

IMAGING PERFORMED BY

Jenn

HOSPITAL NAME

Rockaway AH

REFERRING VET

Dr. Maniar

INVOICE

35957

DATE

2/24/26

PRESENTING CLINICAL SIGNS

History: decreased urine output, and stool production

Abnormal PE/Chem/CBC/UA Results: proteinuria and hematuria

ULTRASONOGRAPHIC EXAMINATION OF THE ABDOMEN

Urinary System

Urinary bladder is adequately distended. It has a normal uniform wall thickness. Contents include primarily anechoic fluid with occasional echogenic non-shadowing debris, most consistent with incidental suspended lipid in a cat, possibly combined with exfoliated cells, mucous and/or small blood clots. Both sterile inflammation as well as urinary tract infection can also present with echogenic debris. No masses or definitive cystoliths are observed. The trigone and visible pelvic urethra are normal in thickness with a smooth mucosal surface.

Left kidney is normal in size (3.3 cm), shape and echogenicity. It has smooth peripheral margination. There is a normal 1:3 cortex to medulla ratio with appropriate corticomedullary distinction. There is no evidence of pyelectasia, mineral or infarcts observed.

Right kidney is normal in size (3.5 cm), shape and echogenicity. It has smooth peripheral margination. There is a normal 1:3 cortex to medulla ratio with appropriate corticomedullary distinction. There is no evidence of pyelectasia, mineral or infarcts observed.

Adrenal Glands

The adrenal glands are unable to be well visualized in these images.

Spleen

Spleen is subjectively normal in size with a normal smooth capsular contour. Parenchyma is appropriately finely textured and homogenous with normal echogenicity relative to surrounding tissue (hyperechoic to liver). No focal nodules or masses are observed. Splenic vasculature appears normal.

Liver

Liver is subjectively normal in size with normal smooth curvilinear peripheral contour. Parenchyma is appropriately hypoechoic to the spleen in echogenicity and appropriately mildly coarse and homogenous in echotexture. No focal lesions are observed. Visible vasculature and biliary tree appear normal without distension or congestion.

Gallbladder is non-distended in size. The wall is smooth without visible thickening. Luminal contents are primarily anechoic. There is no evidence of cystic or common bile duct dilation.

Gastrointestinal

The visible stomach wall is normal in thickness and layering. The lumen of the stomach is empty with no evidence of obstruction, foreign material or infiltrative disease. Pyloric outflow tract appears patent.



PATIENT

Zoomi Brennan

The visible small intestines are normal in wall thickness and layering. Small intestinal motility appears adequate (1-3 contractions per min). The lumen of the small intestine is empty with no evidence of obstruction, foreign material or infiltrative disease.

SPECIES

Feline

The visible colon is normal in wall thickness (< 0.2 cm) and layering. Contents are consistent with normal formed feces and gas.

Pancreas

BREED

DSH

The pancreas that is observed appears appropriately isoechoic to surrounding omental fat. Visible capsule is smooth and normal in contour. Visible pancreatic parenchyma is homogenous and unremarkable. There is no visible pancreatic duct dilation. There is no evidence of active peripancreatic inflammation.

SEX

Spayed Female

Free Abdomen

AGE

1

There is no visible free peritoneal effusion noted in these images.

There is no apparent pathologic lymphadenopathy noted in these images.

ULTRASONOGRAPHIC FINDINGS

- A very mild amount of echogenic urinary bladder debris
- Otherwise, this is a largely unremarkable/normal structural abdomen.

INTERPRETED BY

Beth Johnson, DVM,
DACVIM (SAIM)

INTERPRETATION OF THE FINDINGS & FURTHER RECOMMENDATIONS

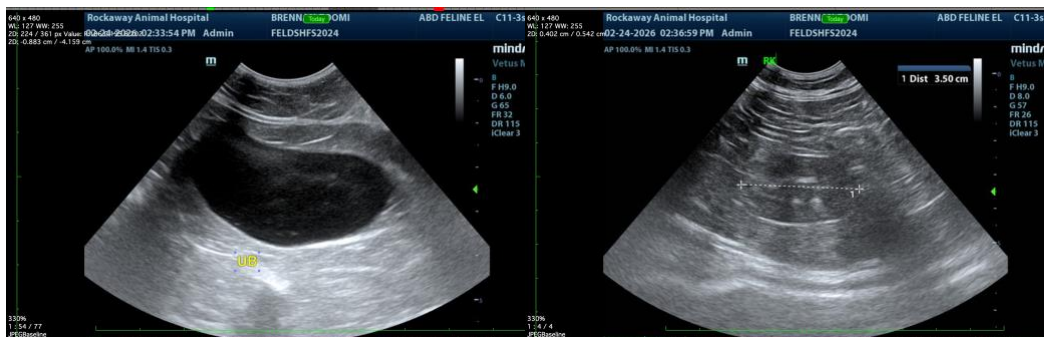
There is no definitive ultrasonographically visible intraabdominal pathology to explain patients reportedly decreased urine output and stool production. Further recommendations are largely dependent on whether patient is straining to produce versus just not producing, which could potentially be secondary to decreased intake, altering further diagnostic and treatment recommendations. Additionally, further urinary recommendations, given the proteinuria, hematuria, etc., are dependent on full urinalysis results, including any evidence of bacteria, etc.

IMAGING PERFORMED BY

Jenn

HOSPITAL NAME

Rockaway AH



REFERRING VET

Dr. Maniar

INVOICE

35957

DATE

2/24/26



PATIENT

Zoomi Brennan

SPECIES

Feline

BREED

DSH

SEX

Spayed Female

AGE

1

WEIGHT

12

INTERPRETED BY

Beth Johnson, DVM,
DACVIM (SAIM)

IMAGING PERFORMED BY

Jenn

HOSPITAL NAME

Rockaway AH

REFERRING VET

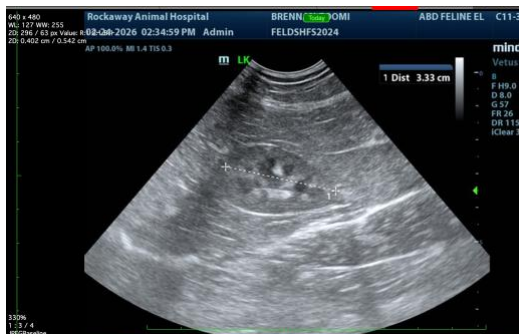Dr. Maniar

INVOICE

35957

DATE

2/24/26



The information and recommendations provided are based on the images presented by the referring veterinarian/sonographer. No evaluation can be communicated regarding pathology that was not visible in the image/video clips provided.

Thank you for this referral. If the clinical or image interpretation does not parallel your findings or if I can be of any further assistance please contact me.

Beth Johnson, DVM DACVIM

info@sonopath.com