



## PATIENT

Wrigley Lum

## SPECIES

Canine

## BREED

Lab X

## SEX

MN

## AGE

11 years 6 months

## WEIGHT

78.6

## INTERPRETED BY

Beth Johnson, DVM  
DACVIM

## IMAGING PERFORMED BY

Dr. Warner

## HOSPITAL NAME

VT-NH Veterinary  
Clinic

## REFERRING VET

Dr. Warner

## INVOICE

11352

## DATE

2/24/2026

## PRESENTING CLINICAL SIGNS

- Wrigley presented today for removal of a mass on his anus and 3 dermal masses on his face. At his pre-anesthetic bloodwork, it was noted that anemia had recurred
- Senior panel run in August showed mild anemia which corrected at recheck
- No c/s/v/d or other symptoms are reported
- Wrigley is on daily meds for behavior, as well as carprofen & Librela for OA

Abnormal PE/Chem/CBC/UA Results: 8/27 RBC 6.18, HCT 37.8, Hg 13.8, MCV 61 10/3 PCV 43%, TS 5.2 2/24 RBC 5.62, Hct 36.2, Hg 13, MCV normal at 64.4, lympho 0.7 Chemistries have remained normal.

## ULTRASONOGRAPHIC EXAMINATION OF THE ABDOMEN

### Urinary System

The urinary bladder is adequately distended with anechoic contents. No masses, inflammatory changes, echogenic sediment or cystoliths are observed. The urinary bladder, trigone and visible pelvic urethra are normal in thickness with a smooth mucosal surface.

The prostate is unable to be well visualized in these images.

The right kidney is normal is size (6.56 cm), shape and echogenicity. It has smooth peripheral margination. There is a normal 1:3 cortex to medulla ratio with appropriate corticomedullary distinction. There is no evidence of pyelectasia, mineral or infarcts observed.

The left kidney is normal is size (5.98 cm), shape and echogenicity. It has smooth peripheral margination. There is a normal 1:3 cortex to medulla ratio with appropriate corticomedullary distinction. There is no evidence of pyelectasia, mineral or infarcts observed.

### Adrenal Glands

The adrenal glands are unable to be visualized in these images.

### Spleen

There appears to be an approximately 7.0 cm x 8.3+ cm mixed, largely cavitated, slightly hyperechoic mass originating from the medial cranial aspect of the spleen. \*See Liver\*

### Liver

The liver is normal. In some views of what I suspect is the previously described mass, the mass appears slightly more cranial with origination from the liver unable to be definitively ruled out. I suspect based on sonographer history that only one mass was visualized but two separate masses is also a possibility. In the views where it's difficult to rule out liver versus spleen, the mass measures approximately 9.0 cm x 10.0 cm in size.

Gallbladder is moderately distended with anechoic bile as well as suspended and gravity dependent echogenic debris. The wall is smooth without visible thickening. There is no evidence of cystic or CBD dilation. There is no evidence of effusion or inflammation.

### Gastrointestinal



**PATIENT**

Wrigley Lum

The visible stomach wall is normal in thickness and layering. The lumen of the stomach is empty with no evidence of obstruction, foreign material or infiltrative disease. Pyloric outflow tract appears patent.

**SPECIES**

Canine

The visible small intestines are normal in wall thickness and layering. Small intestinal motility appears adequate (1-3 contractions per min). The lumen of the small intestine is empty with no evidence of obstruction, foreign material or infiltrative disease.

**BREED**

Lab X

The visible colon is normal in wall thickness (< 0.2 cm) and layering. Contents are consistent with normal formed feces and gas.

**SEX**

MN

The pancreas that is observed appears appropriately isoechoic to surrounding omental fat. Visible capsule is smooth and normal in contour. Visible pancreatic parenchyma is homogenous and unremarkable. There is no visible pancreatic duct dilation. There is no evidence of active peripancreatic inflammation.

**AGE**

11 years 6 months

**Free Abdomen**

In the caudal abdomen, just cranial to the urinary bladder is a discrete, approximately 2.0 cm in diameter, homogenous, hyperechoic density.

**WEIGHT**

78.6

**ULTRASONOGRAPHIC FINDINGS**

**INTERPRETED BY**

Beth Johnson, DVM  
DACVIM

- The suspected splenic mass could represent a benign process such as extramedullary hematopoiesis, nodular hyperplasia, cysts, hematoma, other. Although infiltrative neoplasia including sarcoma versus other can't be ruled out without tissue sampling. As described above, a second mass isn't mentioned in the sonographer's history but can't be definitively ruled out. I suspect I'm seeing one mass of splenic origin, but similarly liver origin can't be definitively ruled out. The density cranial to the urinary bladder may or may not be related to this pathology but has the appearance of fat such as a lipogranuloma versus other. Therefore, differentials trend baseline appearance toward benign. Although a metastatic lesion cannot be ruled out.

**IMAGING PERFORMED BY**

Dr. Warner

**HOSPITAL NAME**

VT-NH Veterinary  
Clinic

- Moderate gallbladder debris - Cholecystic debris is of unknown clinical significance. It can be seen with biliary stasis from fasting or illness. Cholecystic debris is not necessarily related to hepatobiliary disease. Echogenic bile is most commonly an incidental finding in dogs and should be interpreted in combination with clinical signs such as nausea, inappetence, cranial abdominal discomfort and/or laboratory changes such as increased ALP and/or increased Tbili.

**REFERRING VET**

Dr. Warner

**INTERPRETATION OF THE FINDINGS & FURTHER RECOMMENDATIONS**

**INVOICE**

11352

Three view thoracic radiographs are recommended for further assessment of cardio-pulmonary status as well as to further evaluate for any evidence of metastatic disease, if not recently evaluated.

**DATE**

2/24/2026

Fine needle aspirates of the suspected splenic mass, as well as the density cranial to the urinary bladder could be considered if patient's coagulation status is appropriate.



**PATIENT**

Wrigley Lum

**SPECIES**

Canine

**BREED**

Lab X

**SEX**

MN

**AGE**

11 years 6 months

**WEIGHT**

78.6

**INTERPRETED BY**

Beth Johnson, DVM  
DACVIM

**IMAGING PERFORMED BY**

Dr. Warner

**HOSPITAL NAME**

VT-NH Veterinary  
Clinic

**REFERRING VET**

Dr. Warner

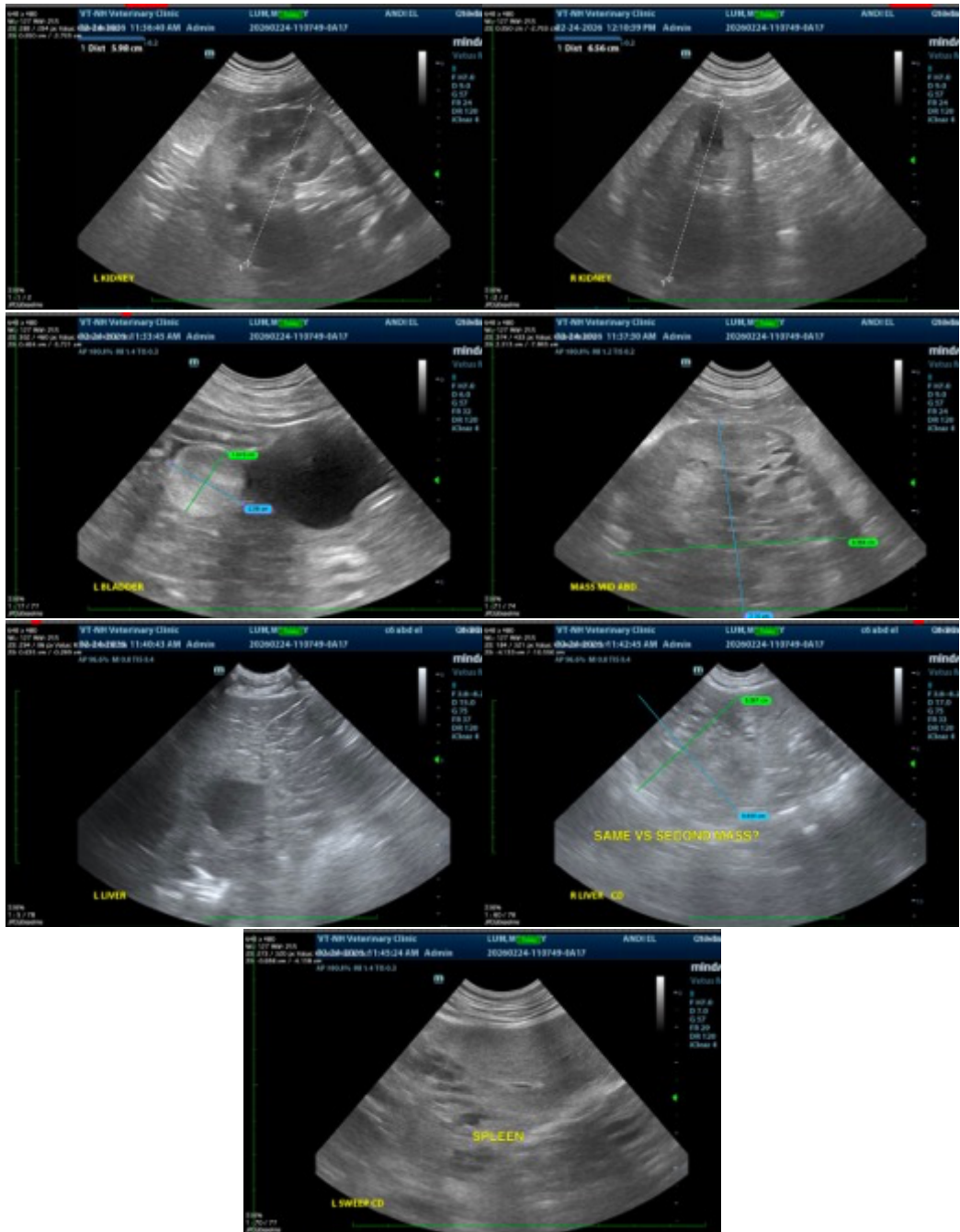
**INVOICE**

11352

**DATE**

2/24/2026

Alternatively, or a cytologic diagnosis is unable to be obtained, an exploratory laparotomy for planned splenectomy as well as biopsies/removal of any additional pathology may be indicated. If surgery is pursued, a pre-surgical planning abdominal CT Scan may be helpful.



The information and recommendations provided are based on the images presented by the referring veterinarian/sonographer. No evaluation can be communicated regarding pathology that was not visible in the image/video clips provided.



## PATIENT

Wrigley Lum

## SPECIES

Canine

## BREED

Lab X

## SEX

MN

## AGE

11 years 6 months

## WEIGHT

78.6

## INTERPRETED BY

Beth Johnson, DVM  
DACVIM

## IMAGING PERFORMED BY

Dr. Warner

## HOSPITAL NAME

VT-NH Veterinary  
Clinic

## REFERRING VET

Dr. Warner

## INVOICE

11352

## DATE

2/24/2026

Thank you for this referral. If the clinical or image interpretation does not parallel your findings or if I can be of any further assistance please contact me.

**Beth Johnson, DVM, DACVIM**  
info@sonopath.com