



PATIENT

Remington Schisler

SPECIES

Canine

BREED

Brittany Spaniel

SEX

Spayed Female

AGE

10 Years 10 Months

WEIGHT

33.8

INTERPRETED BY

Beth Johnson, DVM
DACVIM

IMAGING PERFORMED BY

Jessica Green

HOSPITAL NAME

Stanglein Veterinary
Clinic

REFERRING VET

Dr. Nathaniel Stanglein

INVOICE

73233

DATE

2/24/26

PRESENTING CLINICAL SIGNS

PU/PD and suspicion of Cushings disease but ACTH stim test was normal. Elevated ALP on BW. Concern for atypical Cushings vs DI or psychogenic drinking vs other abdominal causes

ULTRASONOGRAPHIC EXAMINATION OF THE ABDOMEN

Urinary System

The urinary bladder is adequately distended with anechoic contents. No masses, inflammatory changes, echogenic sediment or cystoliths are observed. The urinary bladder, trigone and visible pelvic urethra are normal in thickness with a smooth mucosal surface.

Kidneys are overall normal in size and shape with smooth peripheral margination. A normal 1:3 cortex to medulla ratio is maintained. The medulla and cortices are uniform in texture with some mild increased cortical echogenicity and mild loss of corticomedullary distinction, expected in this age patient. There is no evidence of pyelectasia, mineral or infarcts observed. Left kidney measures 5.63 cm. Right kidney measures 5.8 cm.

Adrenal Glands

The right adrenal gland is normal in size (0.49 cm at cranial pole and 0.40 cm at caudal pole), shape and overall architecture, echogenicity and echotexture. Visible surrounding vasculature appears normal.

The left adrenal gland is normal in size (0.51 cm at cranial pole and 0.63 cm at caudal pole), shape and overall architecture, echogenicity and echotexture. Visible surrounding vasculature appears normal.

Spleen

The spleen is subjectively normal in size with a normal smooth capsular contour. Parenchyma is appropriately finely textured and homogenous with normal echogenicity relative to surrounding tissue (hyperechoic to liver). No focal nodules or masses are observed. Splenic vasculature appears normal.

Liver

Liver is subjectively enlarged with mildly irregular margins. Parenchyma is moderately heterogenous characterized by multiple poorly defined hypoechoic nodules within otherwise hyperechoic liver parenchyma. Visible vasculature and biliary tree appear normal without distension or congestion.

The gallbladder is non-distended in size. The wall is smooth without visible thickening. Luminal contents are primarily anechoic. There is no evidence of cystic or common bile duct dilation.

Gastrointestinal

The visible stomach wall is normal in thickness and layering. The lumen of the stomach is mildly distended with very echogenic reverberation artifact from intraluminal gas. There is no evidence of obstruction, foreign material, or infiltrative disease; however, visualization is partially inhibited by gas.

The visible small intestines are normal in wall thickness and layering. Small intestinal motility appears adequate (1-3 contractions per min). The lumen of the small intestine is mildly distended with very echogenic reverberation artifact from intraluminal gas. There is no evidence of obstruction, foreign material, or infiltrative disease; however, visualization is partially inhibited by gas.



PATIENT

Remington Schisler

SPECIES

Canine

BREED

Brittany Spaniel

SEX

Spayed Female

AGE

10 Years 10 Months

WEIGHT

33.8

INTERPRETED BY

Beth Johnson, DVM
DACVIM

IMAGING PERFORMED BY

Jessica Green

HOSPITAL NAME

Stanglein Veterinary
Clinic

REFERRING VET

Dr. Nathaniel Stanglein

INVOICE

73233

DATE

2/24/26

The visible colon is normal in wall thickness (< 0.2 cm) and layering. Contents are consistent with normal formed feces and gas.

Pancreas

The pancreas that is observed appears appropriately isoechoic to surrounding omental fat. Visible capsule is smooth and normal in contour. Visible pancreatic parenchyma is homogenous and unremarkable. There is no visible pancreatic duct dilation. There is no evidence of active peripancreatic inflammation.

Free Abdomen

There is no visible free peritoneal effusion noted in these images.

There is no apparent pathologic lymphadenopathy noted in these images.

PRIMARY FINDINGS

- Moderately heterogenous liver – These changes are most consistent with benign processes such as nodular hyperplasia, steroid (vacuolar) hepatopathy, extramedullary hematopoiesis or possibly chronic inflammatory disease and less commonly infiltrative round cell or metastatic neoplasia.

SECONDARY FINDINGS

- Age related kidney changes.

INTERPRETATION OF THE FINDINGS & FURTHER RECOMMENDATIONS

Given patient's history, a urinalysis and, if indicated based on urinalysis results, urine culture is recommended. If protein is present in an otherwise quiet sediment, protein quantification with a urine protein to creatinine ratio is recommended.

Additionally, a blood pressure is recommended.

Normal appearing adrenal glands do not rule out hyperadrenocorticism. Therefore, if clinically suspected and another underlying cause for the reported PU/PD is not diagnosed, more sensitive hormone testing could be considered in the form of a low-dose Dexamethasone suppression test.

Differentials for PU/PD are vast and include, but are not limited to:

Primary polyuria caused by chronic kidney disease, pyelonephritis, liver disease, diabetes mellitus, hyperthyroidism, hypercalcemia, hyperadrenocorticism, hypoadrenocorticism, E.coli infections ie) pyometra in females, polycythemia, central diabetes insipidus or primary nephrogenic diabetes insipidus.

Primary polydipsia caused by psychogenic polydipsia, fever, pain, or central nervous system disease.

Most causes of PU/PD can be diagnosed with a comprehensive history and physical exam, a first AM urine specific gravity to see if urine concentration is possible (as most animals naturally consume less water overnight) followed by a comprehensive CBC, serum chemistry panel, electrolytes, and urinalysis.



PATIENT

Remington Schisler

SPECIES

Canine

BREED

Brittany Spaniel

SEX

Spayed Female

AGE

10 Years 10 Months

WEIGHT

33.8

INTERPRETED BY

Beth Johnson, DVM
DACVIM

IMAGING PERFORMED BY

Jessica Green

HOSPITAL NAME

Stanglein Veterinary
Clinic

REFERRING VET

Dr. Nathaniel Stanglein

INVOICE

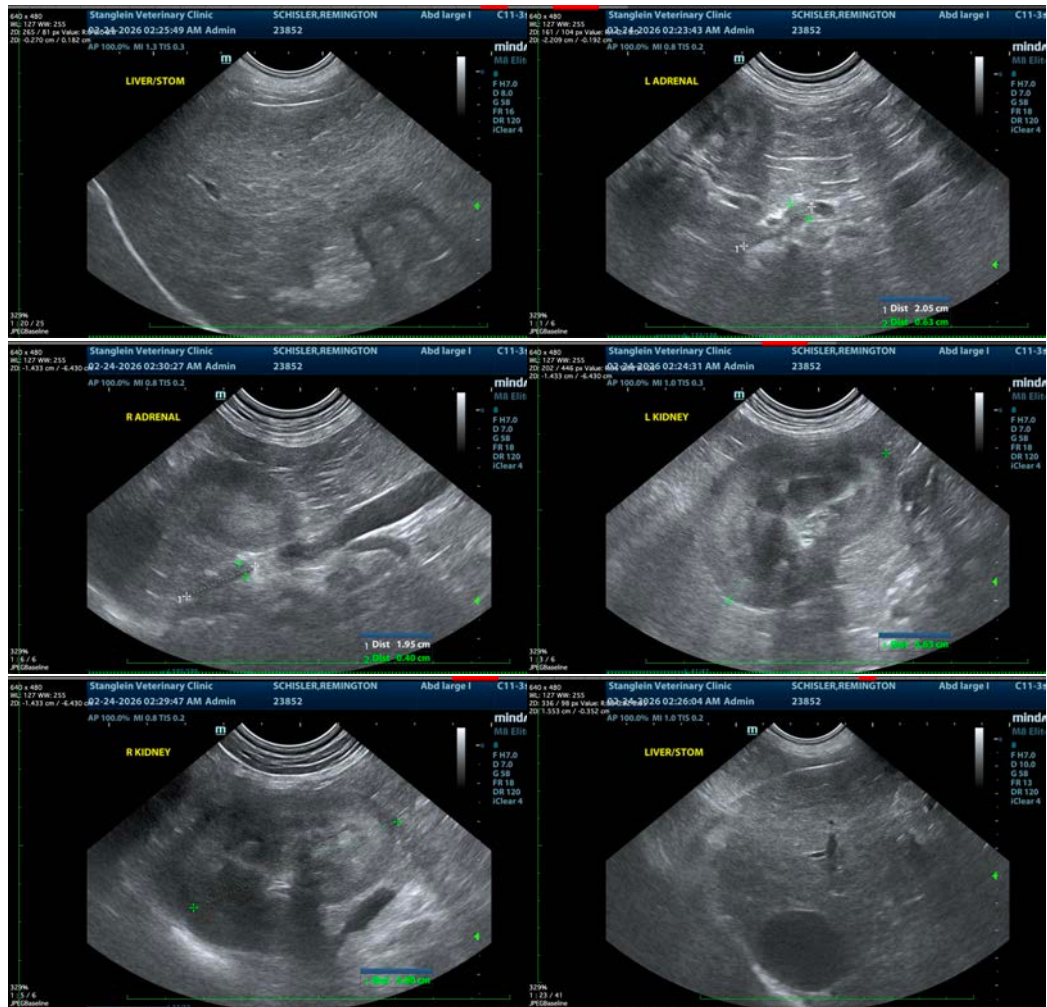
73233

DATE

2/24/26

If not, next step(s) may include a urine culture, low dose dexamethasone suppression test, T4, bile acids, Leptospirosis testing and/or an empirical course of antibiotics.

If a diagnosis is still not obtained, a more advanced work-up is indicated and consultation with an internist may be warranted.



The information and recommendations provided are based on the images presented by the referring veterinarian/sonographer. No evaluation can be communicated regarding pathology that was not visible in the image/video clips provided.

Thank you for this referral. If the clinical or image interpretation does not parallel your findings or if I can be of any further assistance please contact me.

Beth Johnson, DVM, DACVIM
info@sonopath.com