



DATE PRESENTING CLINICAL SIGNS

2/24/26 **Patient History:** Cushings for 3 years; abdominal mass palpated on recent physical exam.

PATIENT Current Medications: Vetoryl 60mg QD, Thyroxine 0.5mg BID.

Henry Cornwell **Labwork Results:** Labwork not attached, reported as pending.

Date of Previous IntraPet Ultrasound: No previous.

Sedation: Not required to complete full diagnostic ultrasound.

Stat Report: Declined.

SPECIES Imaging Performed by: Stephanie Warga RDCS, RVT.

Canine

ULTRASONOGRAPHIC EXAMINATION OF THE ABDOMEN

BREED Urinary System

Lab x

The urinary bladder is adequately distended with anechoic contents. No masses, inflammatory changes, echogenic sediment or cystoliths are observed. The urinary bladder, trigone and visible pelvic urethra are normal in thickness with a smooth mucosal surface.

SEX

Neutered Male

Prostate is normal in size, echotexture and echogenicity for a neutered male.

AGE

1/5/13

The left kidney is large in size (12.9 cm) owing to a large, heterogeneous mass as described in "other" involving the entire cranial pole. Trace pyelectasia is noted in the left kidney.

WEIGHT

93.1 lbs

The right kidney has a more normal appearance measures 7.3 cm in size but does contain at least one discrete homogeneous hypoechoic nodule.

INTERPRETED BY

Adrenal Glands

Beth Johnson, DVM
DACVIM

The adrenal glands are unable to be visualized.

Spleen

HOSPITAL NAME

Chadwell Animal
Hospital

The spleen is diffusely made up of mixed heterogeneous masses of varying sizes, and is largely hypoechoic in appearance.

Liver

REFERRING VET

Dr. Gold

The liver is diffusely made up of mixed heterogeneous masses of varying sizes, and is largely hypoechoic in appearance.

INVOICE

73241

Gallbladder is moderately distended with anechoic bile as well as suspended and gravity dependent echogenic debris. The wall is smooth without visible thickening. There is no evidence of cystic or CBD dilation. There is no evidence of effusion or inflammation.

Gastrointestinal

The stomach is unable to be fully visualized but may be mildly thick in some views. There are no definitive masses involving the stomach, and no definitive loss of layering. The lumen of the stomach is mildly distended

with very echogenic reverberation artifact from intraluminal gas. There is no evidence of obstruction, foreign material, or infiltrative disease; however, visualization is partially inhibited by gas.

The bowel that is definitively identifiable as bowel is normal in wall thickness and layering. Small intestinal motility appears adequate (1-3 contractions per min). The lumen of the small intestine is empty with no evidence of obstruction, foreign material or infiltrative disease.

The visible colon is normal in wall thickness (< 0.2 cm) and layering. Contents are consistent with normal formed feces and gas.

Pancreas

The pancreas is unable to be well visualized in these images.

Free Abdomen

Throughout the abdomen, as well as adjacent to the heart base, and appearing to involve almost every organ, are multiple, large, mixed, heterogeneous, primarily hypoechoic nodules/masses of varying shapes, sizes, etc. are present throughout the cranial mid and caudal abdomen, with some unable to be definitively identified in terms of organ origination. Definitive nodules/masses affect both kidneys, the spleen, the liver. There are too many masses to describe individually and provide measurements for in the description, but pictures of a variety of masses with measurements are included. Additionally, there appears to be a more solid hypoechoic density/mass adjacent to the base of the heart.

There is no visible free peritoneal effusion noted in these images.

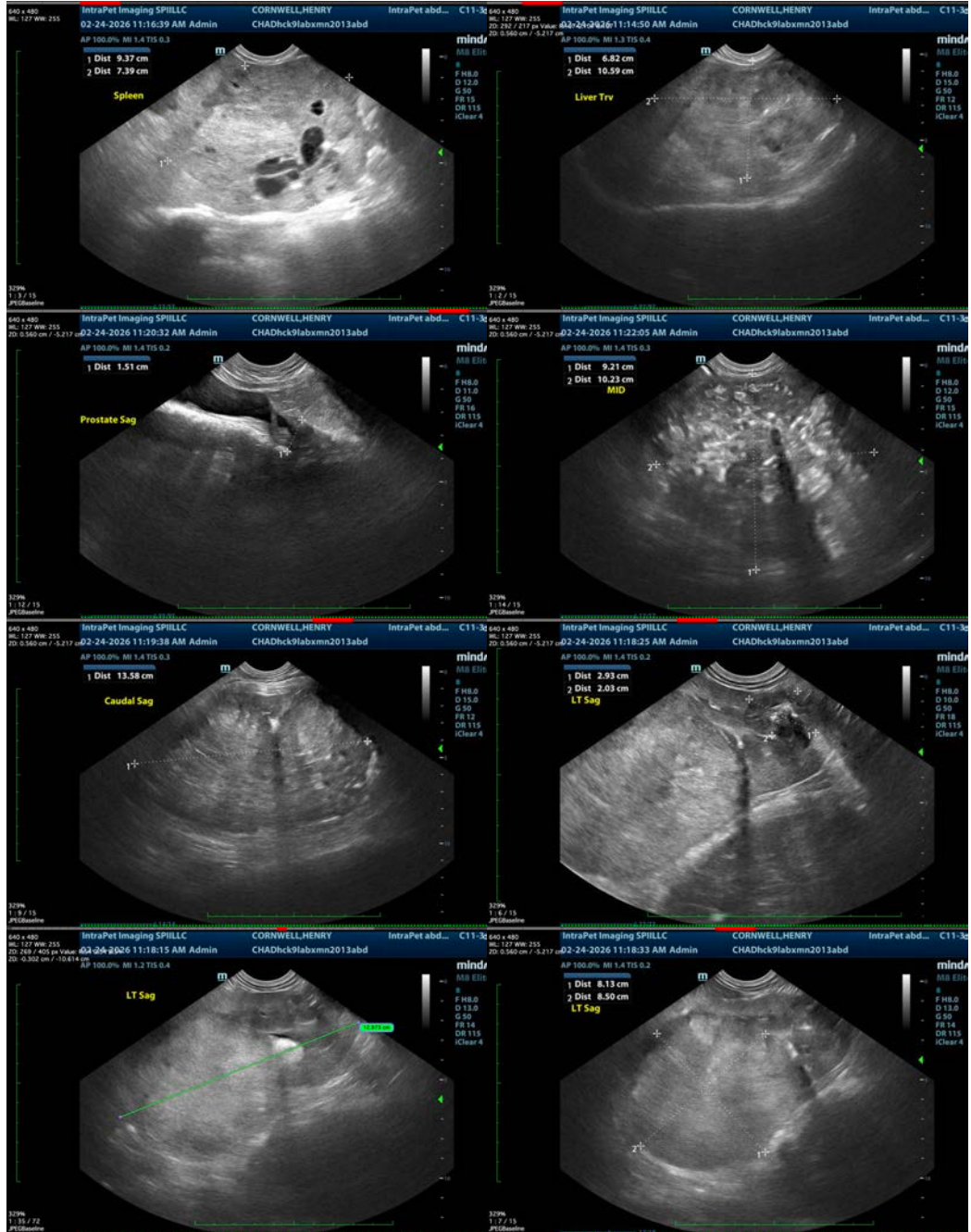
There is no apparent pathologic lymphadenopathy noted in these images.

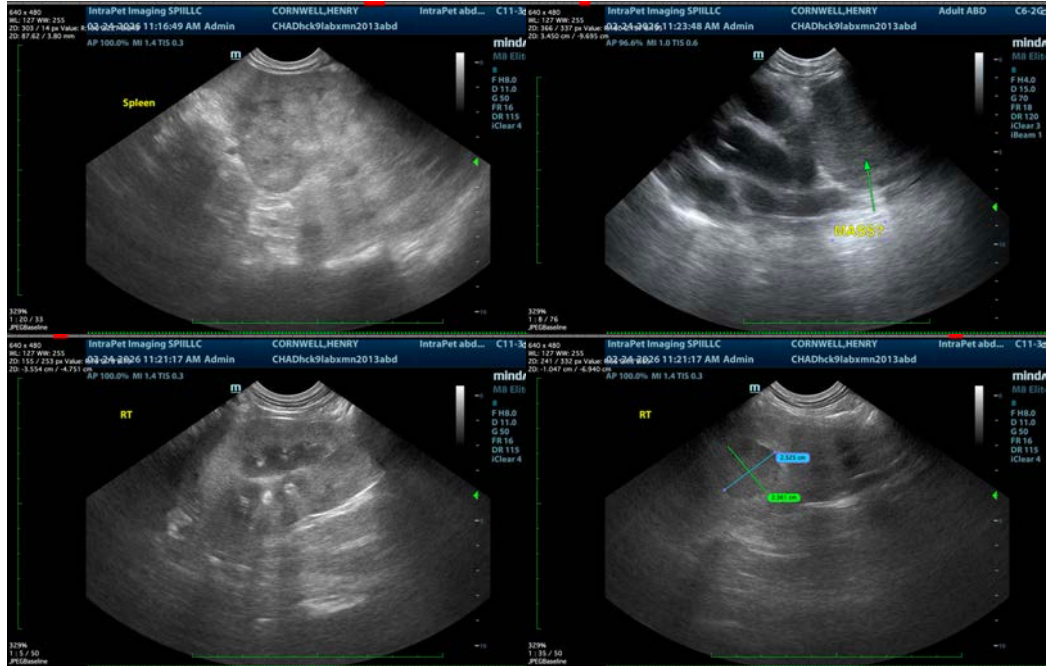
ULTRASONOGRAPHIC FINDINGS

- Mixed heterogeneous masses throughout the abdomen and thorax involving almost every organ – Most concerning for infiltrative malignant neoplasia i.e., round cell neoplasia versus metastatic nodules versus other. A diffuse but benign inflammatory, infectious or other inflammatory process is possible but considered much less likely.

INTERPRETATION OF THE FINDINGS & FURTHER RECOMMENDATIONS

Tissue sampling is recommended. Fine needle aspirates of any variety of the masses described above could be considered if patient's coagulation status is appropriate. Additionally, and/or alternatively, advanced imaging such as thoracic and abdominal contrast CT scan could be considered to more definitively identify the location of the pathology.





The information and recommendations provided are based on the images presented by the referring veterinarian/sonographer. No evaluation can be communicated regarding pathology that was not visible in the image/video clips provided.

Thank you for this referral. If the clinical or image interpretation does not parallel your findings or if I can be of any further assistance please contact me.

Beth Johnson, DVM, DACVIM
info@sonopath.com