



PATIENT

Doris Day Weselowski

SPECIES

Canine

BREED

Yorkshire Terrier

SEX

FS

AGE

13 years

WEIGHT

2.9 kg

INTERPRETED BY

Beth Johnson, DVM
DACVIM

IMAGING PERFORMED BY

Dr. Gira

HOSPITAL NAME

Dewinton PH

REFERRING VET

Dr. Kathy Weston

INVOICE

11363

DATE

2/24/2026

PRESENTING CLINICAL SIGNS

- Hx of on and off vomiting, diarrhea and inappetence. Hx of PU/PD. Suspected IBD and chronic pancreatitis. Currently being treated for KCS.
- Dry cough elicited on tracheal palpation. Grade II heart murmur.

Abnormal PE/Chem/CBC/UA Results: CBC RBC 9.42 (5.82-8.90), HGB 23 (13.2-22.), HCT 61.5 (36.9-60.0) CHEM TP 41 (55-76) ,ALB 18 (25-40) ,TBIL 13 (0-9) ,TCHO 2.30 (3.10-8.02), IP 1.85 (0.61-1.61) ,GGT 15 (0-14) ,Ca 2.02 (2.25-3.10) 1.87, TG 2.22 (0.34-1.47), K 3.6 (3.8-5.3), T4 31 (15-55), Nu.Q 16 (0-50) low suspicion, SDMA 23.5 (0.0-15.0), LIP 288.2 (0.0-125.0.)

ULTRASONOGRAPHIC EXAMINATION OF THE ABDOMEN

Urinary System

The urinary bladder is adequately distended with anechoic contents. No masses, inflammatory changes, echogenic sediment or cystoliths are observed. The urinary bladder, trigone and visible pelvic urethra are normal in thickness with a smooth mucosal surface.

Kidneys are overall normal in size and shape with smooth peripheral margination. A normal 1:3 cortex to medulla ratio is maintained. The medulla and cortices are uniform in texture with some mild increased cortical echogenicity and mild loss of corticomedullary distinction, expected in this age patient. There is no evidence of pyelectasia, mineral or infarcts observed. Left kidney measures 3.48 cm, and the right kidney measures 3.41 cm.

Adrenal Glands

The right adrenal gland is normal in size (0.42 cm at cranial pole and 0.66 cm at caudal pole), shape and overall architecture, echogenicity and echotexture. Visible surrounding vasculature appears normal.

The left adrenal gland is normal in size (0.43 cm at cranial pole and 0.43 cm at caudal pole), shape and overall architecture, echogenicity and echotexture. Visible surrounding vasculature appears normal.

Spleen

Spleen is subjectively large in size with a normal smooth capsular contour. Parenchyma is appropriately finely textured and homogenous with normal echogenicity relative to surrounding tissue (hyperechoic to liver). An approximately 0.5 cm x 0.3 cm non-capsular disrupting, hypo- to anechoic nodule is noted near the caudal aspect of the spleen. Splenic vasculature appears normal. The spleen is folded upon itself, which is a positional non-pathologic variant.

Liver

The liver is subjectively normal in size with normal smooth curvilinear peripheral contour. Parenchyma is appropriately hypoechoic to the spleen in echogenicity and appropriately mildly coarse and homogenous in echotexture. No focal lesions are observed. Visible vasculature and biliary tree appear normal without distension or congestion.

The gallbladder is non-distended in size. The wall is smooth without visible thickening. Luminal contents are primarily anechoic. There is no evidence of cystic or common bile duct dilation.

Gastrointestinal



PATIENT

Doris Day Weselowski

SPECIES

Canine

BREED

Yorkshire Terrier

SEX

FS

AGE

13 years

WEIGHT

2.9 kg

INTERPRETED BY

Beth Johnson, DVM
DACVIM

IMAGING PERFORMED BY

Dr. Gira

HOSPITAL NAME

Dewinton PH

REFERRING VET

Dr. Kathy Weston

INVOICE

11363

DATE

2/24/2026

The visible stomach wall is normal in thickness and layering. The lumen of the stomach is empty with no evidence of obstruction, foreign material or infiltrative disease. Pyloric outflow tract appears patent.

Small intestine is diffusely mildly thick with a relatively thick mucosa compared to other layers. Normal wall layering is preserved; however, the mucosa is more echogenic than normal and contains hyperechoic striations perpendicular to the lumen. The lumen of the small intestine is empty with no evidence of obstruction or foreign material.

The visible colon is normal in wall thickness (< 0.2 cm) and layering. Contents are consistent with normal formed feces and gas.

Pancreas

The area of the pancreas contains irregular hyperechoic pancreatic remodeling.

Free Abdomen

There is no visible free peritoneal effusion noted in these images.

There is no apparent pathologic lymphadenopathy noted in these images.

PRIMARY FINDINGS

- Lymphangiectasia – Small bowel findings are most consistent with lacteal dilation. These findings can be observed with protein-losing enteropathies caused by either primary lymphangiectasia or primary infiltrative inflammatory disease with secondary lymphangiectasia. Infiltrative neoplasia is possible but considered less likely. Histopathology is necessary to definitively determine underlying cause.
- Hyperechoic pancreas – This finding is suggestive of pancreatic fibrosis, possibly secondary to chronic pancreatitis. A TLI is recommended to rule out exocrine pancreatic insufficiency (EPI), especially if clinical signs (weight loss, diarrhea, etc.) are present.
- Mild Splenomegaly with hypo- to anechoic splenic nodule – can be associated with congestion caused by sedation (if sedated) but can also be associated with diffuse infiltrative disease. Both benign conditions such as extramedullary hematopoiesis, lymphoid hyperplasia, amyloidosis as well as infiltrative neoplastic diseases such as round cell neoplasia should be considered. Hypo to anechoic splenic nodule – likely represents a benign lesion such as a cyst, hematoma, nodular hyperplasia, extramedullary hematopoiesis, etc., however while considered less likely, infiltrative neoplasia can mimic benign lesions, and cannot be ruled out.

SECONDARY FINDINGS

- Age related kidney changes.

INTERPRETATION OF THE FINDINGS & FURTHER RECOMMENDATIONS

- A gastrointestinal malabsorption panel (including cobalamin, folate, TLI and PLI) to Texas A&M GI Laboratory is recommended for further evaluation of GI and pancreatic function.
- A baseline cortisol is recommended. If baseline cortisol is less than 2, a full ACTH stimulation test is recommended to rule out hypoadrenocorticism.



PATIENT

Doris Day Weselowski

SPECIES

Canine

BREED

Yorkshire Terrier

SEX

FS

AGE

13 years

WEIGHT

2.9 kg

INTERPRETED BY

Beth Johnson, DVM
DACVIM

IMAGING PERFORMED BY

Dr. Gira

HOSPITAL NAME

Dewinton PH

REFERRING VET

Dr. Kathy Weston

INVOICE

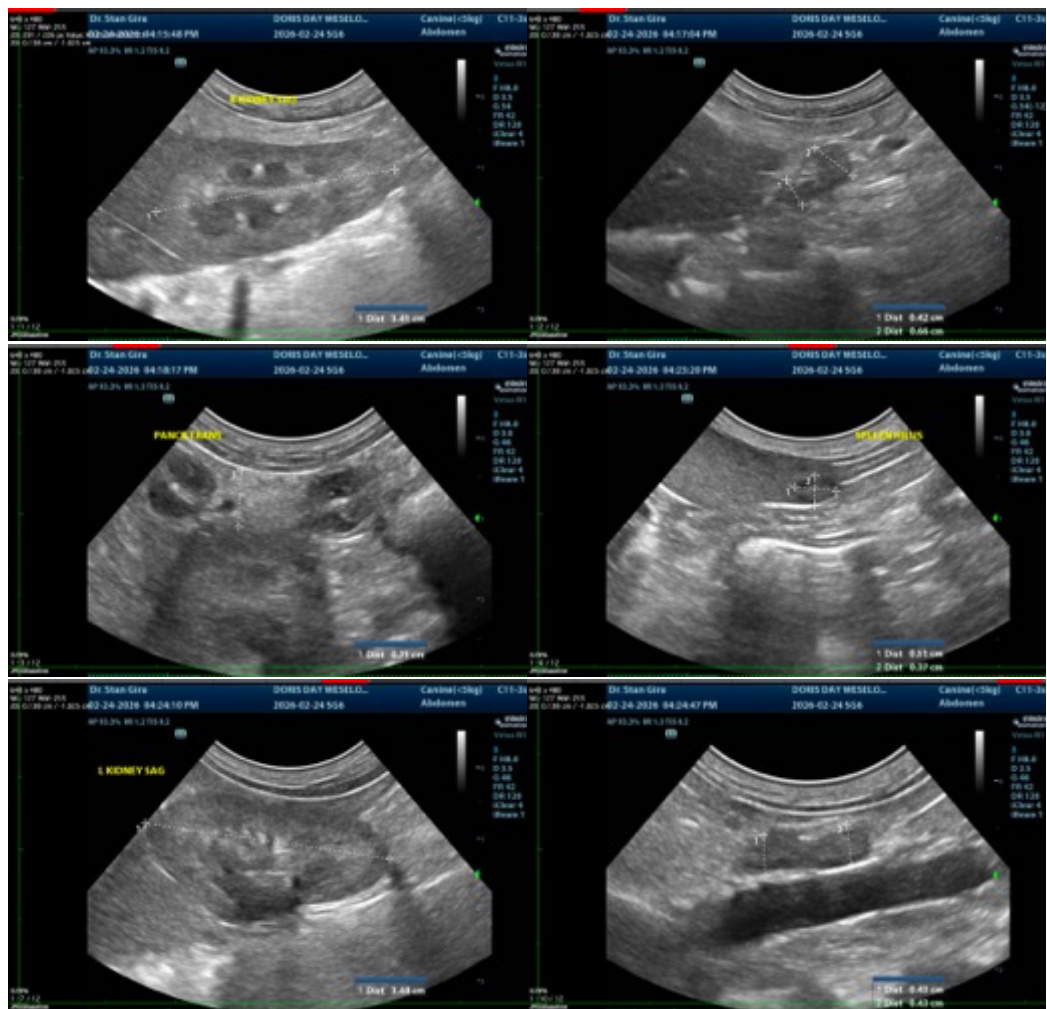
11363

DATE

2/24/2026

- Ideally, biopsies of the GI tract are recommended to definitively diagnose and therefore manage the infiltrative bowel process.
- If biopsies cannot be obtained safely due to low albumin or patient stability, etc., empirical therapies could include diet change to an ultra-low-fat diet, empirical deworming with a 5-day course of Panacur, cobalamin supplementation (unless cobalamin level is evaluated and supplementation is not warranted) a probiotic and prednisolone (if not contraindicated based on patient contraindications, co-morbidities, etc.).
- Calcium monitoring, and supplementation, if necessary, is also recommended.
- Additionally, if patient's coagulation status is otherwise appropriate, anti-thrombotics such as clopidogrel or low dose aspirin may also be warranted.

Additionally, if not recently evaluated, urinalysis and, if indicated based on urinalysis results, urine culture is recommended. If protein is present in an otherwise quiet sediment, protein quantification with a urine protein to creatinine ration is recommended.





PATIENT

Doris Day Weselowski

SPECIES

Canine

BREED

Yorkshire Terrier

SEX

FS

AGE

13 years

WEIGHT

2.9 kg

INTERPRETED BY

Beth Johnson, DVM
DACVIM

IMAGING PERFORMED BY

Dr. Gira

HOSPITAL NAME

Dewinton PH

REFERRING VET

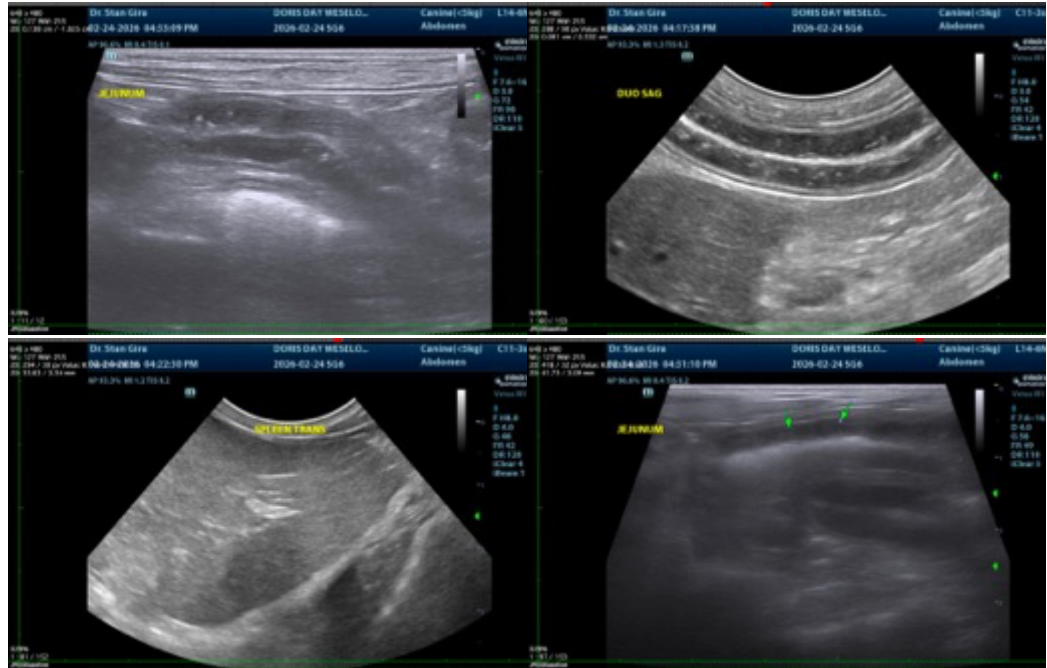
Dr. Kathy Weston

INVOICE

11363

DATE

2/24/2026



The information and recommendations provided are based on the images presented by the referring veterinarian/sonographer. No evaluation can be communicated regarding pathology that was not visible in the image/video clips provided.

Thank you for this referral. If the clinical or image interpretation does not parallel your findings or if I can be of any further assistance please contact me.

Beth Johnson, DVM, DACVIM
info@sonopath.com