



PATIENT

Dallas Kisiellus

SPECIES

Canine

BREED

Mix

SEX

Spayed Female

AGE

5

WEIGHT

61

INTERPRETED BY

Beth Johnson, DVM,
DACVIM (SAIM)

IMAGING PERFORMED BY

Jenn

HOSPITAL NAME

Rockaway AH

REFERRING VET

Dr. Maniar

INVOICE

35947

DATE

2/24/26

PRESENTING CLINICAL SIGNS

History: drooling, lethargy

Abnormal PE/Chem/CBC/UA Results: WNL

ULTRASONOGRAPHIC EXAMINATION OF THE ABDOMEN

Urinary System

Urinary bladder is adequately distended with anechoic contents. No masses, inflammatory changes, echogenic sediment or cystoliths are observed. The urinary bladder, trigone and visible pelvic urethra are normal in thickness with a smooth mucosal surface.

Left kidney is normal in size (5.91 cm), shape and echogenicity. It has smooth peripheral margination. There is a normal 1:3 cortex to medulla ratio with appropriate corticomedullary distinction. There is no evidence of pyelectasia, mineral or infarcts observed.

Right kidney is normal in size (5.68 cm), shape and echogenicity. It has smooth peripheral margination. There is a normal 1:3 cortex to medulla ratio with appropriate corticomedullary distinction. There is no evidence of pyelectasia, mineral or infarcts observed.

Adrenal Glands

Left adrenal gland is small (flattened contour). Corticomedullary structure is unremarkable. Visible surrounding vasculature appears normal. The left adrenal gland measures 0.25 cm at the cranial pole and 0.26 cm at the caudal pole.

Right adrenal gland is unable to be visualized in these images.

Spleen

Spleen is subjectively normal in size with a normal smooth capsular contour. Parenchyma is appropriately finely textured and homogenous with normal echogenicity relative to surrounding tissue (hyperechoic to liver). No focal nodules or masses are observed. Splenic vasculature appears normal.

Liver

Liver is subjectively normal in size with normal smooth curvilinear peripheral contour. Parenchyma is appropriately hypoechoic to the spleen in echogenicity and appropriately mildly coarse and homogenous in echotexture. No focal lesions are observed. Visible vasculature and biliary tree appear normal without distension or congestion.

Gallbladder is non-distended in size. The wall is smooth without visible thickening. Luminal contents are primarily anechoic. There is no evidence of cystic or common bile duct dilation.

Gastrointestinal

The visible stomach wall is normal in thickness and layering. The lumen of the stomach is empty with no evidence of obstruction, foreign material or infiltrative disease. Pyloric outflow tract appears patent.



PATIENT

Dallas Kisiellus

The visible small intestines are normal in wall thickness and layering. Small intestinal motility appears adequate (1-3 contractions per min). The lumen of the small intestine is empty with no evidence of obstruction, foreign material or infiltrative disease.

SPECIES

Canine

The visible colon is normal in wall thickness (< 0.2 cm) and layering. Contents are consistent with normal formed feces and gas.

Pancreas

BREED

Mix

The pancreas that is observed appears appropriately isoechoic to surrounding omental fat. Visible capsule is smooth and normal in contour. Visible pancreatic parenchyma is homogenous and unremarkable. There is no visible pancreatic duct dilation. There is no evidence of active peripancreatic inflammation.

SEX

Spayed Female

Free Abdomen

AGE

5

There is no visible free peritoneal effusion noted in these images.

There is no apparent pathologic lymphadenopathy noted in these images.

WEIGHT

61

ULTRASONOGRAPHIC FINDINGS

- Flat adrenal glands- This can be a normal patient variant and/or a sign of exogenous cortisol administration. If exogenous steroids are not being administered, hypoadrenocorticism (either relative or absolute) should be considered.

INTERPRETED BY

Beth Johnson, DVM,
DACVIM (SAIM)

INTERPRETATION OF THE FINDINGS & FURTHER RECOMMENDATIONS

A baseline cortisol is recommended. If baseline cortisol is less than 2, a full ACTH stimulation test is recommended to rule out hypoadrenocorticism.

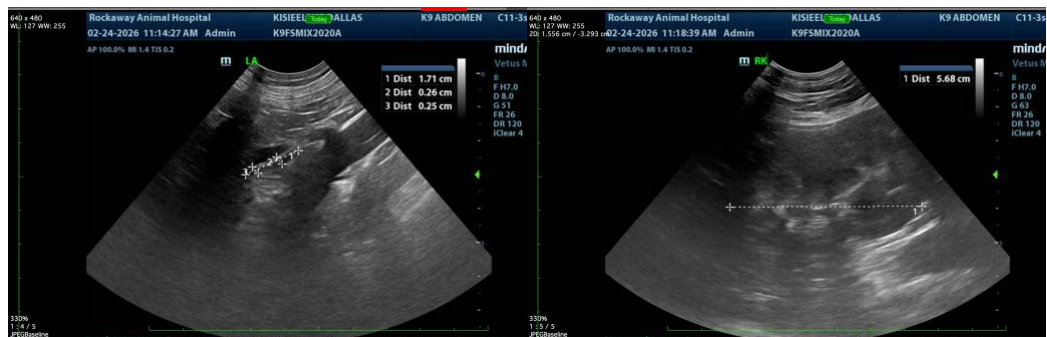
IMAGING PERFORMED BY

Jenn

Other than supportive/symptomatic medical management of clinical signs, including empirical medical management for probable nausea, resulting in the drooling, additional therapeutic and diagnostic recommendations are largely dependent on results of the above.

HOSPITAL NAME

Rockaway AH



REFERRING VET

Dr. Maniar

INVOICE

35947

DATE

2/24/26



PATIENT

Dallas Kisiellus

SPECIES

Canine

BREED

Mix

SEX

Spayed Female

AGE

5

WEIGHT

61

INTERPRETED BY

Beth Johnson, DVM,
DACVIM (SAIM)

IMAGING PERFORMED BY

Jenn

HOSPITAL NAME

Rockaway AH

REFERRING VET

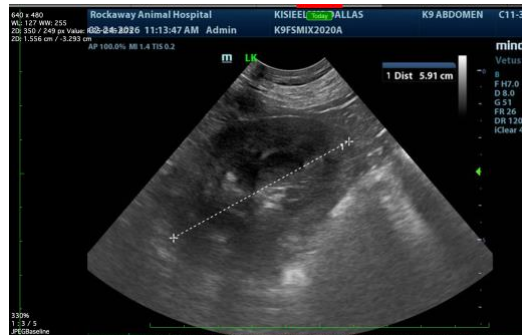Dr. Maniar

INVOICE

35947

DATE

2/24/26



The information and recommendations provided are based on the images presented by the referring veterinarian/sonographer. No evaluation can be communicated regarding pathology that was not visible in the image/video clips provided.

Thank you for this referral. If the clinical or image interpretation does not parallel your findings or if I can be of any further assistance please contact me.

Beth Johnson, DVM DACVIM

info@sonopath.com