



PATIENT

Dakota Foulke

SPECIES

Canine

BREED

Akita

SEX

SF

AGE

8.8 years

WEIGHT

99.7 lbs

INTERPRETED BY

Beth Johnson, DVM
DACVIM

IMAGING PERFORMED BY

Dr. Kristen Carpenter

HOSPITAL NAME

Pennridge Animal
Hospital

REFERRING VET

Dr. Alex Peters

INVOICE

11354

DATE

2/24/2026

PRESENTING CLINICAL SIGNS

- Hx: Patient sedated with Butorphanol.
- Patient presented 2/17/25 for a 2-week hx of inappetence and labored breathing/tachypnea. She was also uncomfortable on abd palpation. No heart murmur or arrhythmias noted. Bloodwork and chest/abd rads were performed and patient set up for thoracocentesis today. Cardiac silhouette and pulm vasculature WNL on rads.
- Chest tap performed today and 550 mL light yellow fluid removed. AFAST of the heart revealed no obvious masses and no clear chamber enlargement.
- AUS performed due to scant abdominal effusion noted on AFAST in the abdomen.
- Chronic meds - carprofen PRN, not used recently.

Abnormal PE/Chem/CBC/UA Results: 2/17/26: Thoracic rads: Mild - Mod pleural effusion, pleural fissure lines. Cardiac silhouette WNL and pulm vasculature WNL. Abd rads: Scant abd effusion suspected, slight reduced serosal detail. - 2/17/26: CBC: HCT 57%, Platelets 123,000. Chem - WNL. CPL normal. - 2/24/26: Fluid analysis: Clear to Light Yellow. SG: 1.025, TP 3.2. Line prep: 2-3 small lymphocytes per HPF, rare non-degenerative neutrophils. -2/24/26: Post tap chest radiographs: No obvious metastatic disease noted, cranial ventral chest/thoracic inlet can not be evaluated for masses/LN elevations d/t residual pleural effusion.

ULTRASONOGRAPHIC EXAMINATION OF THE ABDOMEN

Urinary System

The urinary bladder is adequately distended with anechoic contents. No masses, inflammatory changes, echogenic sediment or cystoliths are observed. The urinary bladder, trigone and visible pelvic urethra are normal in thickness with a smooth mucosal surface.

The right kidney is normal is size (5.5 cm), shape and echogenicity. It has smooth peripheral margination. There is a normal 1:3 cortex to medulla ratio with appropriate corticomedullary distinction. There is no evidence of pyelectasia, mineral or infarcts observed.

The left kidney is normal is size (5.4 cm), shape and echogenicity. It has smooth peripheral margination. There is a normal 1:3 cortex to medulla ratio with appropriate corticomedullary distinction. There is no evidence of pyelectasia, mineral or infarcts observed.

Adrenal Glands

The right adrenal gland is normal in size (1.2 cm at cranial pole and 0.59 cm at caudal pole), shape and overall architecture, echogenicity and echotexture. Visible surrounding vasculature appears normal. A hyperechoic nodule is noted in the cranial pole. Nodule does not disrupt normal shape and/or architecture. The nodule measures 0.9 cm in diameter.

The left adrenal gland is normal in size (0.54 cm at cranial pole and 0.67 cm at caudal pole), shape and overall architecture, echogenicity and echotexture. Visible surrounding vasculature appears normal.

Spleen

Spleen is subjectively large in size with a normal smooth capsular contour. Parenchyma is appropriately finely textured and homogenous with normal echogenicity relative to surrounding tissue



PATIENT

Dakota Foulke

SPECIES

Canine

BREED

Akita

SEX

SF

AGE

8.8 years

WEIGHT

99.7 lbs

INTERPRETED BY

Beth Johnson, DVM
DACVIM

IMAGING PERFORMED BY

Dr. Kristen Carpenter

HOSPITAL NAME

Pennridge Animal
Hospital

REFERRING VET

Dr. Alex Peters

INVOICE

11354

DATE

2/24/2026

(hyperechoic to liver). No focal nodules or masses are observed. Splenic vasculature appears normal. The spleen is folded upon itself, which is a positional non-pathologic variant.

Liver

The liver is subjectively normal in size with normal smooth curvilinear peripheral contour. Parenchyma is appropriately hypoechoic to the spleen in echogenicity and appropriately mildly coarse and homogenous in echotexture. No focal lesions are observed. Visible vasculature and biliary tree appear normal without distension or congestion.

The gallbladder is non-distended in size. The wall is smooth without visible thickening. Luminal contents are primarily anechoic. There is no evidence of cystic or common bile duct dilation.

Gastrointestinal

The visible stomach wall is normal in thickness and layering. The lumen of the stomach is empty with no evidence of obstruction, foreign material or infiltrative disease. Pyloric outflow tract appears patent.

The visible small intestines are normal in wall thickness and layering. Small intestinal motility appears adequate (1-3 contractions per min). The lumen of the small intestine is empty with no evidence of obstruction, foreign material or infiltrative disease.

The visible colon is normal in wall thickness (< 0.2 cm) and layering. Contents are consistent with normal formed feces and gas.

Pancreas

The observed pancreas is prominent (enlarged) in size, hypoechoic to surrounding tissue and irregular in shape with a swollen undulating contour. Enhanced hyperechoic ill-defined surrounding fat is noted.

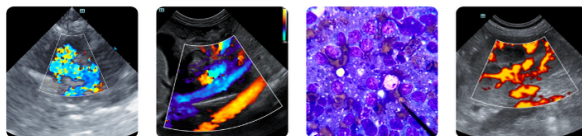
Free Abdomen

There is trace free fluid noted within the abdomen, as is diffusely enhanced hyperechoic mesenteric fat. Additionally, pleural effusion is noted at the edge of the cranial abdominal images. No pericardial effusion is observed. If cardiac function evaluation is desired, a full echocardiogram is recommended.

There is no apparent pathologic lymphadenopathy noted in these images.

PRIMARY FINDINGS

- Suspect mild to moderate acute pancreatitis. Having said that, the free fluid and enhanced mesenteric fat, especially the fat, are diffusely noted throughout the abdomen and not focally consistent with typical pancreatitis pattern.
- Emerging, but no definitively visible bowel disease or other sources of inflammatory changes are considered possible.
- Mild splenomegaly– can be associated with congestion caused by sedation (if sedated) but can also be associated with diffuse infiltrative disease. Both benign conditions such as extramedullary hematopoiesis, lymphoid hyperplasia, as well as infiltrative neoplastic diseases such as round cell neoplasia should be considered.



PATIENT

Dakota Foulke

SPECIES

Canine

BREED

Akita

SEX

SF

AGE

8.8 years

WEIGHT

99.7 lbs

SECONDARY FINDINGS

- Hyperechoic adrenal nodule in the cranial pole of the right adrenal gland – Differentials include primary adrenal cortical adenoma or adenocarcinoma, pheochromocytoma, myelolipoma, adrenal hyperplasia secondary to pituitary disease or metastatic disease. Ultrasound alone cannot differentiate between functional and non-functional nodules and/or between benign and malignant disease. Small nodules without other evidence of abdominal disease (to suggest metastatic disease) and/or clinical signs (to suggest adrenal disease) are most often incidental and should be monitored.

INTERPRETATION OF THE FINDINGS & FURTHER RECOMMENDATIONS

A gastrointestinal malabsorption panel (including cobalamin, folate, TLI and PLI) to Texas A&M GI Laboratory is recommended for further evaluation of GI and pancreatic function.

Other than suspected pancreatitis, however there is not a definitive ultrasonographically visible intraabdominal explanation or source of the bicavitary effusion, and the appearance of the pancreas does not, in my opinion, appear to be severe enough to be the primary underlying cause. Therefore, further evaluation of the fluid and/or advanced imaging of both the thorax and/or abdomen i.e. contrast CT scans may be helpful.

Other than supportive/symptomatic medical management of clinical signs, further diagnostic treatment recommendations are largely dependent on results of the above.

INTERPRETED BY

Beth Johnson, DVM
DACVIM

IMAGING PERFORMED BY

Dr. Kristen Carpenter

HOSPITAL NAME

Pennridge Animal Hospital

REFERRING VET

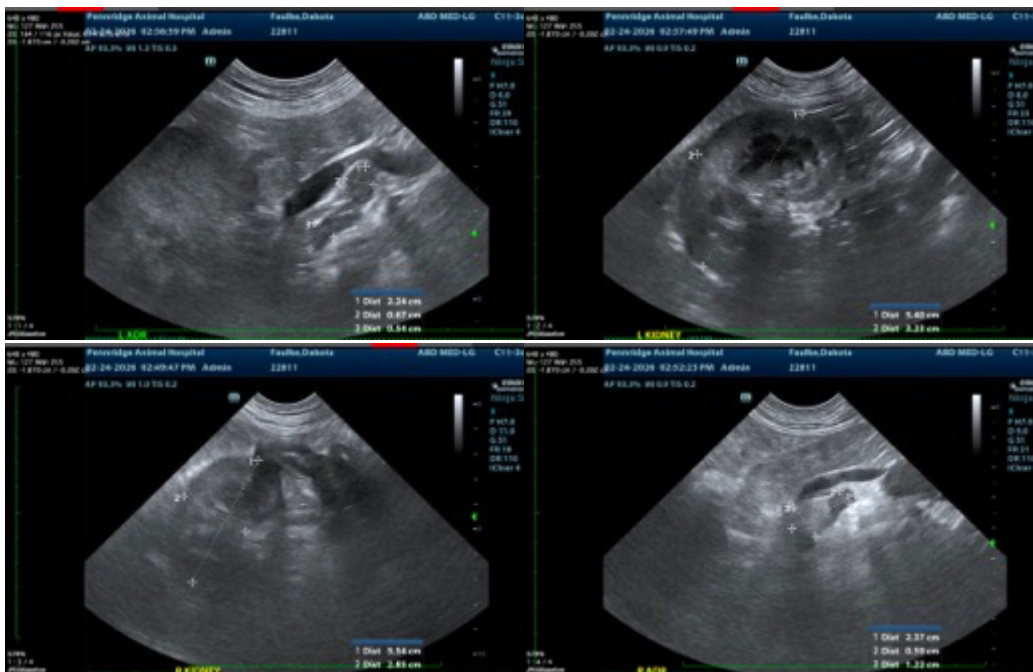
Dr. Alex Peters

INVOICE

11354

DATE

2/24/2026





PATIENT

Dakota Foulke

SPECIES

Canine

BREED

Akita

SEX

SF

AGE

8.8 years

WEIGHT

99.7 lbs

INTERPRETED BY

Beth Johnson, DVM
DACVIM

IMAGING PERFORMED BY

Dr. Kristen Carpenter

HOSPITAL NAME

Pennridge Animal
Hospital

REFERRING VET

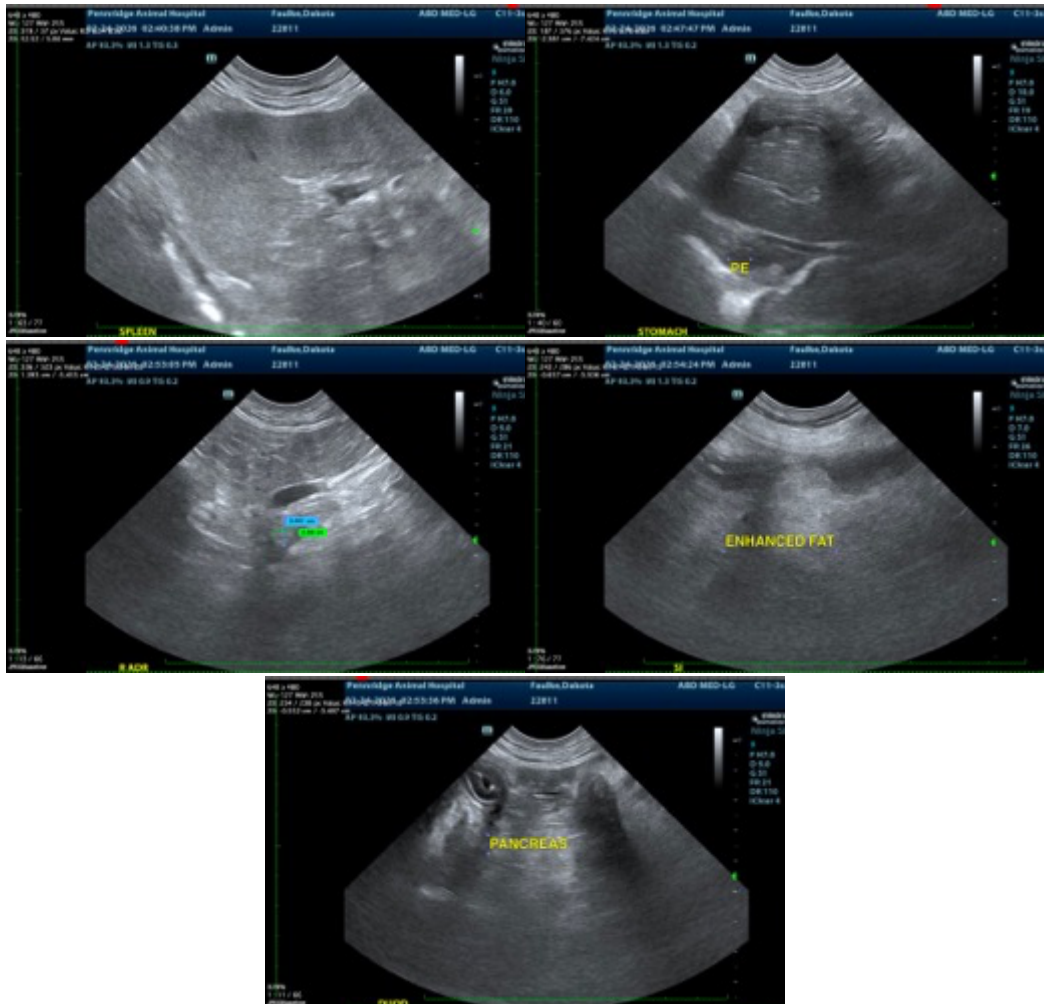Dr. Alex Peters

INVOICE

11354

DATE

2/24/2026



The information and recommendations provided are based on the images presented by the referring veterinarian/sonographer. No evaluation can be communicated regarding pathology that was not visible in the image/video clips provided.

Thank you for this referral. If the clinical or image interpretation does not parallel your findings or if I can be of any further assistance please contact me.

Beth Johnson, DVM, DACVIM
info@sonopath.com