



**DATE PRESENTING CLINICAL SIGNS**

2/24/26

**Patient History:** Indoor cat. Poor appetite the past month. Lethargic, being reclusive. No changes in home life or food. Not vomiting. Hx of left ventricular focal septal bulge, last year echo (no LAE)

**PATIENT**

PE : 3 lb weight loss, Temp 103.5F, poor skin elasticity, no pain on palpation of abdomen, subtle icterus of temples, sclera, caudal palate. Grade III systolic murmur left side

Crimson Hoffman

**SPECIES**

**Current Medications:** IV fluids NaCl at 1 1/2 times maintenance, Convenia -.45 ml SQ, Prednisolone 5 mg 1 1/2 tab PO BiD

Feline

**Labwork Results:** Labwork attached, reported as: Globulin 5.5, Na and Cl low, Hct 27.7%, platelets 71K (ran test twice on 2 different samples, 2nd sample had 83K). T bili 0.7 mg/dl (towards hi end of ref range). Radiographs - chest wnl - abdomen - prominent rugal folds, area behind stomach on lateral view poor detail.

**BREED**

**Date of Previous IntraPet Ultrasound:** No previous.

DSH

**Sedation:** Not required to complete full diagnostic ultrasound.

**Stat Report:** Not requested.

**Imaging Performed by:** Stephanie Warga RDCS, RVT.

**SEX**

**ULTRASONOGRAPHIC EXAMINATION OF THE ABDOMEN**

Neutered Male

**Urinary System**

**AGE**

Urinary bladder is adequately distended. It has a normal uniform wall thickness. Contents include primarily anechoic fluid with a large amount of echogenic non-shadowing debris, most consistent with exfoliated cells, crystals, mucous and/or small blood clots likely combined with incidental suspended lipid. Both sterile inflammation as well as urinary tract infection can present with echogenic debris. No masses or definitive cystoliths are observed. The trigone and visible pelvic urethra are normal in thickness with a smooth mucosal surface.

12/30/14

**WEIGHT**

8.5 lbs

**INTERPRETED BY**

The right kidney is normal is size (3.79 cm), shape and echogenicity. It has smooth peripheral margination. There is a normal 1:3 cortex to medulla ratio with appropriate corticomedullary distinction. There is no evidence of pyelectasia, mineral or infarcts observed.

Beth Johnson, DVM  
DACVIM

**HOSPITAL NAME**

The left kidney is normal is size (3.77 cm), shape and echogenicity. It has smooth peripheral margination. There is a normal 1:3 cortex to medulla ratio with appropriate corticomedullary distinction. There is no evidence of pyelectasia, mineral or infarcts observed.

Chadwell Animal  
Hospital

**Adrenal Glands**

**REFERRING VET**

The right adrenal gland is normal in size (0.36 cm), shape and overall architecture, echogenicity and echotexture. Visible surrounding vasculature appears normal.

Dr. Schaupp

The left adrenal gland is normal in size (0.44 cm), shape and overall architecture, echogenicity and echotexture. Visible surrounding vasculature appears normal.

**INVOICE**

73238

**Spleen**

The spleen is subjectively normal in size with a normal smooth capsular contour. Parenchyma is appropriately finely textured and homogenous with normal echogenicity relative to surrounding tissue (hyperechoic to liver). No focal nodules or masses are observed. Splenic vasculature appears normal.

## ***Liver***

The liver is subjectively normal in size with normal smooth curvilinear peripheral contour. Parenchyma is appropriately hypoechoic to the spleen in echogenicity and appropriately mildly coarse and homogenous in echotexture. No focal lesions are observed. Visible vasculature and biliary tree appear normal without distension or congestion.

Gallbladder is moderately distended with anechoic bile as well as suspended and gravity dependent echogenic debris. The wall is smooth without visible thickening. There is no evidence of cystic or CBD dilation. There is no evidence of effusion or inflammation.

## ***Gastrointestinal***

The visible stomach wall is normal in thickness and layering. The lumen of the stomach is empty with no evidence of obstruction, foreign material or infiltrative disease. Pyloric outflow tract appears patent.

The visible small intestines are normal in wall thickness and layering. Small intestinal motility appears adequate (1-3 contractions per min). The lumen of the small intestine is empty with no evidence of obstruction, foreign material or infiltrative disease.

The colon beginning just after the ileocecolic junction/transverse colon is thick, measuring between 0.47 cm up to 0.68 cm thick with an overall coarse hypoechoic wall and loss of layering in the area. The descending colon returns to more normal appearance. The lumen is empty.

## ***Pancreas***

Pancreas is prominent (enlarged) in size, hypoechoic to surrounding tissue and has a mildly irregular undulating contour. Parenchyma is coarse with mixed echogenic remodeling noted. No pancreatic duct dilation is noted.

## ***Free Abdomen***

There are scant/trace pockets of free fluid between liver lobes.

Mesenteric lymph nodes are prominent in size with swollen capsular contour. Normal elongated shape (length to width ratio) is maintained. There is no loss of parenchymal detail.

## **ULTRASONOGRAPHIC FINDINGS**

- The thick transverse colon could represent infiltrative neoplasia such as round cell neoplasia i.e., lymphoma versus other given the suspected emerging loss of layering. Having said that, a benign infectious, parasitic, dietary related, other benign inflammatory etiology cannot be ruled out without tissue sampling.
- Very mild reactive mesenteric lymph nodes – infiltrative neoplastic disease cannot be ruled out but is considered less likely.
- The scant/trace free fluid is of unknown origin. Differentials (unless already ruled out) could include increased hydrostatic pressure (cardiac disease and/or vascular or lymph blockage), decreased

oncotic pressure (low albumin), vasculitis, paraneoplastic fluid, rupture/leakage of/from an organ (GI, GB, UB, other), blood (hemoabdomen), other.

- Concurrent chronic low-grade smoldering pancreatitis can't be ruled out and should be suspected in the face of appropriate clinical signs.
- Mild gallbladder debris - Cholecystic debris is of unknown clinical significance. It can be seen with biliary stasis from fasting or illness, however, it can also be associated with hepatobiliary disease in cats and should be interpreted in combination with clinical signs such as nausea, inappetence, cranial abdominal discomfort and/or laboratory changes such as increased ALP and/or increased Tbili.
- Moderate amount of echogenic urinary bladder debris.

### INTERPRETATION OF THE FINDINGS & FURTHER RECOMMENDATIONS

I suspect that the primary contributing factor to this patient's reported clinical signs is an infiltrative process, either benign or malignant, affecting the colon. Therefore, colonic sampling in the form of a colonoscopy is recommended, if possible.

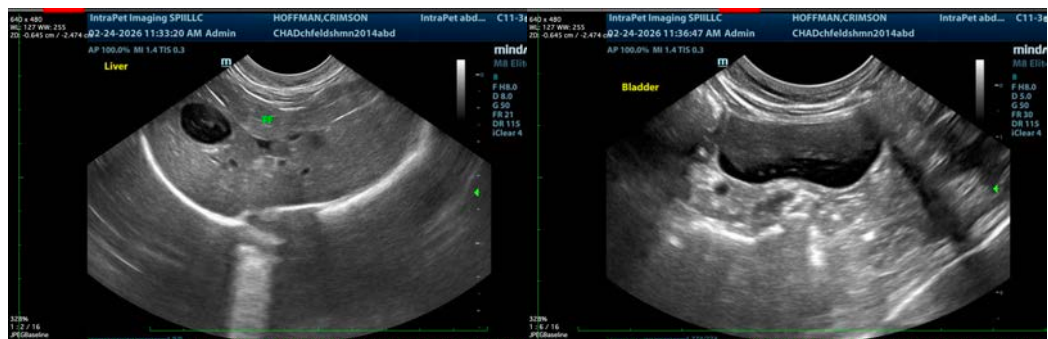
In the meantime, additionally a routine fecal/giardia exam is recommended if not recently evaluated.

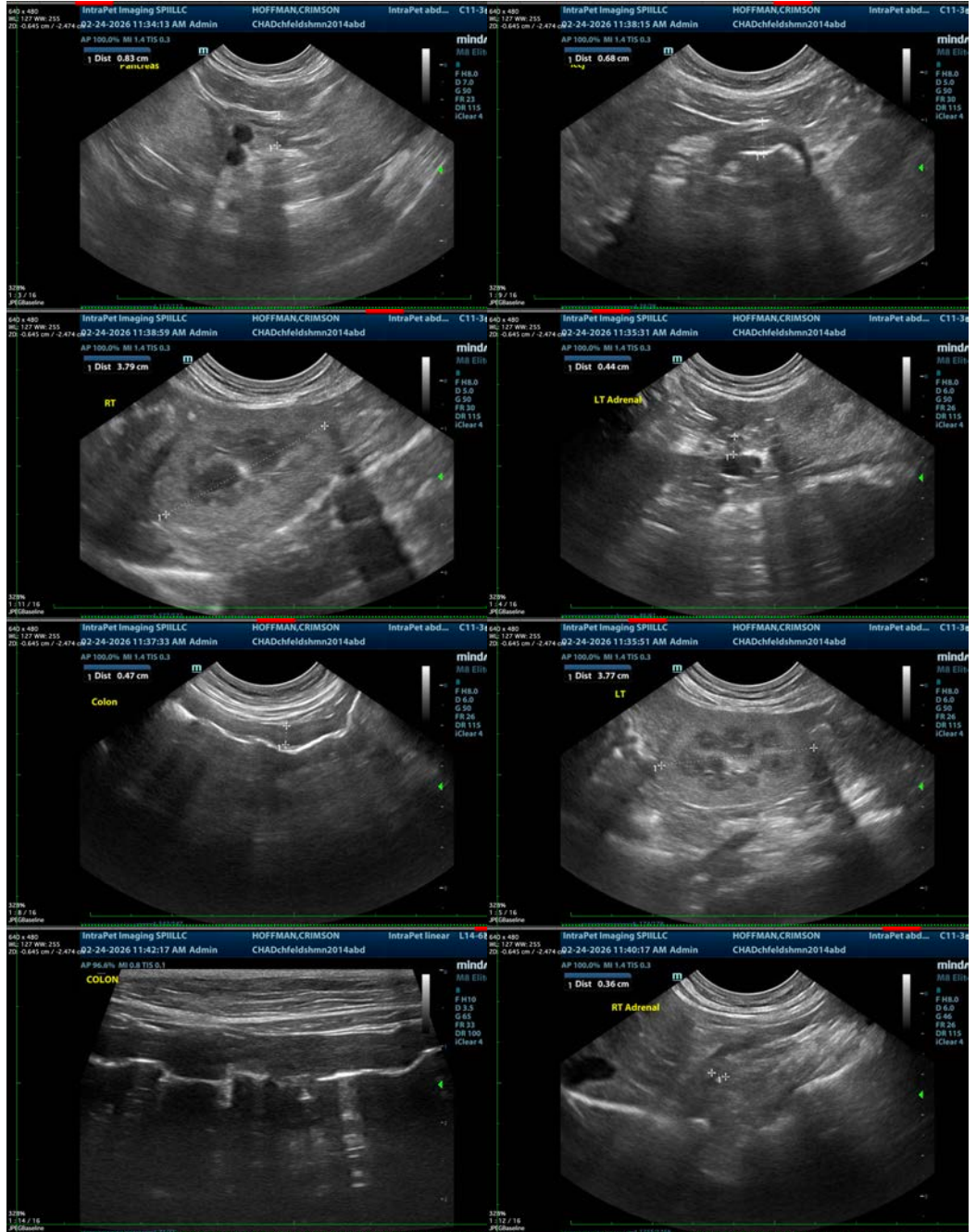
A gastrointestinal malabsorption panel (including cobalamin, folate, TLI and PLI) to Texas A&M GI Laboratory is recommended for further evaluation of GI and pancreatic function.

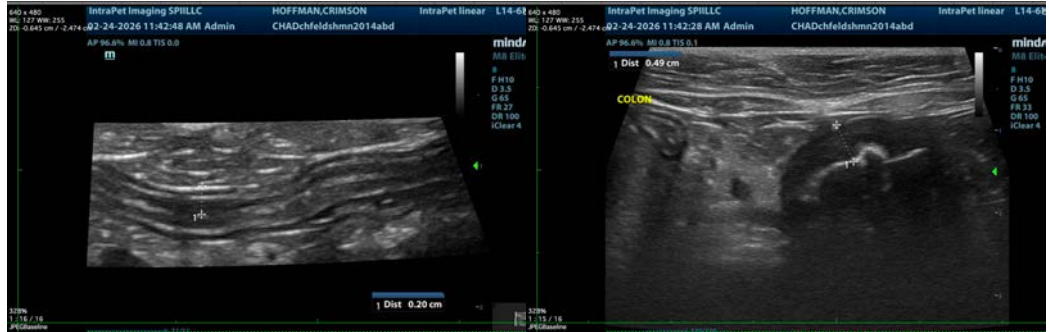A fecal enteropathogen PCR panel to Texas A&M GI Laboratory could be considered for further evaluation of possible infectious disease. Contact lab for recommendations on how long to discontinue antibiotics (if indicated) prior to obtaining a stool sample for submission.

There is not a definitive ultrasonographically visible intraabdominal explanation for patient's reported anemia. However, a slow chronic gastrointestinal bleed could be present. Therefore, in the meantime, in addition to supportive/symptomatic medical management of clinical signs, empirical antacid therapy +/- sucralfate and empirical deworming with a 5-day course of Panacur could all be considered.

Patient's platelets, given signalment, are most likely clumped and should be confirmed with a manual count and/or pathology review prior to pursuit of true thrombocytopenia.







The information and recommendations provided are based on the images presented by the referring veterinarian/sonographer. No evaluation can be communicated regarding pathology that was not visible in the image/video clips provided.

Thank you for this referral. If the clinical or image interpretation does not parallel your findings or if I can be of any further assistance please contact me.

**Beth Johnson, DVM, DACVIM**  
info@sonopath.com