



PATIENT PRESENTING CLINICAL SIGNS

Jeter Fink Patient presents out of concern for possible foreign body vs. other causing intermittent vomiting within an hour or so after eating for 5 days. No change in diet. Abdominal rads were suspicious. No current meds.

SPECIES

Feline

ULTRASONOGRAPHIC EXAMINATION OF THE ABDOMEN

BREED

Urinary System

DSH

Urinary bladder is adequately distended. It has a normal uniform wall thickness. Contents include primarily anechoic fluid with occasional echogenic non-shadowing debris, most consistent with incidental suspended lipid in a cat, possibly combined with exfoliated cells, mucous and/or small blood clots. Both sterile inflammation as well as urinary tract infection can also present with echogenic debris. No masses or cystoliths are observed. The trigone and visible pelvic urethra are normal in thickness with a smooth mucosal surface.

SEX

Neutered Male

AGE

7 Years

The right kidney is normal in size (4.06 cm), shape and echogenicity. It has smooth peripheral margination. There is a normal 1:3 cortex to medulla ratio with appropriate corticomedullary distinction. There is no evidence of pyelectasia, mineral or infarcts observed.

WEIGHT

10.9 Pounds

The left kidney is normal in size (3.6 cm), shape and echogenicity. It has smooth peripheral margination. There is a normal 1:3 cortex to medulla ratio with appropriate corticomedullary distinction. There is no evidence of pyelectasia, mineral or infarcts observed.

INTERPRETED BY

Adrenal Glands

Beth Johnson, DVM
DACVIM

The area of the right adrenal gland is examined without evident right adrenal gland pathology.

The left adrenal gland is normal in size (0.29 cm), shape and contour. Corticomedullary structure is unremarkable. Visible surrounding vasculature appears normal.

IMAGING PERFORMED BY

Spleen

Kelly Vazquez

The spleen is subjectively normal in size with a normal smooth capsular contour. Parenchyma is appropriately finely textured and homogenous with normal echogenicity relative to surrounding tissue (hyperechoic to liver). No focal nodules or masses are observed. Splenic vasculature appears normal.

HOSPITAL NAME

Liver

Westwood Regional

The liver is subjectively normal in size with normal smooth curvilinear peripheral contour. Parenchyma is appropriately hypoechoic to the spleen in echogenicity and appropriately mildly coarse and homogenous in echotexture. No focal lesions are observed. Visible vasculature and biliary tree appear normal without distension or congestion.

REFERRING VET

Dr. Giammanco

INVOICE

The gallbladder is non-distended in size. The wall is smooth without visible thickening. Luminal contents are primarily anechoic. There is no evidence of cystic or common bile duct dilation.

45475

DATE

Gastrointestinal

2/24/23

The stomach wall is normal in thickness (canine < 0.5 cm and feline < 0.4 cm) and layering. The lumen of the stomach is empty with no evidence of obstruction, foreign material or infiltrative disease. Pyloric outflow tract appears patent.

The visible small intestine demonstrates areas of mildly thick muscularis layer relative to mucosa (disruption of the normal 1:3 muscularis:mucosa ratio). Small intestinal submucosa is slightly irregular, thick and hyperechoic, without evident loss of layering appreciated. The lumen is mildly distended with



PATIENT

Jeter Fink

echogenic non-shadowing luminal contents and gas consistent with normal ingesta. There is no evidence of obstruction or foreign material noted.

SPECIES

Feline

The visible colon is normal in wall thickness (< 0.2 cm) and layering. Contents are consistent with normal formed feces and gas.

Pancreas

BREED

DSH

The pancreatic parenchyma is appropriately isoechoic to surrounding tissue. Visible capsule is smooth and normal in contour. There is no visible pancreatic duct dilation. There is no evidence of active peripancreatic inflammation.

SEX

Neutered Male

Free Abdomen

There is no evidence of free peritoneal effusion noted in these images.

AGE

7 Years

There is no apparent lymphadenopathy noted in these images.

WEIGHT

10.9 Pounds

PRIMARY FINDINGS

- **Mild inflammatory bowel disease (IBD) pattern** – Thick muscularis has been reported with infiltrative bowel disease including both benign inflammatory disease as well as infiltrative neoplasia such as lymphoma. No aggressive lymphadenopathy, loss of layering, etc. is noted to make lymphoma more probable, but lymphoma cannot be definitively ruled out without tissue sampling.
- **Full stomach** – Most consistent with normal ingesta. Foreign material cannot be definitively ruled out but is considered less likely.

INTERPRETED BY

Beth Johnson, DVM
DACVIM

SECONDARY FINDINGS

- Urinary bladder debris

IMAGING PERFORMED BY

Kelly Vazquez

INTERPRETATION OF THE FINDINGS & FURTHER RECOMMENDATIONS

This patient's reported chronic vomiting, based on these images, appears likely more related to an emerging diffuse infiltrative bowel disease versus and obstruction. Recommendation include:

HOSPITAL NAME

Westwood Regional

A gastrointestinal malabsorption panel (including cobalamin, folate, TLI and PLI) to Texas A&M GI Laboratory is recommended for further evaluation of GI and pancreatic function.

REFERRING VET

Dr. Giammanco

While providing supportive care, additional 12-24 hours of fasting is recommended with recheck imaging if vomiting persists for further evaluation of ideally an empty GI tract if possible.

INVOICE

45475

Ultimately, biopsies of the gastrointestinal tract may be necessary to definitively diagnose and therefore treat the suspected infiltrative bowel disease. In the meantime, empirical deworming with a 5-day course of Panacur is recommended, as is a diet change, if tolerated, beginning with a hydrolyzed protein diet and continuing based on trial-and-error response, knowing that some patients respond better to one brand versus another, so sometimes several diet trials are necessary.

DATE

2/24/23

Additionally, if not recently evaluated, a urinalysis and, if indicated based on urinalysis results, urine culture are recommended. If protein is present in an otherwise quiet sediment, protein quantification with a urine protein to creatinine ration is recommended.



PATIENT

Jeter Fink

SPECIES

Feline

BREED

DSH

SEX

Neutered Male

AGE

7 Years

WEIGHT

10.9 Pounds

INTERPRETED BY

Beth Johnson, DVM
DACVIM

IMAGING PERFORMED BY

Kelly Vazquez

HOSPITAL NAME

Westwood Regional

REFERRING VET

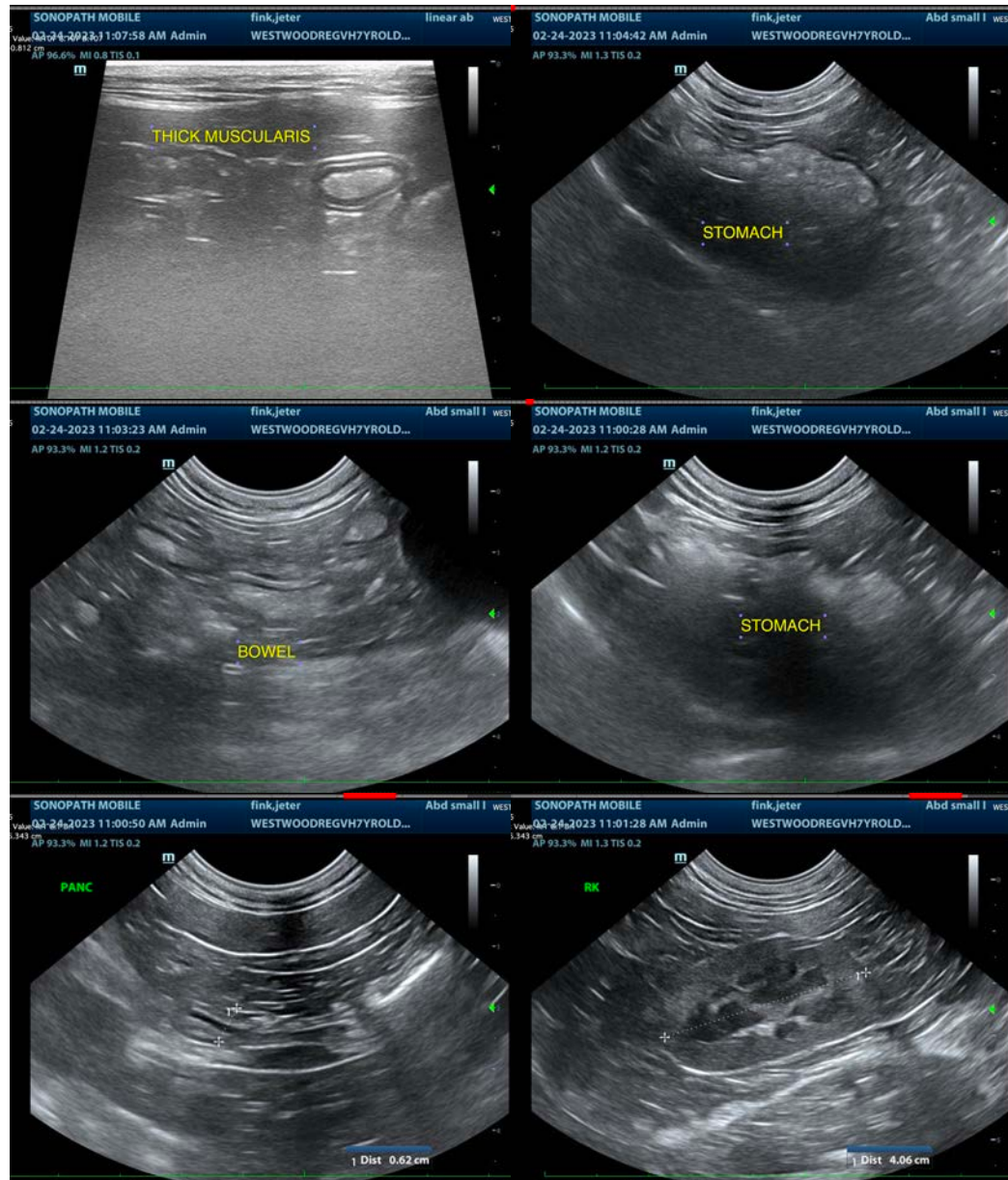
Dr. Giammanco

INVOICE

45475

DATE

2/24/23





PATIENT

Jeter Fink

SPECIES

Feline

BREED

DSH

SEX

Neutered Male

AGE

7 Years

WEIGHT

10.9 Pounds

INTERPRETED BY

Beth Johnson, DVM
DACVIM

IMAGING PERFORMED BY

Kelly Vazquez

HOSPITAL NAME

Westwood Regional

REFERRING VET

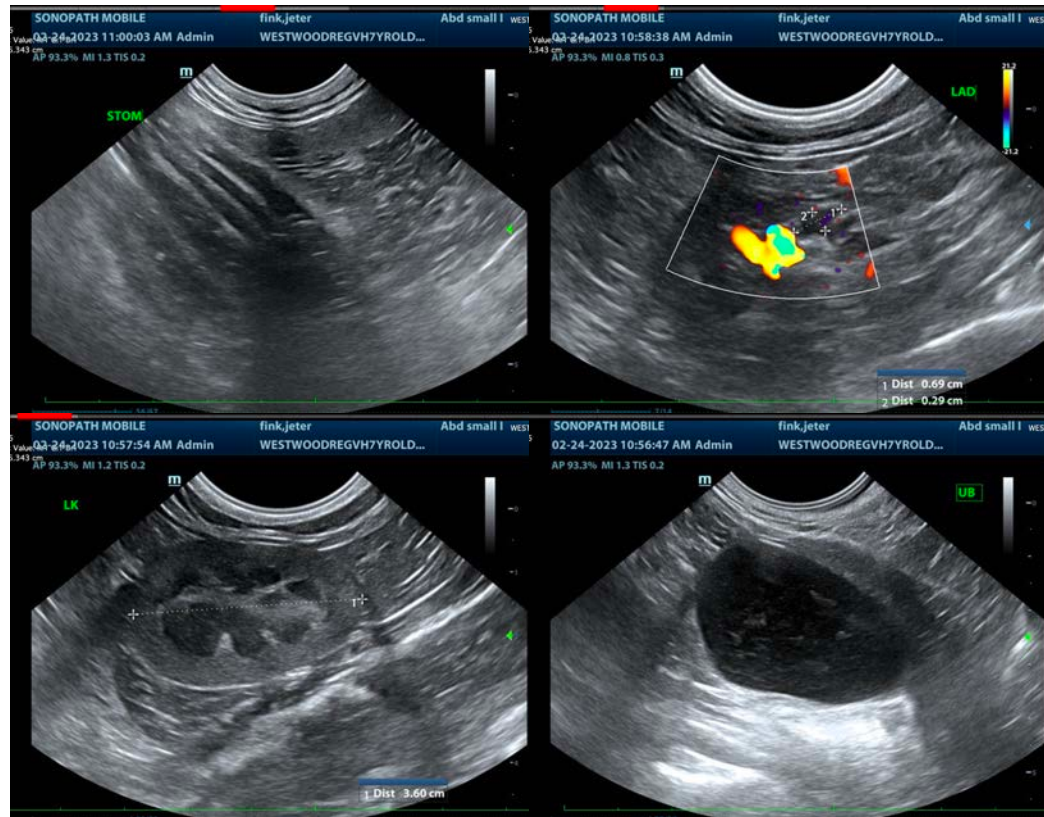
Dr. Giammanco

INVOICE

45475

DATE

2/24/23



The information and recommendations provided are based on the images presented by the referring veterinarian/sonographer. No evaluation can be communicated regarding pathology that was not visible in the image/video clips provided.

Thank you for this referral. If the clinical or image interpretation does not parallel your findings or if I can be of any further assistance please contact me.

Beth Johnson, DVM, DACVIM
Beth.Johnson@sonopath.com