

PATIENT PRESENTING CLINICAL SIGNS

PATIENT Domino Moran
SPECIES Feline
BREED DSH
SEX Intact Male
AGE 7 Years
WEIGHT 4.88 kg

Presented Feb 3/23 for 2nd opinion for jaundiced, anorexia, weight loss From previous clinic: Elevated ALP+++ , anorexia and weight loss- Mild anemia and Mild neutrophilia at the time. Fip tested. Had a history of pancreatitis previously and vomits dry food. Treated with liver supplement and clavaseptin on diagnosis of cholangiohepatitis- Urea is low (3.0)- liver failure vs pu/pd vs anorexia. Recent small panel- Improved ALP, no bilirubin tested, potassium low and urea is now lower Blood work done Feb 3/2023:- Bilirubin+++ with mild increase in ALP and normal ALT and AST- FPLI normal and Viral screen negative- Albumin low normal, urea low (Liver failure?) WBC and RBC normal- R/O biliary obstruction- cholangiohepatitis (neutrophilic, lymphocytic) vs primary liver? vs fatty liver, PCV is low normal so less likely to be prehepatic. Current Medications Buprenorphine 0.3mg/ml : 0.3ml BID for pain

ULTRASONOGRAPHIC EXAMINATION OF THE ABDOMEN

Urinary System

Urinary bladder is adequately distended. It has a normal uniform wall thickness. Contents include primarily anechoic fluid with occasional echogenic non-shadowing debris, most consistent with incidental suspended lipid in a cat, possibly combined with exfoliated cells, mucous and/or small blood clots. Both sterile inflammation as well as urinary tract infection can also present with echogenic debris. No masses or cystoliths are observed. The trigone and visible pelvic urethra are normal in thickness with a smooth mucosal surface.

The right kidney is normal in size (4.15 cm), shape and echogenicity. It has smooth peripheral margination. There is a normal 1:3 cortex to medulla ratio with appropriate corticomedullary distinction. There is no evidence of pyelectasia, mineral or infarcts observed.

The left kidney is normal in size (3.86 cm), shape and echogenicity. It has smooth peripheral margination. There is a normal 1:3 cortex to medulla ratio with appropriate corticomedullary distinction. There is no evidence of pyelectasia, mineral or infarcts observed.

Adrenal Glands

The right adrenal gland is normal in size (0.24 cm), shape and contour. Corticomedullary structure is unremarkable. Visible surrounding vasculature appears normal.

The left adrenal gland is normal in size (0.48 cm), shape and contour. Corticomedullary structure is unremarkable. Visible surrounding vasculature appears normal.

Spleen

The spleen is subjectively normal in size with a normal smooth capsular contour. Parenchyma is appropriately finely textured and homogenous with normal echogenicity relative to surrounding tissue (hyperechoic to liver). No focal nodules or masses are observed. Splenic vasculature appears normal.

Liver

The liver is subjectively normal in size with normal smooth curvilinear peripheral contour. Parenchyma is appropriately hypoechoic to the spleen in echogenicity and appropriately mildly coarse and homogenous in echotexture. No focal lesions are observed. Visible vasculature and biliary tree appear normal without distension or congestion.

The gallbladder is non-distended in size. The wall is smooth without visible thickening. Luminal contents are primarily anechoic. There is no evidence of cystic or common bile duct dilation.

Gastrointestinal

INTERPRETED BY

Beth Johnson, DVM
DACVIM

IMAGING PERFORMED BY

Kelly Reschny

HOSPITAL NAME

Windrush VS

REFERRING VET

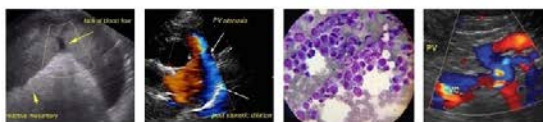
Dr. McGrath

INVOICE

45489

DATE

2/24/23



PATIENT	The stomach wall is normal in thickness (canine < 0.5 cm and feline < 0.4 cm) and layering. The lumen of the stomach is empty with no evidence of obstruction, foreign material or infiltrative disease. Pyloric outflow tract appears patent.
Domino Moran	
SPECIES	The visible small intestine demonstrates areas of mildly to moderately thick muscularis layer relative to mucosa (disruption of the normal 1:3 muscularis:mucosa ratio). Small intestinal submucosa is slightly irregular, thick and hyperechoic, without evident loss of layering appreciated. The lumen is empty with no evidence of obstruction or foreign material.
Feline	
BREED	The visible colon is normal in wall thickness (< 0.2 cm) and layering. Contents are consistent with normal formed feces and gas.
DSH	
SEX	Pancreas
Intact Male	The pancreatic parenchyma is appropriately isoechoic to surrounding tissue. Visible capsule is smooth and normal in contour. There is no visible pancreatic duct dilation. There is no evidence of active peripancreatic inflammation.
AGE	Free Abdomen
7 Years	
WEIGHT	There is no evidence of free peritoneal effusion noted in these images.
4.88 kg	There is no apparent lymphadenopathy noted in these images.
INTERPRETED BY	In the cranial abdomen superficial to the liver in the area of the falciform fat, fat is enhanced/hyperechoic and mottled by multifocal hypoechoic/cystic nodules or densities.
Beth Johnson, DVM DACVIM	
IMAGING PERFORMED BY	PRIMARY FINDINGS
Kelly Reschny	<ul style="list-style-type: none"> • Mild to moderate inflammatory bowel disease (IBD) pattern – Thick muscularis has been reported with infiltrative bowel disease including both benign inflammatory disease as well as infiltrative neoplasia such as lymphoma. No aggressive lymphadenopathy, loss of layering, etc. is noted to make lymphoma more probable, but lymphoma cannot be definitively ruled out without tissue sampling. • Nodular/cystic appearing falciform fat – May represent steatitis of unknown etiology.
HOSPITAL NAME	SECONDARY FINDINGS
Windrush VS	<ul style="list-style-type: none"> • Urinary bladder debris
REFERRING VET	INTERPRETATION OF THE FINDINGS & FURTHER RECOMMENDATIONS
Dr. McGrath	Given the lack of significant anemia, pre-hepatic cholestasis is unlikely, and there is no evidence of post-hepatic cholestasis ultrasonographically, leading the increased bilirubin to likely be intrahepatic cholestasis. Given concurrent laboratory changes, both decreased hepatic function as well as possibly malabsorptive gastrointestinal disease are differentials. Recommendations include a fine needle aspirate of the liver if patient's coagulation status is appropriate, as well as a gastrointestinal malabsorption panel (including cobalamin, folate, TLI and PLI) to Texas A&M GI Laboratory.
INVOICE	If not recently evaluated, a urinalysis and, if indicated based on urinalysis results, urine culture are recommended. If protein is present in an otherwise quiet sediment, protein quantification with a urine protein to creatinine ratio is recommended.
45489	
DATE	The abnormal appearing falciform fat is of unknown clinical significant and of unknown relation to presenting complaints, but it should be further investigated with a fine needle aspirate of the fat for both cytology as well as potentially culture and sensitivity if indicated based on cytology results.
2/24/23	



PATIENT

Domino Moran

Ultimately, pending above results, an exploratory laparotomy for planned full thickness GI biopsies as well as a liver biopsy +/- a falciform fat biopsy may be warranted to obtain a definitive diagnosis and therefore a treatment plan for this patient.

SPECIES

Feline

However, in the meantime, treatment recommendations include fluid therapy, anti-emetics, gastroprotectants, hepatic nutraceuticals such as ursodiol and/or Denamarin, and broad-spectrum antibiotics. Nutritional support is critical to prevent/manage concurrent hepatic lipidosis, so appetite stimulants and/or, if indicated, feeding tube placement is also recommended.

BREED

DSH

Additionally, empirical deworming with a 5-day course of Panacur is recommended.

SEX

Intact Male

AGE

7 Years

WEIGHT

4.88 kg

INTERPRETED BY

Beth Johnson, DVM
DACVIM

IMAGING PERFORMED BY

Kelly Reschny

HOSPITAL NAME

Windrush VS

REFERRING VET

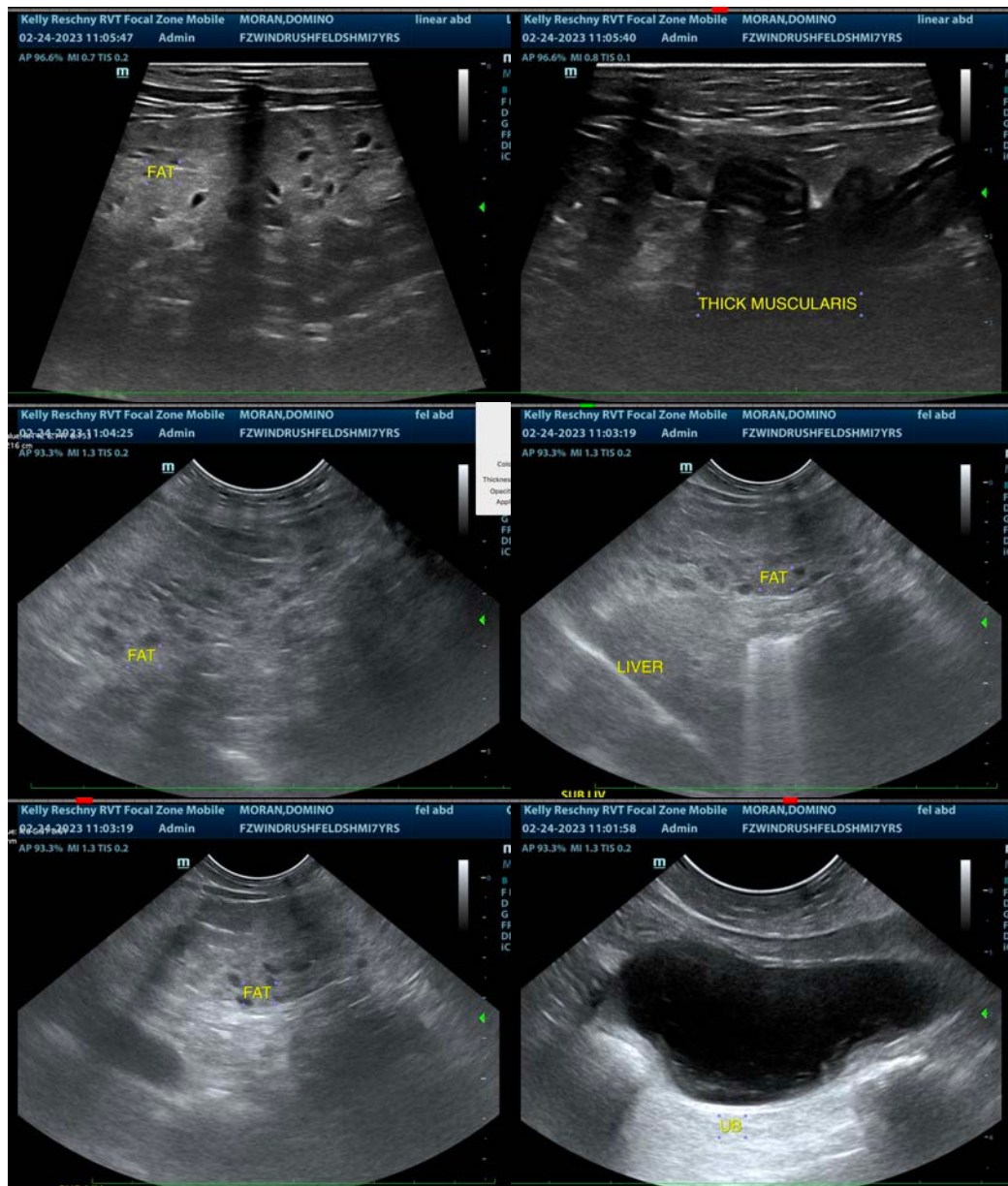
Dr. McGrath

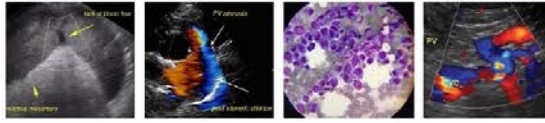
INVOICE

45489

DATE

2/24/23





PATIENT

Domino Moran

SPECIES

Feline

BREED

DSH

SEX

Intact Male

AGE

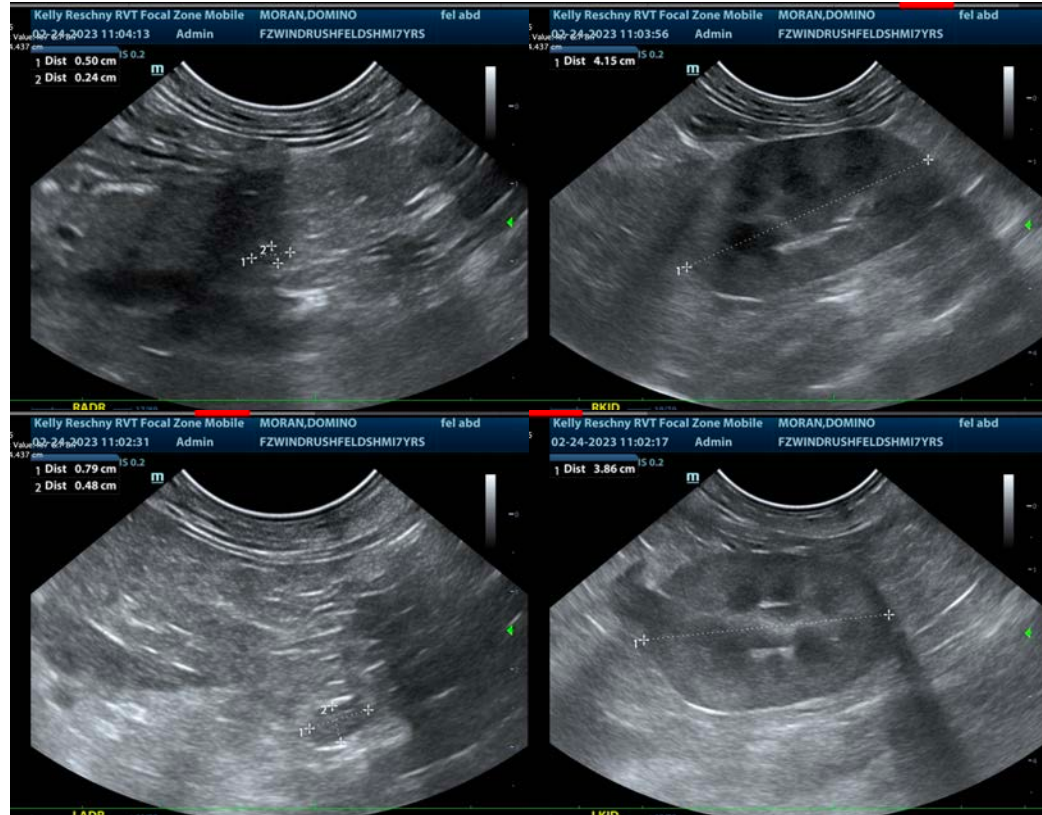
7 Years

WEIGHT

4.88 kg

INTERPRETED BY

Beth Johnson, DVM
DACVIM



IMAGING PERFORMED BY

Kelly Reschny

HOSPITAL NAME

Windrush VS

REFERRING VET

Dr. McGrath

INVOICE

45489

DATE

2/24/23

The information and recommendations provided are based on the images presented by the referring veterinarian/sonographer. No evaluation can be communicated regarding pathology that was not visible in the image/video clips provided.

Thank you for this referral. If the clinical or image interpretation does not parallel your findings or if I can be of any further assistance please contact me.

Beth Johnson, DVM, DACVIM
Beth.Johnson@sonopath.com