

IMAGING PERFORMED BY

IntraPet.com



SonoPath

Clinical Sonography & Telecytology

EDUCATIONAL TELECONSULTATION SERVICES™

1-800-838-4268 info@sonopath.com SonoPath.com

DATE PRESENTING CLINICAL SIGNS

2/24/22

Brought into the rescue this year In January at Mason Dixon- had explore, no FB, but had decrease motility dewormed and GI meds Neutered and had a scrotal infection -- had convenia with RDVM January 25th also note of a cardiac murmur seen 2/21 at RDVM= rads- some bunching, tried outpatient , Sub-q and cerenia did well for 1 day, then tonight vomited large amount of fluid. On PE slightly dehydrated, abdomen palpates uncomfortable, thickened bowel, very full.

PATIENT

Casper Sullivan

SPECIES

Feline

Current Medications: Buprenorphine, Ampicillin, Potassium Chloride, Pantoprazole, Metoclopramide.

Lab Results: Not provided.

Radiographs: Severe distention of stomach, no obvious FB, repeat no improvement.

Date of Previous IntraPet Ultrasound:

Sedation: Sedation utilized for NG tube placement and AUS.

Stat Report: DVM requested Stat report

BREED

DSH

ULTRASONOGRAPHIC EXAMINATION OF THE ABDOMEN

SEX

Neutered Male

Urinary System

The urinary bladder is moderately distended with anechoic contents. No masses, inflammatory changes, echogenic sediment or cystoliths are observed. The urinary bladder, trigone and visible pelvic urethra are normal in thickness with a smooth mucosal surface.

AGE

7/20/21

The right kidney is normal in size (4.18 cm), shape and echogenicity. It has smooth peripheral margination. There is a normal 1:3 cortex to medulla ratio with appropriate corticomedullary distinction. There is no evidence of pyelectasia, mineral or infarcts observed.

WEIGHT

6.2 Pounds

The left kidney is normal in size (3.5 cm), shape and echogenicity. It has smooth peripheral margination. There is a normal 1:3 cortex to medulla ratio with appropriate corticomedullary distinction. There is no evidence of pyelectasia, mineral or infarcts observed.

INTERPRETED BY

Beth Johnson, DVM
DACVIM

Adrenal Glands

The right adrenal gland is normal in size (0.48 cm thick), shape and contour. Corticomedullary structure is unremarkable. Visible surrounding vasculature appears normal.

IMAGING PERFORMED BY

Rachel Brillhart RDMS

The left adrenal gland is normal in size (0.33 cm thick), shape and contour. Corticomedullary structure is unremarkable. Visible surrounding vasculature appears normal.

HOSPITAL NAME

Animal Emergency
Hospital

Spleen

The spleen is subjectively normal in size with a normal smooth capsular contour. Parenchyma is appropriately finely textured and homogenous with normal echogenicity relative to surrounding tissue (hyperechoic to liver). No focal nodules or masses are observed. Splenic vasculature appears normal.

REFERRING VET

Dr. Kalwa

Liver

The liver is subjectively normal in size with normal smooth curvilinear peripheral contour. Parenchyma is appropriately hypoechoic to the spleen in echogenicity and appropriately mildly coarse and homogenous in echotexture. No focal lesions are observed. Visible vasculature and biliary tree appear normal without distension or congestion.

INVOICE

35853

The gallbladder is non-distended in size. The wall is smooth without visible thickening. Luminal contents are primarily anechoic. The common bile duct is tortuous.

Gastrointestinal

The stomach wall is normal in thickness (canine < 0.5 cm and feline < 0.4 cm) and layering. The stomach is markedly distended with sonolucent fluid and suspended echogenic debris. Pyloric outflow tract appears patent.

The visible small intestines are normal in wall thickness. Normal layering is maintained except for a diffusely disproportionately thick muscularis layer relative to mucosa. Small intestinal motility appears decreased with decreased peristalsis. However, marked corrugation/some plication is present throughout most of the small bowel, most prominent in the duodenum. The lumen of the small intestine is mildly distended with echogenic non-shadowing luminal contents and gas consistent with normal ingesta. There is no evidence of obstruction, foreign material or infiltrative disease.

The visible colon is normal in wall thickness (< 0.2 cm) and layering. Contents are consistent with normal formed feces and gas.

Pancreas

The pancreatic parenchyma is appropriately isoechoic to surrounding tissue. Visible capsule is smooth and normal in contour. There is no visible pancreatic duct dilation. There is no evidence of active peripancreatic inflammation.

Free Abdomen

There is no evidence of peritoneal effusion. Mesenteric lymphadenopathy is noted.

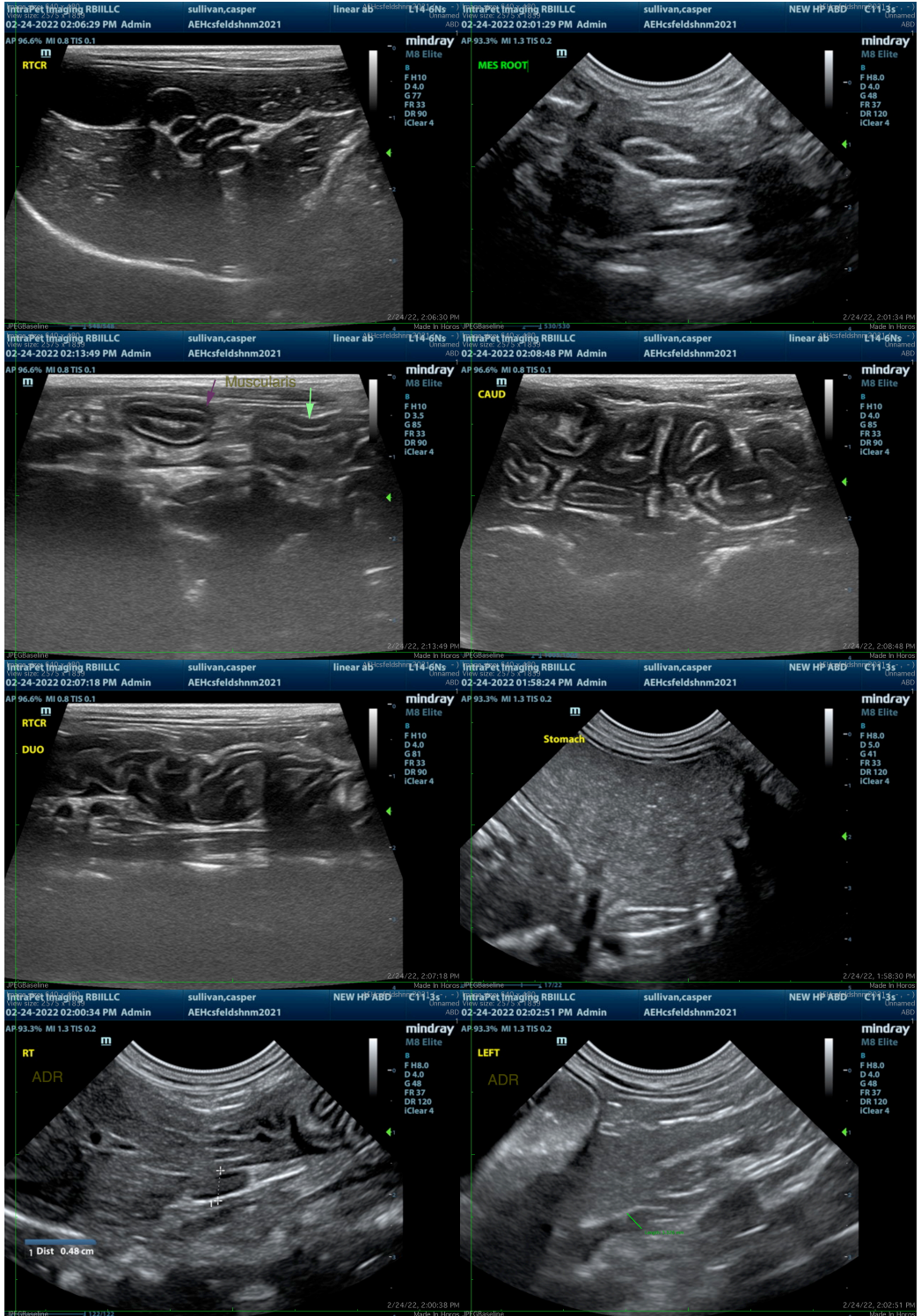
ULTRASONOGRAPHIC FINDINGS

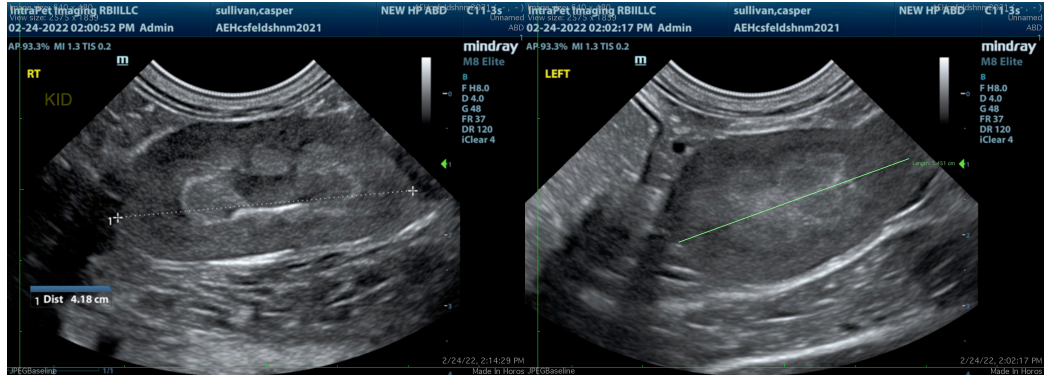
- Markedly fluid distended stomach – Concerning for gastric outflow obstruction versus gastric ileus.
- Thick muscularis – This finding has been reported in cats with infiltrative bowel disease including both benign inflammatory disease as well as infiltrative neoplasia such as lymphoma.
- Diffusely corrugated and mildly plicated small bowel with diffusely decreased motility – Concerning for diffuse gastroenteritis with diffuse ileus. **There is no visible foreign material or linear foreign body. However, marked gastric distention and bowel corrugation is concerning for at least partial obstruction, potentially secondary to adhesions from the previous surgery versus other peritoneal disease.
- Mesenteric lymphadenopathy – Most likely reactive in a patient this age. Infiltrative neoplasia cannot be ruled out but is considered less likely.

INTERPRETATION OF THE FINDINGS & FURTHER RECOMMENDATIONS

Given the marked gastric distention and corrugation/plication combined with the thick muscularis, recommendations include an exploratory laparotomy for breaking down of adhesions from previous surgeries, further investigation for possible foreign material, as well as full thickness biopsies, being sure to include the ileum if possible.

Given the lack of visible foreign material, if a second surgery in this patient is not possible, or other medical management is preferred prior to a second surgery, less invasive diagnostics could include a barium swallow, and medical management could include IV fluids, antiemetics, gastroprotectants, as well as promotility agents with monitoring of the GI tract for improvement versus progression. If clinical signs don't resolve with conservative management, and/or gastric distention progresses and/or barium swallow is also suggestive of gastric outflow obstruction, then exploratory laparotomy would be the next step.





The information and recommendations provided are based on the images presented by the referring veterinarian/sonographer. No evaluation can be communicated regarding pathology that was not visible in the image/video clips provided.

Thank you for this referral. If the clinical or image interpretation does not parallel your findings or if I can be of any further assistance please contact me.

Beth Johnson, DVM, DACVIM
Beth.Johnson@sonopath.com