

**DATE PRESENTING CLINICAL SIGNS**

2/24/22 Nebulous signs of pain, not jumping on bed anymore, 3 urinary accidents in the house in 2 weeks.

PATIENT Current Medications: Carprofen.

Lab Results: UA wnl. Awaiting BW.

Bodhi Smith Radiographs: Multiple bone opacity fragments in SI/colon- per owner chews on antlers. Ventral deviation of cd colon- susp sublumbar LN enlargement. Prostate WNL on palpation and rads. No bladder stones.

Date of Previous IntraPet Ultrasound: No previous.

SPECIES

Canine

Sedation: Domitor 0.5/Torb 0.5ml IM. Pet is a caution- comes in with muzzle and WILL require sedation.

BREED

Stat Report: Not requested.

Pit Bull

ULTRASONOGRAPHIC EXAMINATION OF THE ABDOMEN**SEX *Urinary System***

Neutered Male

The urinary bladder is not fully distended, which partially hinders full assessment. No masses, inflammatory changes, echogenic sediment or cystoliths are observed. The urinary bladder, trigone and visible pelvic urethra are normal in thickness with a smooth mucosal surface.

AGE

11/24/16

The prostate is mildly enlarged for a neutered dog, measuring 1.9 cm thick. However, it maintains a normal echotexture, echogenicity, and symmetrical bilobed shape with normal distinct margins. No cysts or mineral are noted.

WEIGHT

61 Pounds

The right kidney is normal in size (6.8 cm), shape and echogenicity. It has smooth peripheral margination. There is a normal 1:3 cortex to medulla ratio with appropriate corticomedullary distinction. There is no evidence of pyelectasia, mineral or infarcts observed.

INTERPRETED BY

Beth Johnson, DVM
DACVIM

The left kidney is normal in size (6.84 cm), shape and echogenicity. It has smooth peripheral margination. There is a normal 1:3 cortex to medulla ratio with appropriate corticomedullary distinction. There is no evidence of pyelectasia, mineral or infarcts observed.

IMAGING PERFORMED BY

Rachel Brilhart RDMS

Adrenal Glands

The right adrenal gland is normal in size (2.9 cm long x 0.83 cm at the cranial pole and 0.82 cm at the caudal pole), shape and contour. Corticomedullary structure is unremarkable. Visible surrounding vasculature appears normal.

HOSPITAL NAME

Eastern AH

The left adrenal gland is normal in size (2.6 cm long x 0.56 cm at the cranial pole and 0.60 cm at the caudal pole), shape and contour. Corticomedullary structure is unremarkable. Visible surrounding vasculature appears normal.

REFERRING VET

Dr. Sole

Spleen

Spleen is subjectively enlarged in size with rounded margins but intact capsule. Parenchyma is homogeneously coarse/mottled in echotexture and normal to hypochoic in echogenicity. No focal nodules or masses are observed. Splenic vasculature appears normal.

INVOICE

35888

Liver

The liver is subjectively normal in size with normal smooth curvilinear peripheral contour. Parenchyma is appropriately hypochoic to the spleen in echogenicity and appropriately mildly coarse and homogenous in echotexture. No focal lesions are observed. Visible vasculature and biliary tree appear normal without distension or congestion.

The gallbladder is non-distended in size. The wall is smooth without visible thickening. Luminal contents are primarily anechoic. There is no evidence of cystic or common bile duct dilation.

Gastrointestinal

The stomach wall is normal in thickness (canine < 0.5 cm and feline < 0.4 cm) and layering. The lumen of the stomach is mildly distended with echogenic non-shadowing luminal contents and gas consistent with normal ingesta. There is no evidence of obstruction, foreign material or infiltrative disease. Pyloric outflow tract appears patent.

The visible small intestines are normal in wall thickness and layering (canine duodenum < 0.5 cm and feline duodenum < 0.4 cm; other < 0.3 cm). Small intestinal motility appears adequate (1-3 contractions per min). The lumen of the small intestine is mildly distended with echogenic non-shadowing luminal contents and gas consistent with normal ingesta. There is no evidence of obstruction, foreign material or infiltrative disease.

The visible colon is normal in wall thickness (< 0.2 cm) and layering. Contents are consistent with normal formed feces and gas.

Pancreas

The pancreatic parenchyma is appropriately isoechoic to surrounding tissue. Visible capsule is smooth and normal in contour. There is no visible pancreatic duct dilation. There is no evidence of active peripancreatic inflammation.

Free Abdomen

There is no evidence of peritoneal effusion. There is a small sublumbar lymph node present in these images that measures 1.6 cm x 0.6 cm in size. It maintains normal shape and is hypoechoic to surrounding tissue.

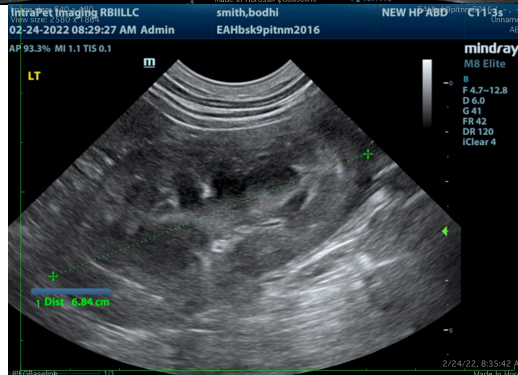
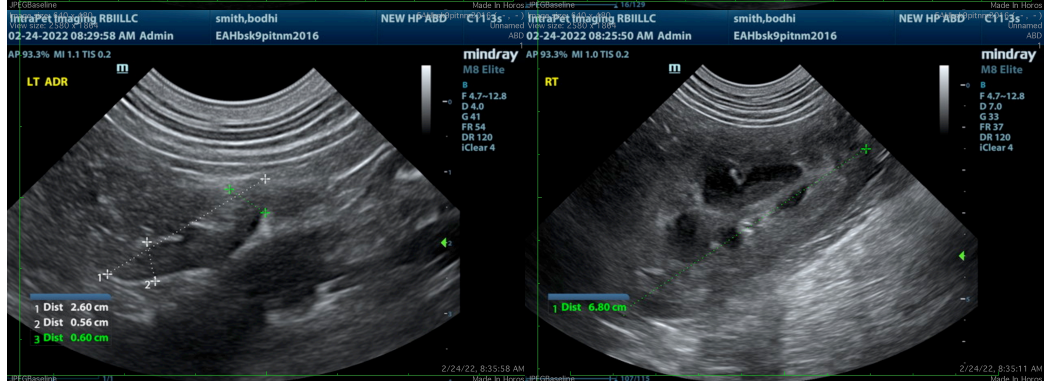
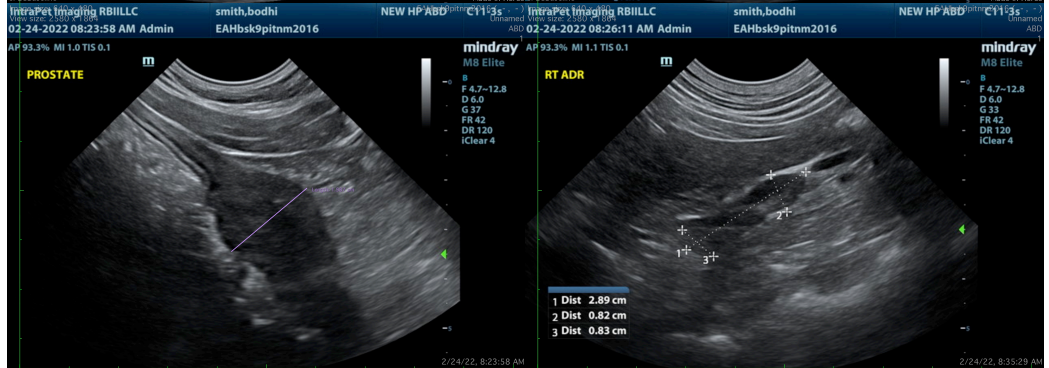
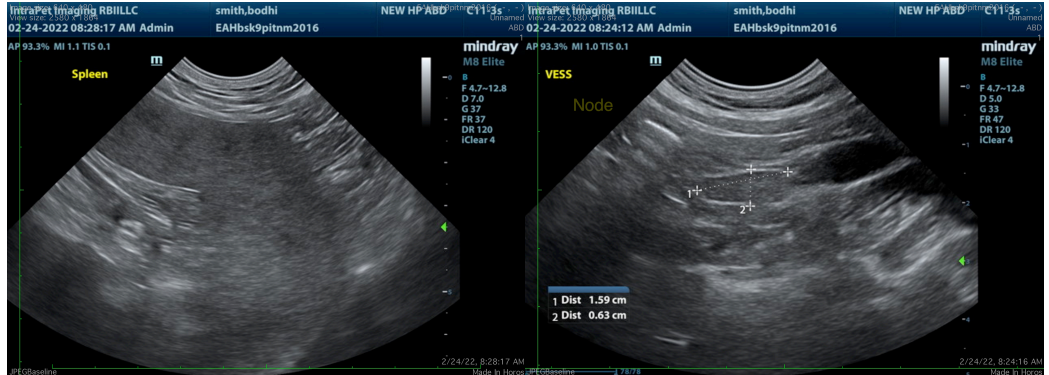
ULTRASONOGRAPHIC FINDINGS

- Coarse splenomegaly – can be associated with congestion caused by sedation (if sedated) but can also be associated with diffuse infiltrative disease. Both benign conditions such as extramedullary hematopoiesis, lymphoid hyperplasia, as well as infiltrative neoplastic diseases such as round cell neoplasia should be considered.
- Mild reactive sublumbar lymphadenopathy – Infiltrative neoplasia cannot be ruled out, but is considered much less likely.
- Very mild prostatomegaly for a dog neutered as a puppy. This is considered a normal patient variant given the otherwise normal appearance, shape, etc. of the prostate. Chronic prostatitis or even infiltrative neoplasia are possible, but considered much less likely.

INTERPRETATION OF THE FINDINGS & FURTHER RECOMMENDATIONS

Given the reported urinary accidents and the very mild prostatomegaly, recommendations include a urine culture to rule out an occult urinary tract infection. The prostate is considered most likely a normal variant, especially if this patient was neutered later in life. However, monitoring is recommended due to the mildly enlarged size, with a recheck ultrasound in 3 months, sooner if clinical signs change or persist.

Recommendations for the pain include further evaluation of possible orthopedic and/or neurologic causes of hip and/or lumbar spinal pain.



The information and recommendations provided are based on the images presented by the referring veterinarian/sonographer. No evaluation can be communicated regarding pathology that was not visible in the image/video clips provided.

Thank you for this referral. If the clinical or image interpretation does not parallel your findings or if I can be of any further assistance please contact me.

Beth Johnson, DVM, DACVIM
Beth.Johnson@sonopath.com