

**PATIENT**

Gabriel Horton

PRESENTING CLINICAL SIGNS

Chronic vomiting for 9 months, was responsive initially to rx i/d diet, but clinical signs returned after a few months.

SPECIES

Feline

Abnormal PE/Chem/CBC/UA Results: BW pending.

ULTRASONOGRAPHIC EXAMINATION OF THE ABDOMEN**Urinary System**

The urinary bladder is moderately distended with anechoic contents. No masses, inflammatory changes, echogenic sediment or cystoliths are observed. The urinary bladder, trigone and visible pelvic urethra are normal in thickness with a smooth mucosal surface.

BREED

DSH

SEX

Neutered Male

The right kidney is normal in size (4.02 cm), shape and echogenicity. It has smooth peripheral margination. There is a normal 1:3 cortex to medulla ratio with appropriate corticomedullary distinction. There is no evidence of pyelectasia, mineral or infarcts observed.

AGE

3.5 Years

The left kidney is normal in size (3.71 cm), shape and echogenicity. It has smooth peripheral margination. There is a normal 1:3 cortex to medulla ratio with appropriate corticomedullary distinction. There is no evidence of pyelectasia, mineral or infarcts observed.

Adrenal Glands**WEIGHT**

5.5 kg

The right adrenal gland is normal in size (0.39 cm), shape and contour. Corticomedullary structure is unremarkable. Visible surrounding vasculature appears normal.

The left adrenal gland is normal in size (0.35 cm), shape and contour. Corticomedullary structure is unremarkable. Visible surrounding vasculature appears normal.

INTERPRETED BYBeth Johnson, DVM
DACVIM**Spleen**

The spleen is subjectively normal in size with a normal smooth capsular contour. Parenchyma is appropriately finely textured and homogenous with normal echogenicity relative to surrounding tissue (hyperechoic to liver). No focal nodules or masses are observed. Splenic vasculature appears normal.

IMAGING PERFORMED BY

Amy Mayhew, LVT

Liver

The liver is subjectively normal in size with normal smooth curvilinear peripheral contour. Parenchyma is appropriately hypoechoic to the spleen in echogenicity and appropriately mildly coarse and homogenous in echotexture. No focal lesions are observed. Visible vasculature and biliary tree appear normal without distension or congestion.

HOSPITAL NAME

SVS Imaging MI

REFERRING VET

Dr. Alex Schechter

Gallbladder is moderately distended with anechoic bile as well as suspended and gravity dependent echogenic debris. The wall is smooth without visible thickening. There is no evidence of cystic or CBD dilation. There is no evidence of effusion or inflammation. Incidentally, this patient also has a bilobed gallbladder, which is most commonly a normal anatomic variant in cats.

INVOICE

45470

Gastrointestinal

The stomach wall is normal in thickness (canine < 0.5 cm and feline < 0.4 cm) and layering. The lumen of the stomach is empty with no evidence of obstruction, foreign material or infiltrative disease. Pyloric outflow tract appears patent.

DATE

2/23/23

The visible small intestines are normal in wall thickness and layering (canine duodenum < 0.5 cm and feline duodenum < 0.4 cm; other < 0.3 cm). Small intestinal motility appears adequate (1-3 contractions

IMAGING PERFORMED BY

SVS Mobile Imaging MI 734-637-7711
svsimagingmi@gmail.com



EDUCATIONAL TELECONSULTATION SERVICES™
1-800-838-4268 info@sonopath.com SonoPath.com

PATIENT

Gabriel Horton

SPECIES

Feline

BREED

DSH

SEX

Neutered Male

AGE

3.5 Years

WEIGHT

5.5 kg

INTERPRETED BY

Beth Johnson, DVM
DACVIM

IMAGING PERFORMED BY

Amy Mayhew, LVT

HOSPITAL NAME

SVS Imaging MI

REFERRING VET

Dr. Alex Schechter

INVOICE

45470

DATE

2/23/23

per min). The lumen of the small intestine is empty with no evidence of obstruction, foreign material or infiltrative disease.

The visible colon is normal in wall thickness (< 0.2 cm) and layering. Contents are consistent with normal formed feces and gas.

Pancreas

The pancreatic parenchyma is appropriately isoechoic to surrounding tissue. Visible capsule is smooth and normal in contour. There is no visible pancreatic duct dilation. There is no evidence of active peripancreatic inflammation.

Free Abdomen

There is no evidence of free peritoneal effusion noted in these images.

The mesenteric lymph nodes are prominent in size with swollen capsular contour. Normal elongated shape (length to width ratio) is maintained. There is no loss of parenchymal detail.

ULTRASONOGRAPHIC FINDINGS

- **Mild gallbladder debris** - Cholecystic debris is of unknown clinical significance. It can be seen with biliary stasis from fasting or illness, however, it can also be associated with hepatobiliary disease in cats and should be interpreted in combination with clinical signs such as nausea, inappetence, cranial abdominal discomfort and/or laboratory changes such as increased ALP and/or increased Tbili.
- **Reactive mesenteric lymph nodes** - infiltrative neoplastic disease cannot be ruled out but is considered less likely.

INTERPRETATION OF THE FINDINGS & FURTHER RECOMMENDATIONS

As is reportedly already pending, a general metabolic health screen is recommended including CBC/Chem panel, electrolytes, a urinalysis and, if indicated based on urinalysis results, urine culture. If protein is present in an otherwise quiet sediment, protein quantification with a urine protein to creatinine ration is recommended.

Close attention for evidence of cholangitis as contributing cause of this patient's vomiting is recommended. If physical exam findings and/or laboratory changes don't support cholangitis, additional evaluation of possible pancreatic and/or gastrointestinal disease is recommended, beginning with a gastrointestinal malabsorption panel (including cobalamin, folate, TLI and PLI) to Texas A&M GI Laboratory.

In the meantime, empirical deworming with a 5-day course of Panacur is recommended. Given this patient's reported improvement originally with a transition to a GI diet, a food component is suspected, and additional transition (if tolerated) to potentially a hydrolyzed protein diet could be considered, understanding that many patients respond better to one brand versus another, so sometimes several trial are needed.

IMAGING PERFORMED BY

SVS Mobile Imaging MI SVS 734-637-7711 svsimagingmi@gmail.com



PATIENT

Gabriel Horton

SPECIES

Feline

BREED

DSH

SEX

Neutered Male

AGE

3.5 Years

WEIGHT

5.5 kg

INTERPRETED BY

Beth Johnson, DVM DACVIM

IMAGING PERFORMED BY

Amy Mayhew, LVT

HOSPITAL NAME

SVS Imaging MI

REFERRING VET

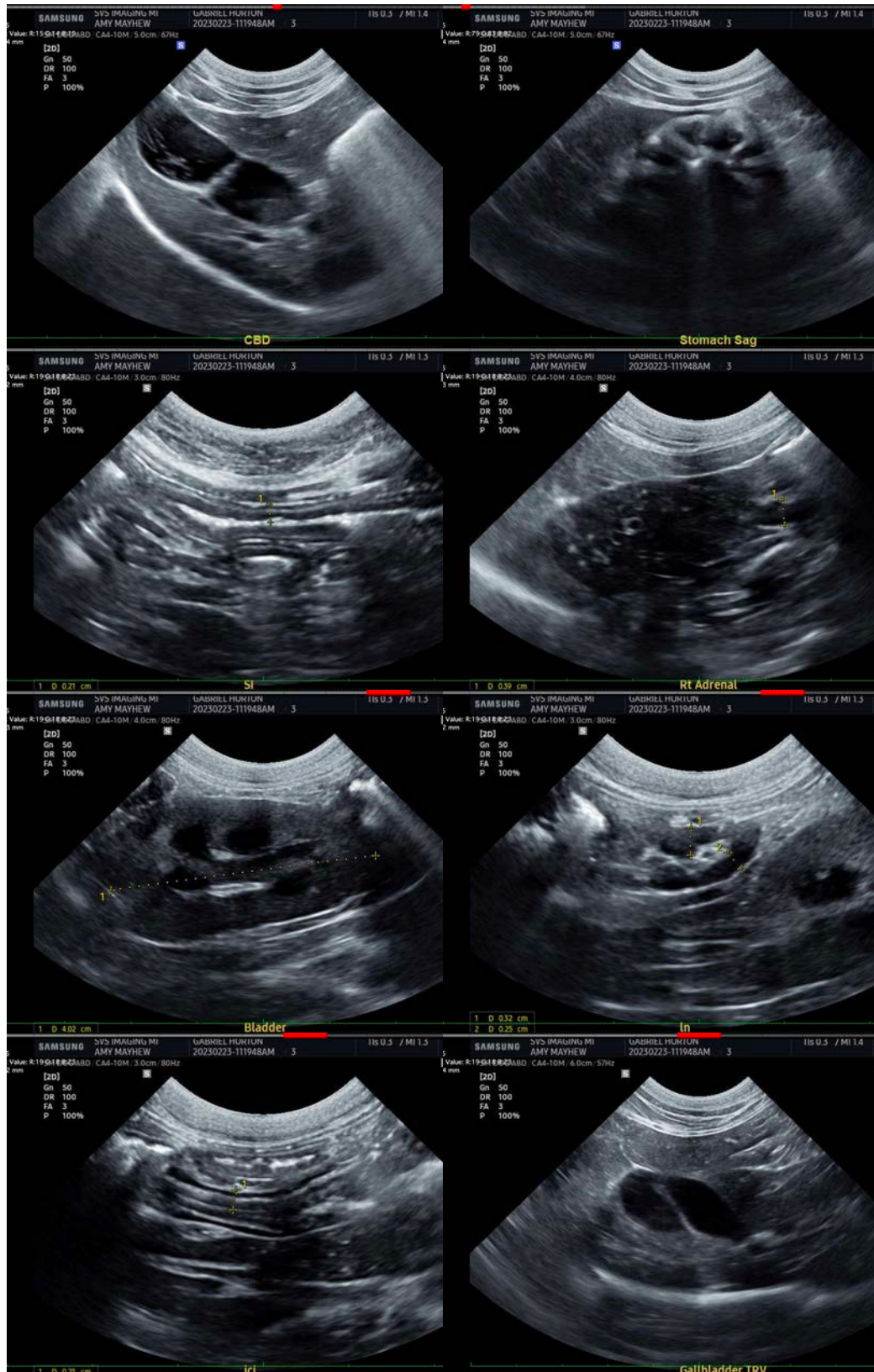
Dr. Alex Schechter

INVOICE

45470

DATE

2/23/23



IMAGING PERFORMED BY

SVS Mobile Imaging MI 734 - 637 - 7711
svsimagingmi@gmail.com



EDUCATIONAL TELECONSULTATION SERVICES™
1-800-838-4268 info@sonopath.com SonoPath.com

PATIENT

Gabriel Horton

SPECIES

Feline

BREED

DSH

SEX

Neutered Male

AGE

3.5 Years

WEIGHT

5.5 kg

INTERPRETED BY

Beth Johnson, DVM
DACVIM

IMAGING PERFORMED BY

Amy Mayhew, LVT

HOSPITAL NAME

SVS Imaging MI

REFERRING VET

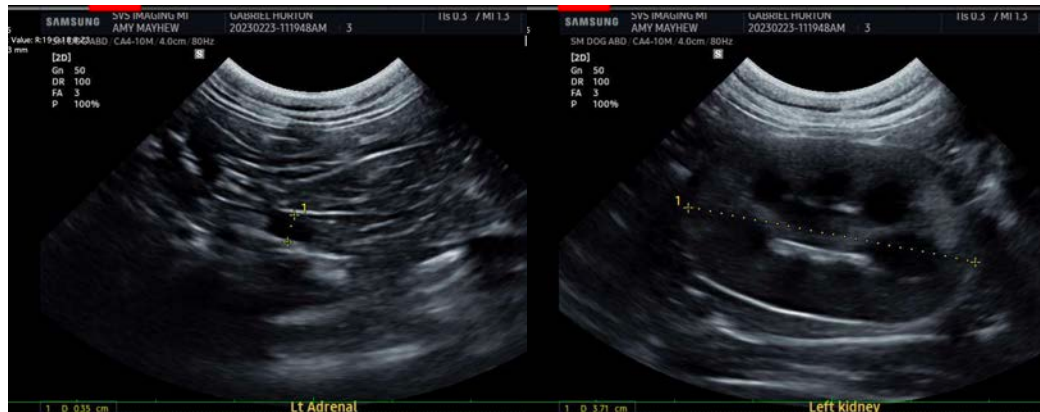
Dr. Alex Schechter

INVOICE

45470

DATE

2/23/23



The information and recommendations provided are based on the images presented by the referring veterinarian/sonographer. No evaluation can be communicated regarding pathology that was not visible in the image/video clips provided.

Thank you for this referral. If the clinical or image interpretation does not parallel your findings or if I can be of any further assistance please contact me.

Beth Johnson, DVM, DACVIM
Beth.Johnson@sonopath.com