



PATIENT

Mayzee Strisofsky

SPECIES

Feline

BREED

DSH

SEX

Spayed Female

AGE

12 Years 10 Months

WEIGHT

7.5

INTERPRETED BY

Beth Johnson, DVM
DACVIM

IMAGING PERFORMED BY

Jessica Green

HOSPITAL NAME

Stanglein Vet Clinic

REFERRING VET

Dr. Daniel Hoffman

INVOICE

45400

DATE

2/22/23

PRESENTING CLINICAL SIGNS

Owner reports an approximate 2-week history of significant hyporexia with weight loss (however this is the first time we've seen this patient, so we do not have any previous weights for comparison). Owner is noticing occasional piles of vomit around the house but is unsure which of his cats are vomiting (assumed to be Mayzee). The patient is also more lethargic and distant from the family. On presentation the patient's respiratory rate was elevated but her effort seemed relatively normal (not in any distress).

Abnormal PE/Chem/CBC/UA Results: BC: relatively mild mature neutrophilia (NEUT=19.01 K/uL), and monocytosis (MONOS= 1.07L/uL). Chemistry: There is mild stress hyperglycemia (GLU=180mg/dL); the SDMA is mildly elevated, but the other renal values are WNL, (SDMA= 20ug/dL); there is severely elevated GGT (GGT=25U/L) and Lipase (LIPA=3196 U/L), but the chemistry is otherwise unremarkable. T4= 0.6ug/dL, but suspected to be euthyroid sick... Rads: there is moderate pleural effusion, leading to an effacement of the cardiac silhouette; there is also moderately decreased serosal detail in the abdomen, but no obvious masses noted.

ULTRASONOGRAPHIC EXAMINATION OF THE ABDOMEN

Urinary System

The urinary bladder is moderately distended with anechoic contents. No masses, inflammatory changes, echogenic sediment or cystoliths are observed. The urinary bladder, trigone and visible pelvic urethra are normal in thickness with a smooth mucosal surface.

The right kidney is normal in size (3.87 cm), shape and echogenicity. It has smooth peripheral margination. There is a normal 1:3 cortex to medulla ratio with appropriate corticomedullary distinction. There is no evidence of pyelectasia, mineral or infarcts observed.

The left kidney is normal in size (3.81 cm), shape and echogenicity. It has smooth peripheral margination. There is a normal 1:3 cortex to medulla ratio with appropriate corticomedullary distinction. There is no evidence of pyelectasia, mineral or infarcts observed.

Adrenal Glands

The right adrenal gland is normal in size (0.38 cm), shape and contour. Corticomedullary structure is unremarkable. Visible surrounding vasculature appears normal.

The left adrenal gland is normal in size (0.38 cm), shape and contour. Corticomedullary structure is unremarkable. Visible surrounding vasculature appears normal.

Spleen

Spleen is subjectively large in size with subtly scalloped or undulating capsular contour. Parenchyma is normal in echogenicity with a mildly coarse/heterogenous echotexture. No focal nodules or masses are observed. Splenic vasculature appears normal.

Liver

Liver is subjectively enlarged (swollen contour) without disruption of architecture. It has a normal homogenous echotexture. Parenchyma is diffusely hyperechoic characterized by less prominent than normal portal vein walls and increased echogenicity relative to the spleen and falciform fat. No focal lesions are observed. Visible vasculature and biliary tree appear normal without distension or congestion.



PATIENT

Mayzee Strisofsky

Gallbladder is moderately distended with anechoic bile as well as suspended and gravity dependent echogenic debris. The wall is smooth without visible thickening. The cystic and common bile duct are tortuous but not pathologically distended, which is often a normal anatomic variant in a cat.

SPECIES

Feline

Gastrointestinal

The stomach wall is normal in thickness (canine < 0.5 cm and feline < 0.4 cm) and layering. The lumen of the stomach is empty with no evidence of obstruction, foreign material or infiltrative disease. Pyloric outflow tract appears patent.

BREED

DSH

Diffusely, the visible small intestines are normal in wall thickness and layering (canine duodenum < 0.5 cm and feline duodenum < 0.4 cm; other < 0.3 cm). Small intestinal motility appears adequate (1-3 contractions per min). The lumen of the small intestine is empty with no evidence of obstruction, foreign material or infiltrative disease. However, in the mid caudal abdomen, there is an approximately 3.5 cm long section of small bowel that is concentrically thick, measuring 0.60 cm in thickness with a heterogeneous, hypoechoic wall and loss of mural detail/loss of normal layering.

SEX

Spayed Female

AGE

12 Years 10 Months

The visible colon is normal in wall thickness (< 0.2 cm) and layering. Contents are consistent with normal formed feces and gas.

WEIGHT

7.5

Pancreas

The pancreatic parenchyma is appropriately isoechoic to surrounding tissue. Visible capsule is smooth and normal in contour. There is no visible pancreatic duct dilation. There is no evidence of active peripancreatic inflammation.

INTERPRETED BY

Beth Johnson, DVM
DACVIM

Free Abdomen

There is a moderate amount of free abdominal fluid as well as pleural effusion noted in these images.

Surrounding the bowel mass, there is markedly enhanced hyperechoic mesenteric fat with pocketed fluid throughout the enhanced mesentery.

IMAGING PERFORMED BY

Jessica Green

There is no apparent lymphadenopathy noted in these images.

ULTRASONOGRAPHIC FINDINGS

HOSPITAL NAME

Stanglein Vet Clinic

- **Small bowel mass** – concerning for infiltrative neoplasia such as round cell neoplasia i.e., lymphoma. A benign infiltrative process is considered possible but exceedingly less likely. The free fluid and enhanced mesenteric fat surrounding the mass are suggestive of a severe inflammatory peritonitis surrounding the bowel mass.

REFERRING VET

Dr. Daniel Hoffman

- **Hyperechoic hepatomegaly** – This appearance is most consistent with benign hepatic lipidosis. Infiltrative disease such as amyloidosis or round cell neoplasia, such as mast cell tumor or less likely, lymphoma, is also possible.

INVOICE

45400

DATE

2/22/23

- **Scalloped spleen** – can be associated with benign or malignant infiltrative disease. Common causes include a reactive spleen secondary to immune stimulus or early infiltrative round cell neoplasia such as lymphoma or mast cell tumor.

- Pleural effusion may represent a concurrent paraneoplastic effusion versus increased hydrostatic pressure from an unknown intrathoracic disease as well, cardiac disease, etc.



PATIENT

Mayzee Strisofsky

SPECIES

Feline

BREED

DSH

SEX

Spayed Female

AGE

12 Years 10 Months

WEIGHT

7.5

INTERPRETED BY

Beth Johnson, DVM
DACVIM

IMAGING PERFORMED BY

Jessica Green

HOSPITAL NAME

Stanglein Vet Clinic

REFERRING VET

Dr. Daniel Hoffman

INVOICE

45400

DATE

2/22/23

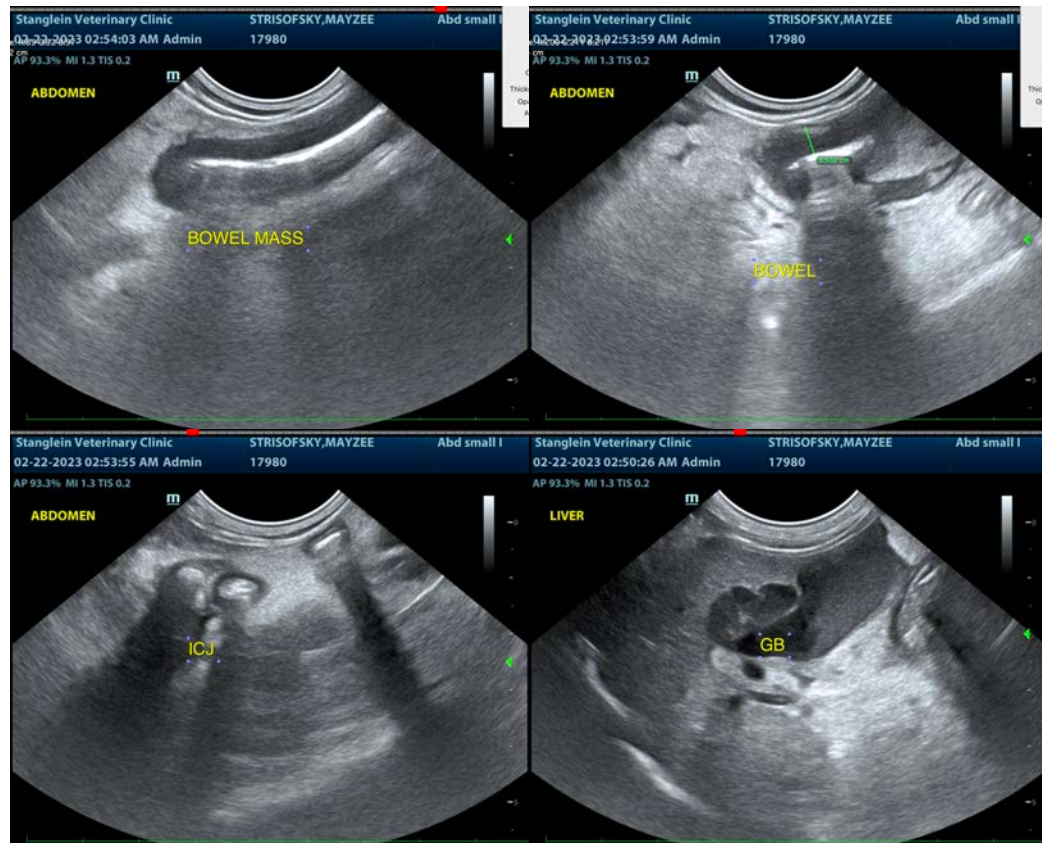
INTERPRETATION OF THE FINDINGS & FURTHER RECOMMENDATIONS

Three view thoracic radiographs are recommended for further assessment of cardio-pulmonary status as well as to further evaluate for any evidence of metastatic disease, if not recently evaluated, +/- a echocardiogram.

Sampling of both the free abdominal fluid and the pleural effusion is recommended as a diagnostic with submission of samples for both cytology as well as culture and sensitivity if indicated based on cytology results, and a therapeutic procedure given this patient's reported respiratory signs.

Additionally, if patient's coagulation status is appropriate and patient is stable to undergo the procedure, fine needle aspirates of the bowel mass +/- the spleen and liver are recommended to look for evidence of infiltrative round cell neoplasia.

Ultimately, to help direct therapy, a gastrointestinal malabsorption panel (including cobalamin, folate, TLI and PLI) to Texas A&M GI Laboratory is recommended for further evaluation of GI and pancreatic function. However, obtaining a cytologic diagnosis and stabilizing the patient is more critically important.





PATIENT

Mayzee Strisofsky

SPECIES

Feline

BREED

DSH

SEX

Spayed Female

AGE

12 Years 10 Months

WEIGHT

7.5

INTERPRETED BY

Beth Johnson, DVM
DACVIM

IMAGING PERFORMED BY

Jessica Green

HOSPITAL NAME

Stanglein Vet Clinic

REFERRING VET

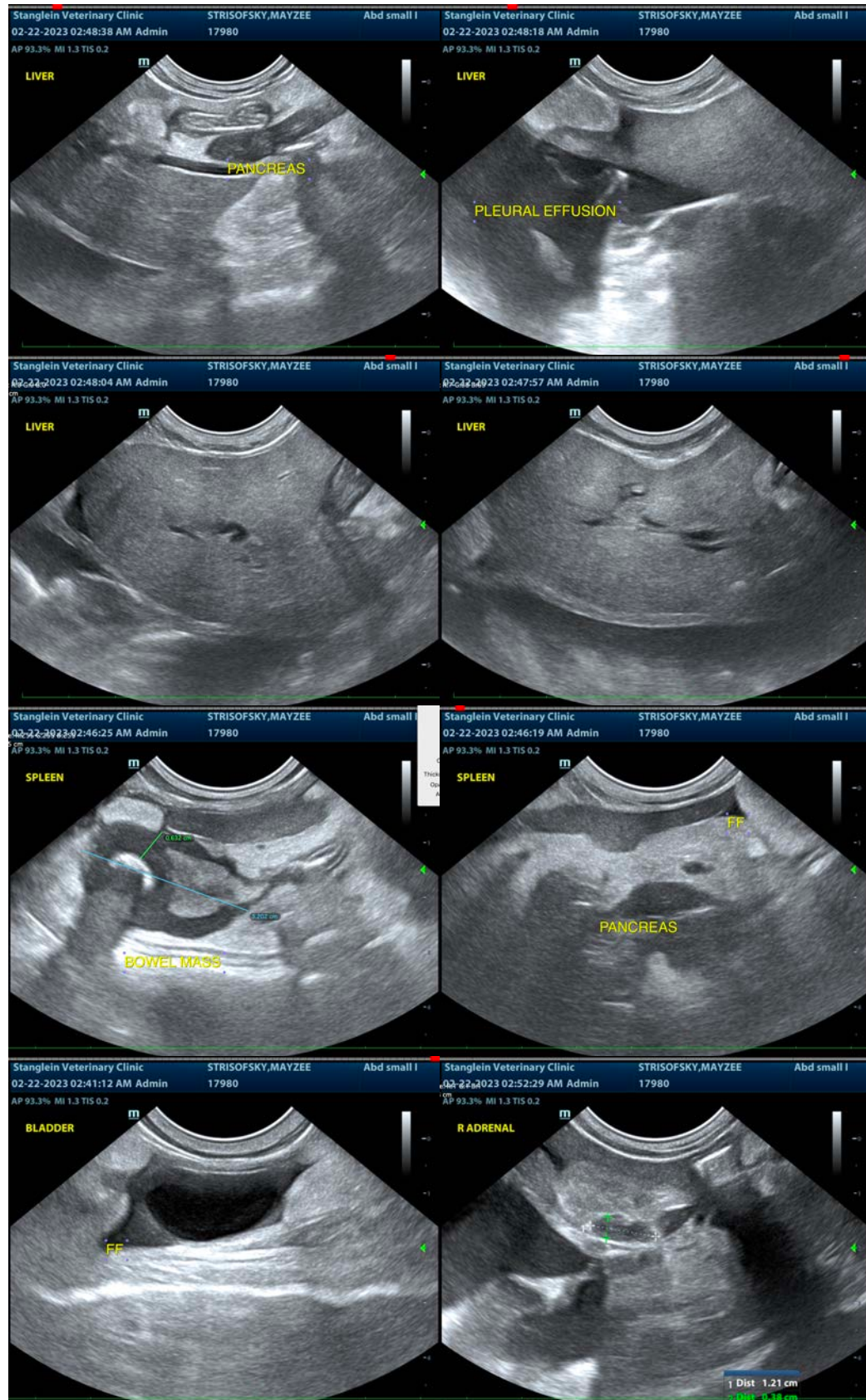
Dr. Daniel Hoffman

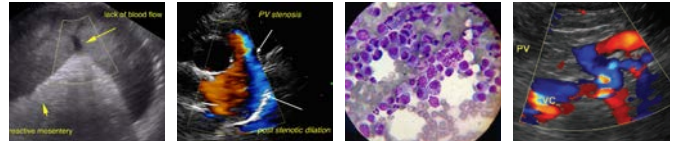
INVOICE

45400

DATE

2/22/23





PATIENT

Mayzee Strisofsky

SPECIES

Feline

BREED

DSH

SEX

Spayed Female

AGE

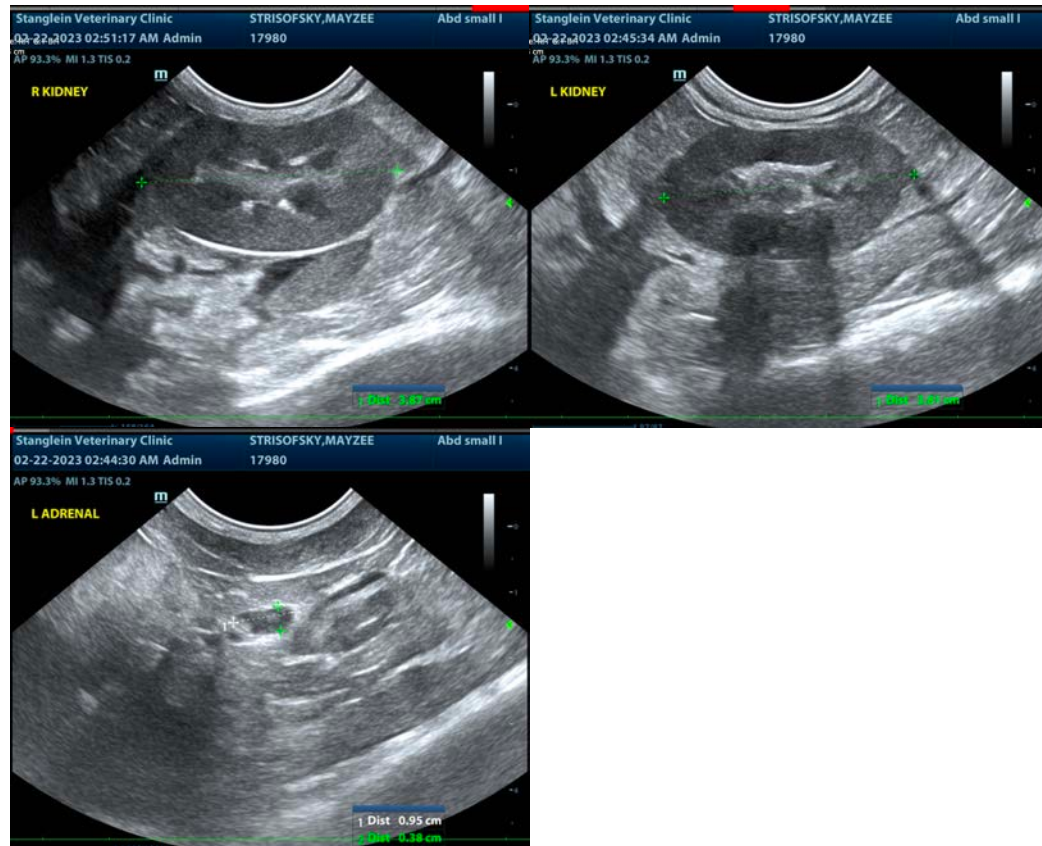
12 Years 10 Months

WEIGHT

7.5

INTERPRETED BY

Beth Johnson, DVM
DACVIM



IMAGING PERFORMED BY

Jessica Green

HOSPITAL NAME

Stanglein Vet Clinic

REFERRING VET

Dr. Daniel Hoffman

INVOICE

45400

DATE

2/22/23

The information and recommendations provided are based on the images presented by the referring veterinarian/sonographer. No evaluation can be communicated regarding pathology that was not visible in the image/video clips provided.

Thank you for this referral. If the clinical or image interpretation does not parallel your findings or if I can be of any further assistance please contact me.

Beth Johnson, DVM, DACVIM
Beth.Johnson@sonopath.com