

DATE PRESENTING CLINICAL SIGNS

2/22/23

Chronic mixed bowel diarrhea. No weight loss. Will improve on metronidazole, but does not fully resolve. Strict hydrolyzed diet for 1 month, no improvement. Addition of fiber (psyllium husk powder) no improvement. Negative fecal screening x2. Chronic mild to moderate allergic dermatitis (intermittent malassezia dermatitis, interdigital pododermatitis). Controlled with cytopoint PRN and topical miconahex+triz mousse.

PATIENT

Diamond Blue Williams

Current Medications: Metronidazole, Provable Forte, Purina HA
Lab Results: Total Protein 7.8, Albumin 4.1, ALT 209, Resting Cortisol WNL. Incidental urinary tract infection on UA to complete senior panel

SPECIES

Canine

Rods present, USG 1.010, Protein 30 mg/dL, 8 WBC/hpf. GI panel to Texas pending.

Date of Previous IntraPet Ultrasound: No previous.

Sedation: Not required to complete full diagnostic ultrasound.

Stat Report: Not requested.

BREED

Pit Bull

Imaging Performed By: Rachel Brillhart, RDMS.

SEX

Spayed female

ULTRASONOGRAPHIC EXAMINATION OF THE ABDOMEN

Urinary System

Urinary bladder is adequately distended with primarily anechoic contents and occasional echogenic non-shadowing debris. Apical urinary bladder wall is diffusely thick (0.92 cm). Mucosa is hyperechoic and irregular. No masses or cystoliths are observed. The trigone and visible pelvic urethra are normal thickness with a smooth mucosal surface.

AGE

12/1/11

Kidneys are overall normal in size and shape with smooth peripheral margination. A normal 1:3 cortex to medulla ratio is maintained. The medulla and cortices are uniform in texture with some mild increased cortical echogenicity and mild loss of corticomedullary distinction, expected in this age patient. There is no evidence of pyelectasia, mineral or infarcts observed. The left kidney measured 7.33 cm and the right kidney measured 7.43 cm.

WEIGHT

66.5 lbs

INTERPRETED BY

Beth Johnson, DVM
DACVIM

Adrenal Glands

Adrenal glands are plump/swollen in size. Normal shape and contour are maintained without evidence of capsular invasion. Corticomedullary structure is unremarkable. Visible surrounding vasculature appears normal. The left adrenal gland measured 3.3 cm long, 1.06 cm at cranial pole and 1.0 cm at caudal pole. The right adrenal gland measured 3.82 cm long, 1.1 cm at cranial pole and 0.97 cm at caudal pole.

HOSPITAL NAME

Paradise AH

Spleen

Spleen is subjectively normal in size with a normal smooth capsular contour. Parenchyma is appropriately finely textured and homogenous with normal echogenicity relative to surrounding tissue (hyperechoic to liver). No focal nodules or masses are observed. Splenic vasculature appears normal.

REFERRING VET

Dr. Pound

INVOICE

42929

Liver

Liver is subjectively normal in size with normal smooth curvilinear peripheral contour. Parenchyma is appropriately hypoechoic to the spleen in echogenicity and appropriately mildly coarse and homogenous in echotexture. No focal lesions are observed. Visible vasculature and biliary tree appear normal without distension or congestion.

Gallbladder is non-distended in size. The wall is smooth without visible thickening. Luminal contents are primarily anechoic. There is no evidence of cystic or common bile duct dilation.

Gastrointestinal

The visible stomach wall is normal in thickness and layering. The lumen of the stomach is mildly distended with echogenic non-shadowing luminal contents and gas consistent with normal ingesta. There is no evidence of obstruction, foreign material or infiltrative disease. Pyloric outflow tract appears patent.

The visible small intestines are normal in wall thickness and layering. Small intestinal motility appears adequate (1-3 contractions per min). The lumen of the small intestine is empty with no evidence of obstruction, foreign material or infiltrative disease.

The visible colon is normal in wall thickness (< 0.2 cm) and layering. Contents are consistent with normal formed feces and gas.

Pancreas

The observed pancreas appears appropriately isoechoic to surrounding omental fat. Visible capsule is smooth and normal in contour. Visible pancreatic parenchyma is homogenous and unremarkable. There is no visible pancreatic duct dilation. There is no evidence of active peripancreatic inflammation.

Free Abdomen

There is no evidence of free peritoneal effusion noted in these images.

There is no apparent lymphadenopathy noted in these images.

A mid left, hypoechoic mammary mass with a mineralized density within the center was noted.

ULTRASONOGRAPHIC FINDINGS

- **Bilateral adrenomegaly** – consistent with adrenal hyperplasia secondary to pituitary dependent hyperadrenocorticism vs stress or normal variant. Interpret in combination with clinical signs of hyperadrenocorticism.
- **Chronic Cystitis** - Urinary bladder wall changes are most consistent with chronic cystitis. Infiltrative neoplasia cannot be ruled out but is considered less likely give the location and diffuse nature of the changes.
- **Age related renal changes.**
- **Left mid mammary mass.**

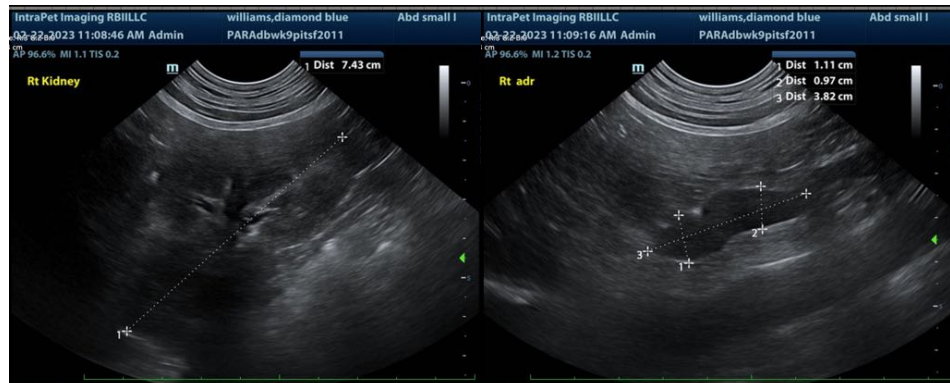
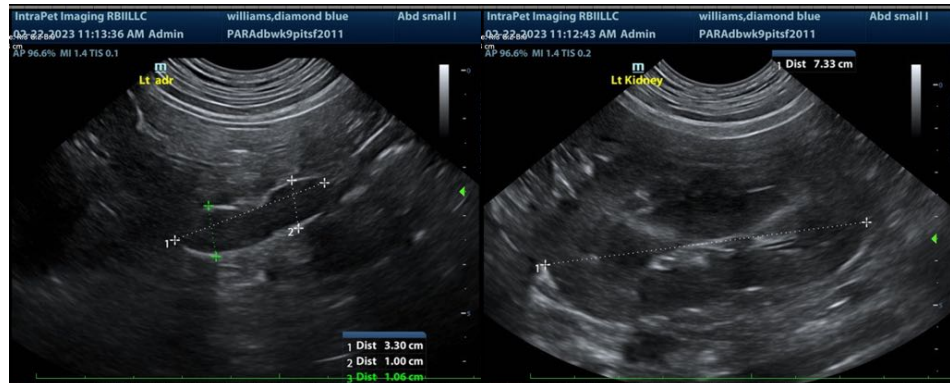
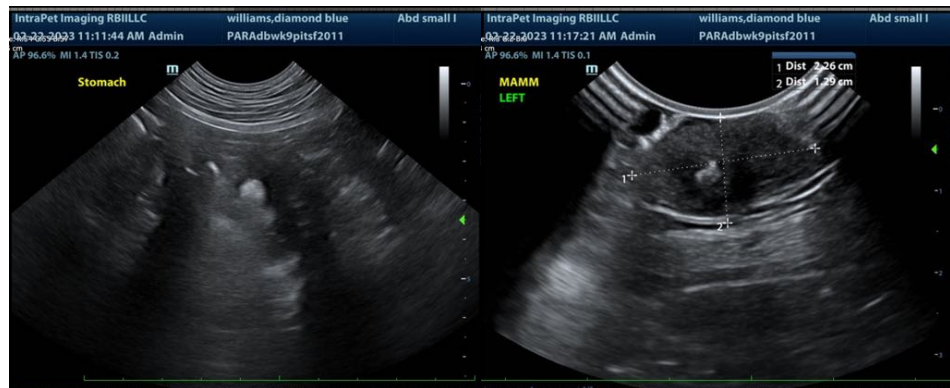
INTERPRETATION OF THE FINDINGS & FURTHER RECOMMENDATIONS

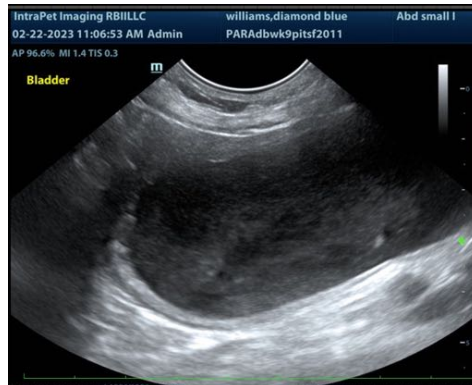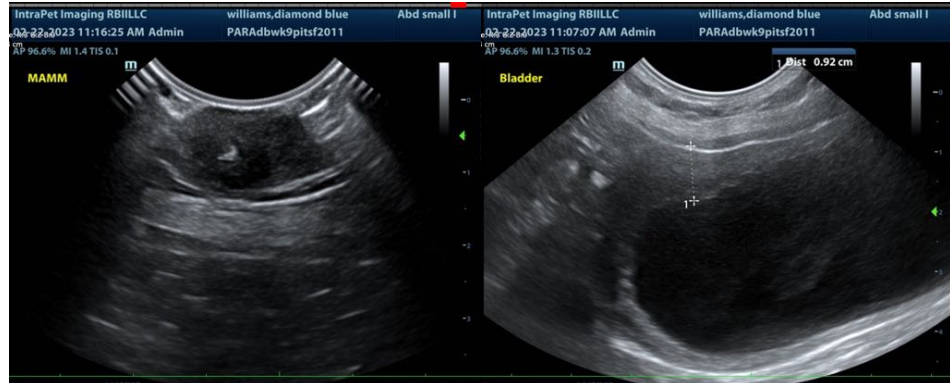
Given this patient's chronic intermittent diarrhea as is reportedly already pending:

1. A gastrointestinal malabsorption panel (including cobalamin, folate, TLI and PLI) to Texas A&M GI Laboratory is recommended for further evaluation of GI and pancreatic function.
2. Given the partial reported response to Metronidazole a fecal enteropathogen PCR panel to Texas A&M GI Laboratory could be considered for further evaluation of possible infectious disease.

In the meantime, in addition to a probiotic that is reportedly currently in place empirical deworming with a 5-day course of Panacur is recommended. Transition from Metronidazole to Tylosin could be considered. Ultimately pending diagnostic results if this is a bacterial dysbiosis overgrowth antibiotic responsive diarrhea

a fecal transplant may offer some benefit. Additionally unrelated to the diarrhea, removal/biopsy of the mammary mass is recommended. If chronic urinary tract infections become a persistent problem and/or there are other clinical signs of hyperadrenocorticism, testing in the form of low-dose Dexamethasone suppression test may be warranted. However, further investigation of possible hyperadrenocorticism is not indicated in the face of concurrent illness like this patient's chronic diarrhea.





The information and recommendations provided are based on the images presented by the referring veterinarian. No evaluation can be communicated regarding pathology that was not visible in the image/video clips provided.

Thank you for this referral. If the clinical or image interpretation does not parallel your findings or if I can be of any further assistance please contact me.

Beth Johnson, DVM DACVIM
Beth.Johnson@SonoPath.com