

**DATE PRESENTING CLINICAL SIGNS**

2/22/23

Doing relatively well for age. But owner does report PU/PD. USG has been between 1.009-1.018 over past 6 months with no signs of UTI. Most recent BW (2/16) showed ALT of 453 U/L.

PATIENT

Angel Schneider

Current Medications: None listed.
Date of Previous IntraPet Ultrasound: No previous.

SPECIES

Canine

Sedation: torbugesic 0.6 ml IM.

Stat Report: Not requested.
Imaging Performed By: Rachel Brillhart, RDMS.

BREED

GSHP

ULTRASONOGRAPHIC EXAMINATION OF THE ABDOMEN**SEX**

Spayed Female

Urinary System

The urinary bladder is moderately distended with anechoic contents. No masses, inflammatory changes, echogenic sediment or cystoliths are observed. The urinary bladder, trigone and visible pelvic urethra are normal in thickness with a smooth mucosal surface.

AGE

9/10/10

Kidneys are overall normal in size and shape with smooth peripheral margination. A normal 1:3 cortex to medulla ratio is maintained. The medulla and cortices are uniform in texture with some mild increased cortical echogenicity and mild loss of corticomedullary distinction, expected in this age patient. There is no evidence of pyelectasia, mineral or infarcts observed. The left kidney measures 5.27 cm. The right kidney measures 6.12 m.

WEIGHT

66 Pounds

Adrenal Glands**INTERPRETED BY**Beth Johnson, DVM
DACVIM

Adrenal glands are plump/swollen in size. Normal shape and contour are maintained without evidence of capsular invasion. Some parenchymal heterogeneity is present without concerning capsular distortion. Visible surrounding vasculature appears normal. The left adrenal gland measures 2.93 cm long x 0.89 cm at the cranial pole and 1.08 cm at the caudal pole. The right adrenal gland measures 2.34 cm long x 0.72 cm at the cranial pole and 0.92 cm at the caudal pole.

HOSPITAL NAME

Paradise AH

Spleen

The spleen is subjectively normal in size with a normal smooth capsular contour. Parenchyma is appropriately finely textured and homogenous with normal echogenicity relative to surrounding tissue (hyperechoic to liver). No focal nodules or masses are observed. Splenic vasculature appears normal.

REFERRING VET

Dr. King

Liver

Liver is subjectively enlarged with mildly irregular margins. Parenchyma is heterogenous characterized by multiple poorly defined hypoechoic nodules within otherwise hyperechoic liver parenchyma. Visible vasculature and biliary tree appear normal without distension or congestion.

INVOICE

45441

The gallbladder is non-distended in size. The wall is smooth without visible thickening. Luminal contents are primarily anechoic. There is no evidence of cystic or common bile duct dilation.

Gastrointestinal

The visible stomach wall is normal in thickness and layering. The lumen of the stomach is mildly distended with echogenic non-shadowing luminal contents and gas consistent with normal ingesta. There is no evidence of obstruction, foreign material or infiltrative disease. Pyloric outflow tract appears patent.

The visible small intestines are normal in wall thickness and layering. Small intestinal motility appears adequate (1-3 contractions per min). The lumen of the small intestine is mildly distended with echogenic non-

shadowing luminal contents and gas consistent with normal ingesta. There is no evidence of obstruction, foreign material or infiltrative disease.

Pancreas

Pancreas is prominent (enlarged) in size and mildly irregular in shape with a slightly undulating contour. Parenchyma is coarse in echotexture and heterogenous to hypoechoic in echogenicity.

Free Abdomen

There is no evidence of free peritoneal effusion noted in these images.

There is no apparent lymphadenopathy noted in these images.

PRIMARY FINDINGS

- **Bilateral adrenomegaly** – consistent with adrenal hyperplasia secondary to pituitary dependent hyperadrenocorticism vs stress or normal variant. Interpret in combination with clinical signs of hyperadrenocorticism.
- **Heterogenous Liver** – These changes are most consistent with benign processes such as nodular hyperplasia, steroid (vacuolar) hepatopathy, extramedullary hematopoiesis or possibly chronic inflammatory disease and less commonly infiltrative round cell or metastatic neoplasia.
- Chronic active pancreatitis

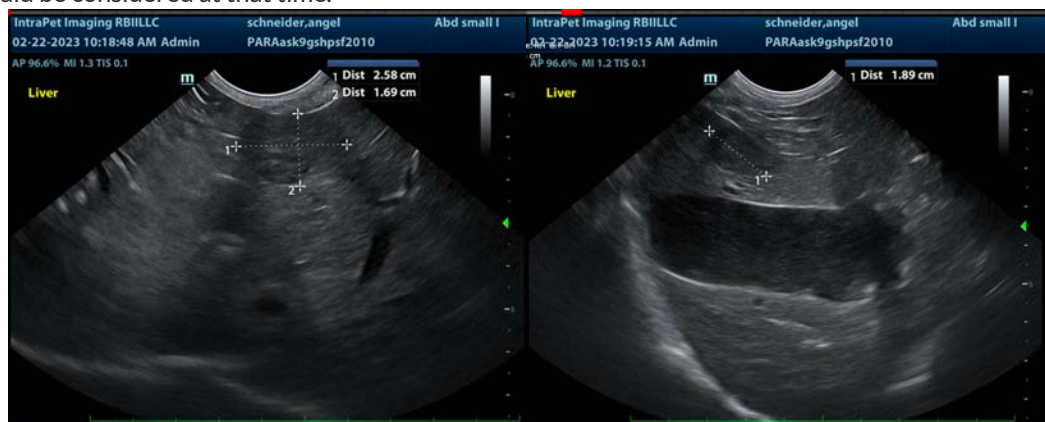
SECONDARY FINDINGS

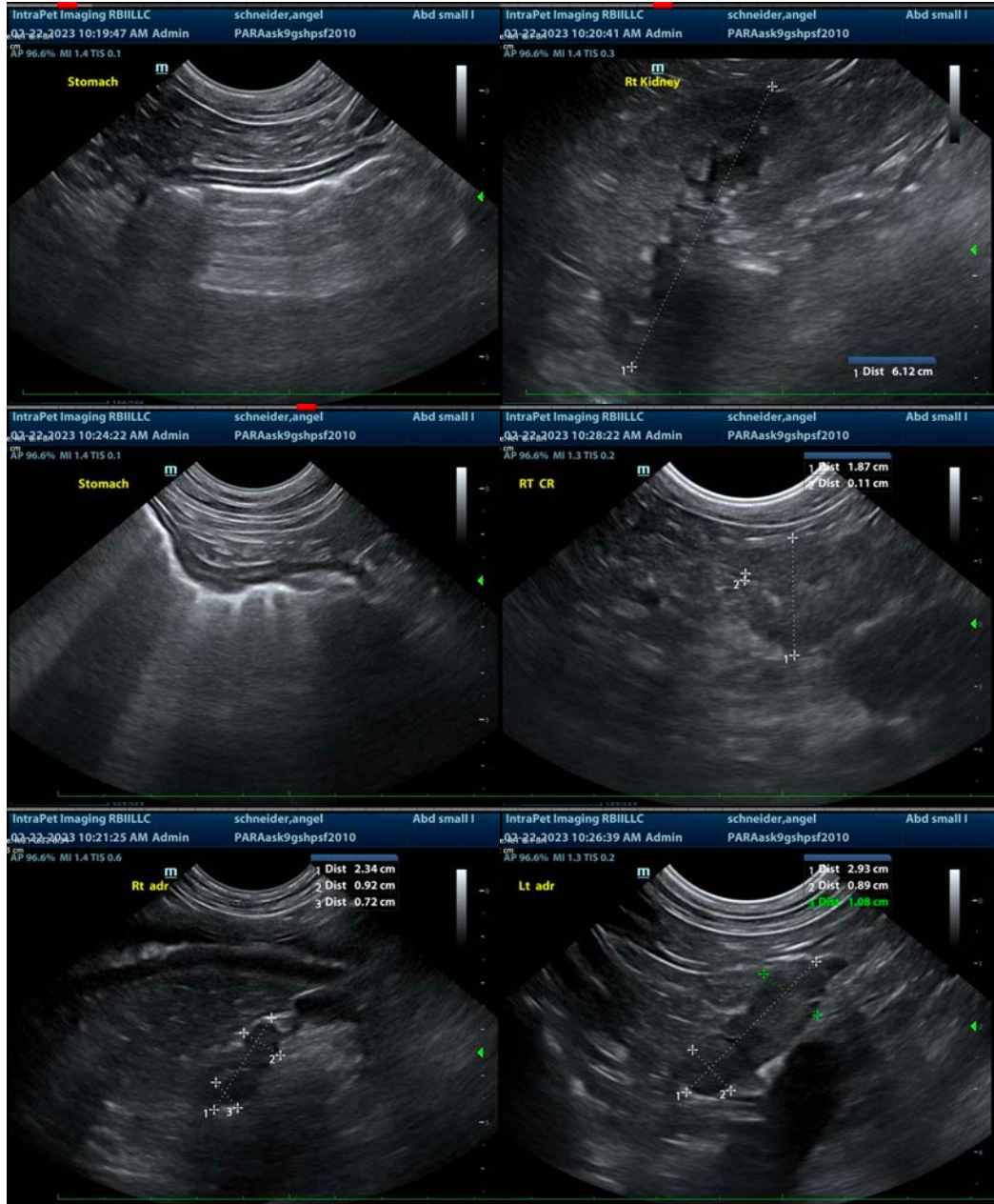
- Age related kidney changes

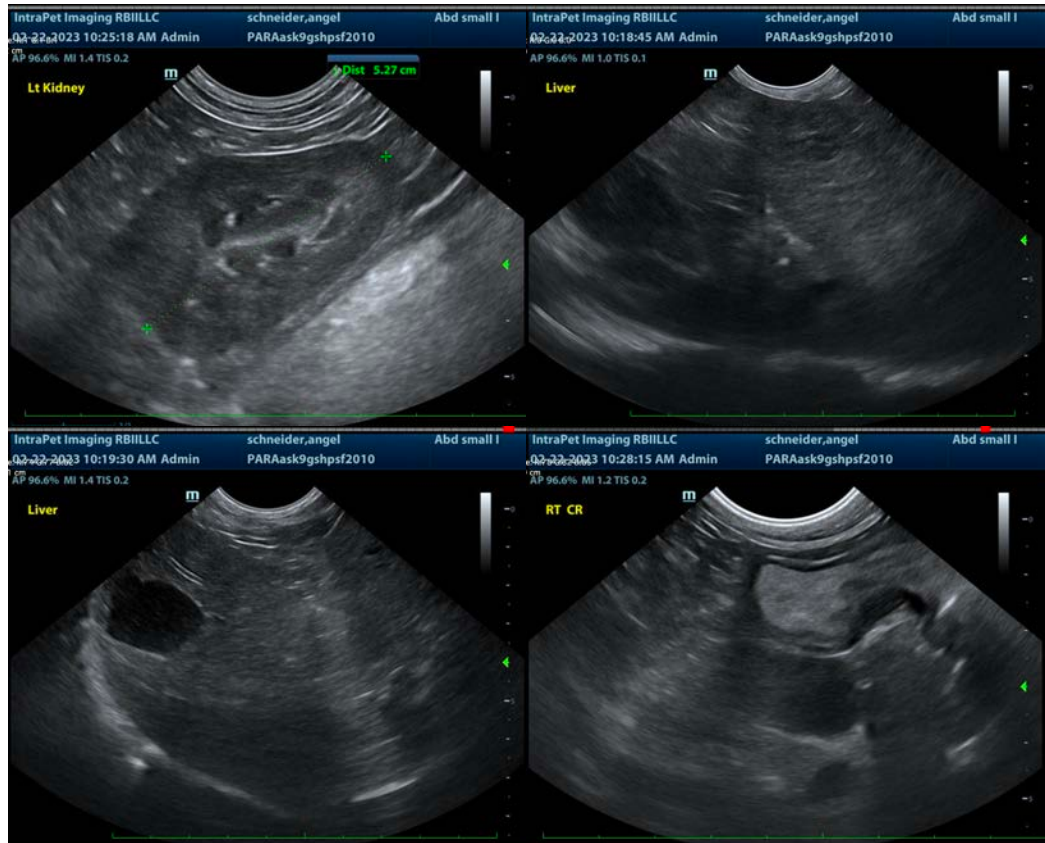
INTERPRETATION OF THE FINDINGS & FURTHER RECOMMENDATIONS

The pathology described above combined with this patient's reported PU/PD, etc. could all be suggestive of hyperadrenocorticism. However, given the hepatocellular injury pattern of increased liver enzymes versus a cholestatic pattern, combined with the marked heterogeneity of the liver, which is slightly more pronounced than typically associated with hyperadrenocorticism alone, a fine needle aspirate of the liver is recommended if patient's coagulation status is appropriate. Additionally, testing for Leptospirosis is recommended.

Pending results of those diagnostics, if clinical signs persist and another underlying reason has not been diagnosed, further testing for hyperadrenocorticism beginning with a low-dose Dexamethasone suppression test could be considered at that time.







The information and recommendations provided are based on the images presented by the referring veterinarian/sonographer. No evaluation can be communicated regarding pathology that was not visible in the image/video clips provided.

Thank you for this referral. If the clinical or image interpretation does not parallel your findings or if I can be of any further assistance please contact me.

Beth Johnson, DVM, DACVIM
Beth.Johnson@sonopath.com