

**DATE**

2/21/23

PRESENTING CLINICAL SIGNS

Diabetic and not doing well. Having uncontrolled urinating and symptoms are not changing even with blood sugar seeming to be well controlled.
Current Medications: None listed.

PATIENT

JJ French

Date of Previous IntraPet Ultrasound: No previous.
Sedation: Not required to complete full diagnostic ultrasound.
Stat Report: Not requested.
Imaging Performed By: Rachel Brillhart, RDMS.

SPECIES

Canine

ULTRASONOGRAPHIC EXAMINATION OF THE ABDOMEN**BREED**

Terrier

Urinary System

Urinary bladder is adequately distended with anechoic contents. No masses, inflammatory changes, echogenic sediment or cystoliths are observed. The urinary bladder, trigone and visible pelvic urethra are normal in thickness with a smooth mucosal surface.

SEX

Neutered male

Prostate (neutered) is normal in size, echotexture and echogenicity for a neutered male.

AGE

6/7/11

The kidneys are normal in size (left kidney 4.97 cm) (right kidney measured 4.77 cm), shape and echogenicity. It has smooth peripheral margination. There is a normal 1:3 cortex to medulla ratio with appropriate corticomedullary distinction. There is no evidence of pyelectasia, mineral or infarcts observed.

WEIGHT

15 lbs

Adrenal Glands

The adrenal glands are normal in size (left adrenal gland 2.27 cm long, 0.74 cm at cranial pole and 0.76 cm at caudal pole) (right adrenal 2.2 cm long, 0.87 cm at the cranial pole and 0.81 cm at the caudal pole), shape and overall architecture, echogenicity and echotexture. Visible surrounding vasculature appears normal.

INTERPRETED BYBeth Johnson, DVM
DACVIM**Spleen**

Spleen is subjectively normal in size with a normal smooth capsular contour. Parenchyma is appropriately finely textured and homogenous with normal echogenicity relative to surrounding tissue (hyperechoic to liver). No focal nodules or masses are observed. Multifocal mineral foci are noted. Splenic vasculature appears normal.

HOSPITAL NAMEHomeward Bound
Veterinary**Liver**

Liver is subjectively enlarged (swollen contour) without disruption of architecture. It has a normal homogenous echotexture. Parenchyma is diffusely hyperechoic characterized by less prominent than normal portal vein walls and increased echogenicity relative to the spleen and falciform fat. No focal lesions are observed. Visible vasculature and biliary tree appear normal without distension or congestion.

REFERRING VET

Dr. Vance

INVOICE

42913

Gallbladder is moderately distended with anechoic bile as well as suspended and gravity dependent echogenic debris. The wall is smooth without visible thickening. There is no evidence of cystic or CBD dilation. There is no evidence of effusion or inflammation.

Gastrointestinal

The visible stomach wall is normal in thickness and layering. The lumen of the stomach is mildly distended with echogenic non-shadowing luminal contents and gas consistent with normal ingesta. There is no evidence of obstruction, foreign material or infiltrative disease. Pyloric outflow tract appears patent.

The visible small intestines are normal in wall thickness and layering. Mild, hyperechoic mucosal fogging or speckling is noted. Small intestinal motility appears adequate (1-3 contractions per min). The lumen of the small intestine is empty with no evidence of obstruction or foreign material.

The visible colon is normal in wall thickness (< 0.2 cm) and layering. Contents are consistent with normal formed feces and gas.

Pancreas

The observed pancreas appears appropriately isoechoic to surrounding omental fat. Visible capsule is smooth and normal in contour. Visible pancreatic parenchyma is homogenous and unremarkable. There is no visible pancreatic duct dilation. There is no evidence of active peripancreatic inflammation.

Free Abdomen

There is no evidence of free peritoneal effusion noted in these images.

There is no apparent lymphadenopathy noted in these images.

ULTRASONOGRAPHIC FINDINGS

- **Hyperechoic hepatomegaly** – This appearance is non-specific and most consistent with a benign steroid (endocrine) or vacuolar hepatopathy or reactive or idiopathic hepatopathy. Inflammatory and/or infiltrative disease (such as round cell neoplasia) are also possible, but considered less likely.
- **Gallbladder debris (canine)** - Cholecystic debris is of unknown clinical significance. It can be seen with biliary stasis from fasting or illness. Cholecystic debris is not necessarily related to hepatobiliary disease. Echogenic bile is most commonly an incidental finding in dogs and should be interpreted in combination with clinical signs such as nausea, inappetence, cranial abdominal discomfort and/or laboratory changes such as increased ALP and/or increased Tbili.
- **Splenic mineralization** – This is a benign change but can be associated with endocrinopathies, especially hyperadrenocorticism.
- **Mucosal speckling** – Mucosal speckling is often present with inflammatory bowel disease (IBD). It is not specific for type or severity of disease. Mild speckling change can occur as a normal patient variant in the post-prandial state.

INTERPRETATION OF THE FINDINGS & FURTHER RECOMMENDATIONS

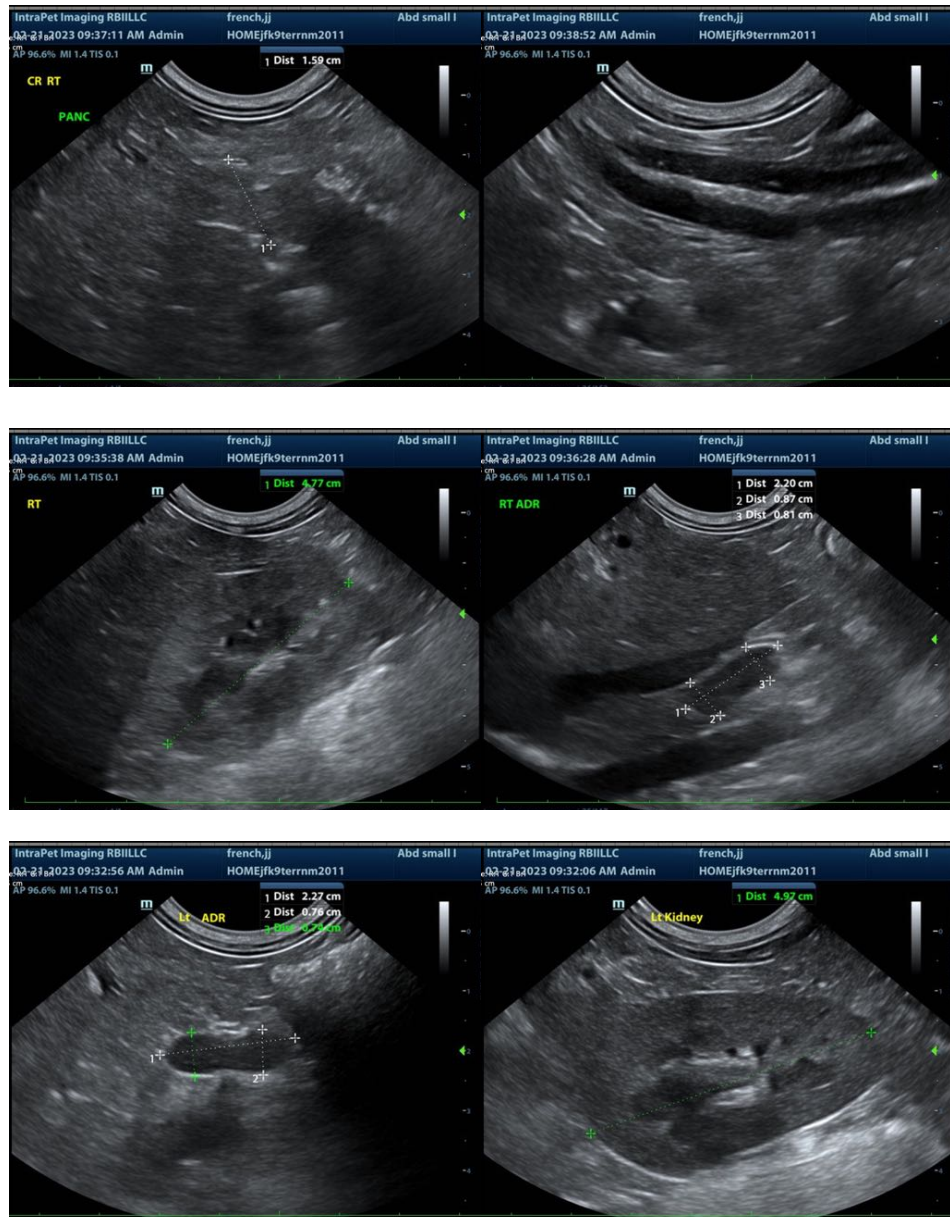
Given the patient's history of diabetes mellitus and reported continued clinical signs, if not recently evaluated:

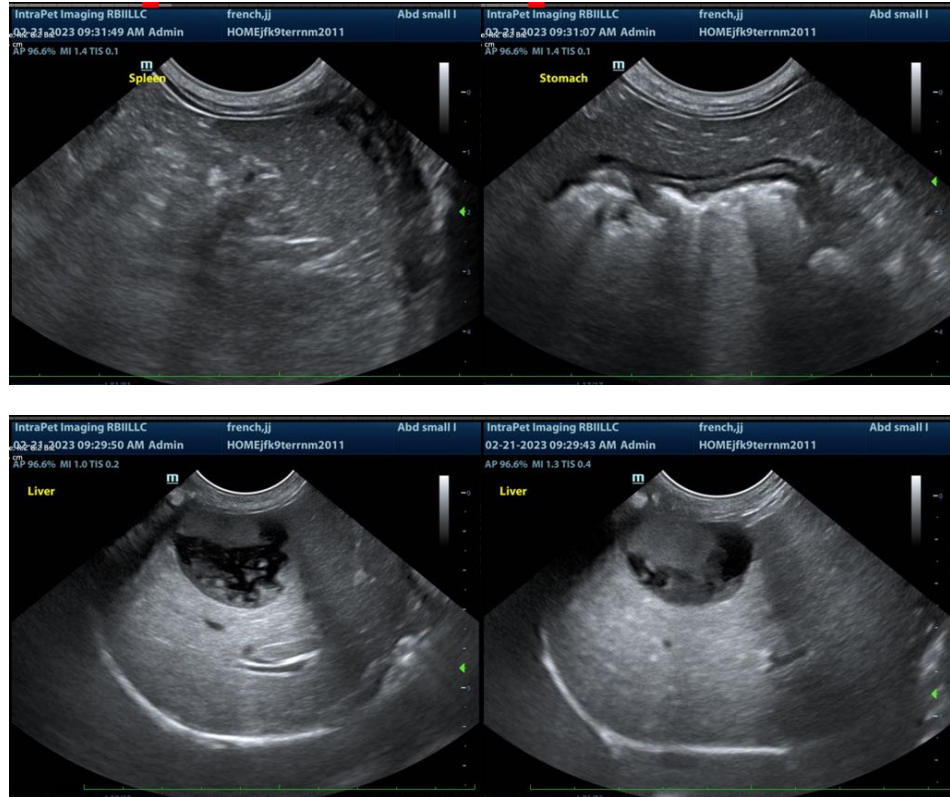
- Urinalysis and, if indicated based on urinalysis results, urine culture are recommended. If protein is present in an otherwise quiet sediment, protein quantification with a urine protein to creatinine ration is recommended.

Depending on how monitoring is currently being done it may be that the checked blood glucoses are appropriate, but the patient is hyperglycemic at other times of the day resulting PU/PD. Therefore, if not already in place more long term monitoring as can be accomplished with placement of a freestyle libre can be considered to assure adequate regulation.

The mucosal speckling is likely a post prandial occurrence in this patient, but if there is a history of gastrointestinal signs other than the weight loss, considered to be caused by diabetes further evaluation of the gastrointestinal tract can be considered with:

- A gastrointestinal malabsorption panel (including cobalamin, folate, TLI and PLI) to Texas A&M GI Laboratory is recommended for further evaluation of GI and pancreatic function.





The information and recommendations provided are based on the images presented by the referring veterinarian. No evaluation can be communicated regarding pathology that was not visible in the image/video clips provided.

Thank you for this referral. If the clinical or image interpretation does not parallel your findings or if I can be of any further assistance please contact me.

Beth Johnson, DVM DACVIM
Info@sonopath.com