



PATIENT

Mia Gasper

SPECIES

Canine

BREED

Lab Mix

SEX

Spayed Female

AGE

12 Years 9 Months

WEIGHT

75 Pounds

INTERPRETED BY

Beth Johnson, DVM
DACVIM

IMAGING PERFORMED BY

Amy Mayhew, LVT

HOSPITAL NAME

SVS Imaging MI

REFERRING VET

Dr. Packard

INVOICE

21217

DATE

2/20/23

PRESENTING CLINICAL SIGNS

History: Presented for recheck liver values after recovering from vestibular episode.

Abnormal PE/Chem/CBC/UA Results: Persistent ALT elevation. Please see attached.

ULTRASONOGRAPHIC EXAMINATION OF THE ABDOMEN

Urinary System

Urinary bladder is adequately distended with anechoic contents. No masses, inflammatory changes, echogenic sediment or cystoliths are observed. The urinary bladder, trigone and visible pelvic urethra are normal in thickness with a smooth mucosal surface.

Left kidney is normal is size (5.96 cm), shape and echogenicity. It has smooth peripheral margination. There is a normal 1:3 cortex to medulla ratio with appropriate corticomedullary distinction. There is no evidence of pyelectasia, mineral or infarcts observed.

Right kidney is normal is size (6.6 cm), shape and echogenicity. It has smooth peripheral margination. There is a normal 1:3 cortex to medulla ratio with appropriate corticomedullary distinction. There is no evidence of pyelectasia, mineral or infarcts observed.

Adrenal Glands

Left adrenal gland is normal in size (0.4 cm at cranial pole and 0.49 cm at caudal pole), shape and overall architecture, echogenicity and echotexture. Visible surrounding vasculature appears normal.

Right adrenal gland is normal in size (0.5 cm at cranial pole and 0.54 cm at caudal pole), shape and overall architecture, echogenicity and echotexture. Visible surrounding vasculature appears normal.

Spleen

Spleen is subjectively normal in size with a normal smooth capsular contour. Parenchyma is appropriately finely textured and homogenous with normal echogenicity relative to surrounding tissue (hyperechoic to liver). No focal nodules or masses are observed. Splenic vasculature appears normal.

Liver

Liver is subjectively normal in size with normal smooth curvilinear peripheral contour. Parenchyma is appropriately hypoechoic to the spleen in echogenicity and appropriately mildly coarse and homogenous in echotexture. A 2.5 cm x 3.5 cm hypoechoic nodule/mass is noted in the deep left liver. Visible vasculature and biliary tree appear normal without distension or congestion.

Gallbladder is moderately distended with anechoic bile as well as mild suspended and gravity dependent echogenic debris. The wall is smooth without visible thickening. There is no evidence of cystic or CBD dilation. There is no evidence of effusion or inflammation.

Gastrointestinal

The visible stomach wall is normal in thickness and layering. The lumen of the stomach is mildly distended with very echogenic reverberation artifact from intraluminal gas. There is no evidence of obstruction, foreign material or infiltrative disease; however, complete visualization of far wall is partially inhibited by gas. Pyloric outflow tract appears patent.



PATIENT

Mia Gasper

The visible small intestines are normal in wall thickness and layering. Small intestinal motility appears adequate (1-3 contractions per min). The lumen of the small intestine is empty with no evidence of obstruction, foreign material or infiltrative disease.

SPECIES

Canine

The visible colon is normal in wall thickness and layering. Contents are consistent with normal formed feces and gas.

Pancreas

BREED

Lab Mix

The observed pancreas appears appropriately isoechoic to surrounding omental fat. Visible capsule is smooth and normal in contour. Visible pancreatic parenchyma is homogenous and unremarkable. There is no visible pancreatic duct dilation. There is no evidence of active peripancreatic inflammation.

Free Abdomen

SEX

Spayed Female

There is no evidence of peritoneal effusion. There is no apparent lymphadenopathy.

ULTRASONOGRAPHIC FINDINGS

AGE

12 Years 9 Months

Primary Findings

- Liver nodule/mass, differentials for which include both benign, as well as infiltrative neoplastic lesions, such as cyst, hematoma, nodular hyperplasia vs primary hepatocellular carcinoma, round cell neoplasia, sarcoma, etc. The differentials cannot be differentiated without tissue sampling.

WEIGHT

75 Pounds

Secondary Findings

- Gallbladder debris - Cholecystic debris is of unknown clinical significance. It can be seen with biliary stasis from fasting or illness. Cholecystic debris is not necessarily related to hepatobiliary disease. Echogenic bile is most commonly an incidental finding in dogs and should be interpreted in combination with clinical signs such as nausea, inappetence, cranial abdominal discomfort and/or laboratory changes such as increased ALP and/or increased Tbili.

INTERPRETED BY

Beth Johnson, DVM
DACVIM

INTERPRETATION OF THE FINDINGS & FURTHER RECOMMENDATIONS

Three view thoracic radiographs are recommended for further assessment of cardio-pulmonary status as well as to further evaluate for any evidence of metastatic disease, if not recently evaluated.

IMAGING PERFORMED BY

Amy Mayhew, LVT

Ideally, a fine needle aspirate of the liver nodule/mass would be obtained if patients coagulation status is appropriate, however, given the small size and deep position, an aspirate may not be able to be safely obtained, in which case options include monitoring, beginning with a recheck ultrasound in 4-6 weeks to assess any progression (if present) vs an exploratory laparotomy for planned biopsy/mass removal.

HOSPITAL NAME

SVS Imaging MI

REFERRING VET

Dr. Packard

Additionally, given that this liver nodule could represent a benign incidental change, further evaluation of the increased liver enzymes, including testing for leptospirosis, in the meantime, is also recommended.

INVOICE

21217

DATE

2/20/23



PATIENT

Mia Gasper

SPECIES

Canine

BREED

Lab Mix

SEX

Spayed Female

AGE

12 Years 9 Months

WEIGHT

75 Pounds

INTERPRETED BY

Beth Johnson, DVM
DACVIM

IMAGING PERFORMED BY

Amy Mayhew, LVT

HOSPITAL NAME

SVS Imaging MI

REFERRING VET

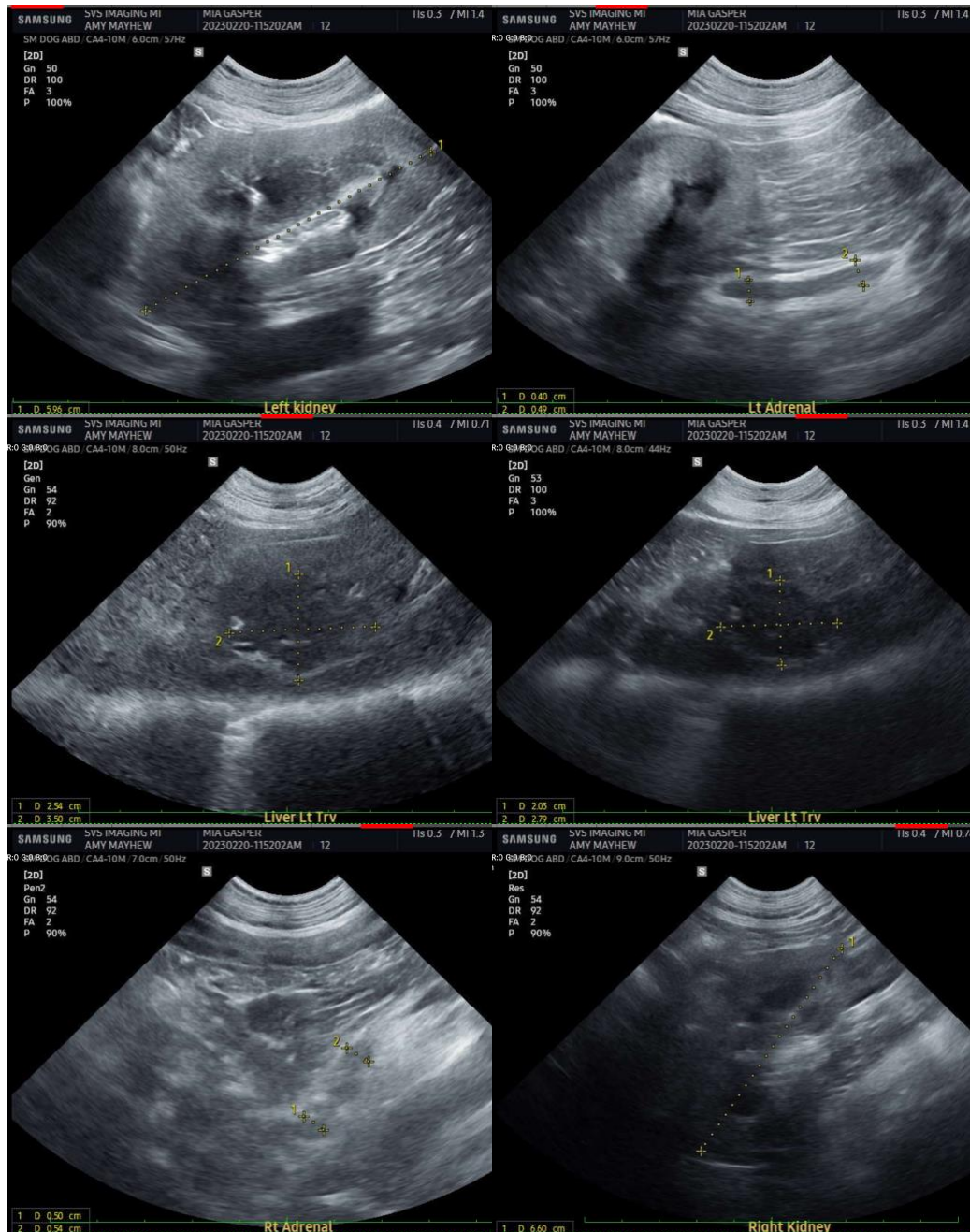
Dr. Packard

INVOICE

21217

DATE

2/20/23





PATIENT

Mia Gasper

SPECIES

Canine

BREED

Lab Mix

SEX

Spayed Female

AGE

12 Years 9 Months

WEIGHT

75 Pounds

INTERPRETED BY

Beth Johnson, DVM
DACVIM

IMAGING PERFORMED BY

Amy Mayhew, LVT

HOSPITAL NAME

SVS Imaging MI

REFERRING VET

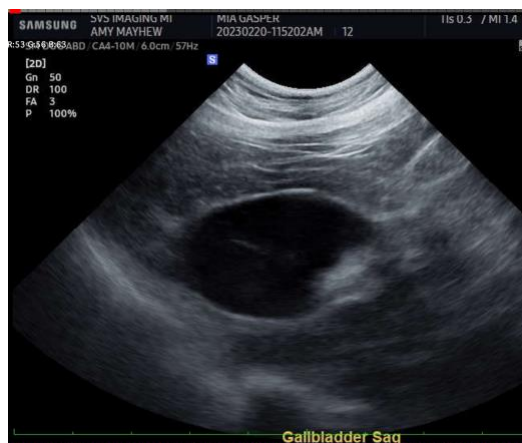Dr. Packard

INVOICE

21217

DATE

2/20/23



The information and recommendations provided are based on the images presented by the referring veterinarian. No evaluation can be communicated regarding pathology that was not visible in the image/video clips provided.

Thank you for this referral. If the clinical or image interpretation does not parallel your findings or if I can be of any further assistance please contact me.

Beth Johnson, DVM DACVIM

Beth.Johnson@SonoPath.com