



PATIENT

Toby Banom

SPECIES

Canine

BREED

Yorkiepool

SEX

Neutered Male

AGE

12 Years

WEIGHT

14.3 Pounds

INTERPRETED BY

Beth Johnson, DVM
DACVIM

IMAGING PERFORMED BY

Shari Reffi, CVT

HOSPITAL NAME

Ridge Road AH

REFERRING VET

Dr. Pathak

INVOICE

44734

DATE

2/2/23

PRESENTING CLINICAL SIGNS

Abdominal mass on PE 2/1/2023. No current meds.
Abnormal PE/Chem/CBC/UA Results: Hypocalcemia 6.4

ULTRASONOGRAPHIC EXAMINATION OF THE ABDOMEN

Urinary System

The urinary bladder is moderately distended with anechoic contents. No masses, inflammatory changes, echogenic sediment or cystoliths are observed. The urinary bladder, trigone and visible pelvic urethra are normal in thickness with a smooth mucosal surface.

Prostate is normal in size, echotexture and echogenicity for a neutered male.

Kidneys are overall normal in size and shape with smooth peripheral margination. A normal 1:3 cortex to medulla ratio is maintained. The medulla and cortices are uniform in texture with some mild increased cortical echogenicity and mild loss of corticomedullary distinction, expected in this age patient. There is no evidence of pyelectasia, mineral or infarcts observed. The right kidney measures 4.73 cm. The left kidney measures 4.53 cm.

Adrenal Glands

The right adrenal gland is normal in size (1.82 cm long x 0.66 cm at the cranial pole and 0.79 cm at the caudal pole), shape and contour. Corticomedullary structure is unremarkable. Visible surrounding vasculature appears normal.

The left adrenal gland is normal in size (1.33 cm long x 0.42 cm at the cranial pole and 0.44 cm at the caudal pole), shape and contour. Corticomedullary structure is unremarkable. Visible surrounding vasculature appears normal.

Spleen

The spleen contains a large 5.6 cm x 6.0 cm mixed heterogeneous, primarily hypoechoic, partially cavitated capsule disrupting mass off the tail of the spleen.

Liver

The liver is subjectively normal in size with normal smooth curvilinear peripheral contour. Parenchyma is appropriately hypoechoic to the spleen in echogenicity and appropriately mildly coarse and homogenous in echotexture. No focal lesions are observed. Visible vasculature and biliary tree appear normal without distension or congestion.

The gallbladder is non-distended in size. The wall is smooth without visible thickening. Luminal contents are primarily anechoic. There is no evidence of cystic or common bile duct dilation.

Gastrointestinal

The stomach wall is normal in thickness (canine < 0.5 cm and feline < 0.4 cm) and layering. The lumen of the stomach is empty with no evidence of obstruction, foreign material or infiltrative disease. Pyloric outflow tract appears patent.

The visible small intestines are normal in wall thickness and layering (canine duodenum < 0.5 cm and feline duodenum < 0.4 cm; other < 0.3 cm). Small intestinal motility appears adequate (1-3 contractions per min). The lumen of the small intestine is empty with no evidence of obstruction, foreign material or infiltrative disease.



PATIENT

Toby Banom

The visible colon is normal in wall thickness (< 0.2 cm) and layering. Contents are consistent with normal formed feces and gas.

SPECIES

Canine

Pancreas

The observed pancreas appears appropriately isoechoic to surrounding omental fat. The capsule is mildly irregular in shape. Parenchyma is mildly heterogenous and coarse. There is no visible pancreatic duct dilation. There is no evidence of active peripancreatic inflammation.

BREED

Yorkiepoo

Free Abdomen

There is no evidence of free peritoneal effusion noted in these images.

SEX

Neutered Male

There is no apparent lymphadenopathy noted in these images.

AGE

12 Years

PRIMARY FINDINGS

- Splenic mass – Concerning for infiltrative neoplasia such as sarcoma. Other neoplasia including infiltrative round cell neoplasia, other are also possible. Benign lesions including extramedullary hematopoiesis, hematomas, etc. however can mimic malignant lesions and cannot be ruled out or differentiated without tissue sampling.

WEIGHT

14.3 Pounds

ULTRASONOGRAPHIC FINDINGS

- Age related kidney changes
- **Pancreatic age-related remodeling** – Mild irregularities are consistent with benign age-related change. Low-grade smoldering chronic pancreatitis cannot be ruled out and should be suspected in the face of appropriate clinical signs.

INTERPRETED BY

Beth Johnson, DVM
DACVIM

INTERPRETATION OF THE FINDINGS & FURTHER RECOMMENDATIONS

Three view thoracic radiographs are recommended for further assessment of cardio-pulmonary status as well as to further evaluate for any evidence of metastatic disease, if not recently evaluated.

IMAGING PERFORMED BY

Shari Reffi, CVT

HOSPITAL NAME

Ridge Road AH

An exploratory laparotomy for planned splenectomy with submission of mass for histopathology is recommended. A fine needle aspirate of the mass could be considered for diagnosis prior to surgery. However, given the risk of hemorrhage, etc. with even benign splenic tumors, ultimately resection is recommended despite the diagnosis.

REFERRING VET

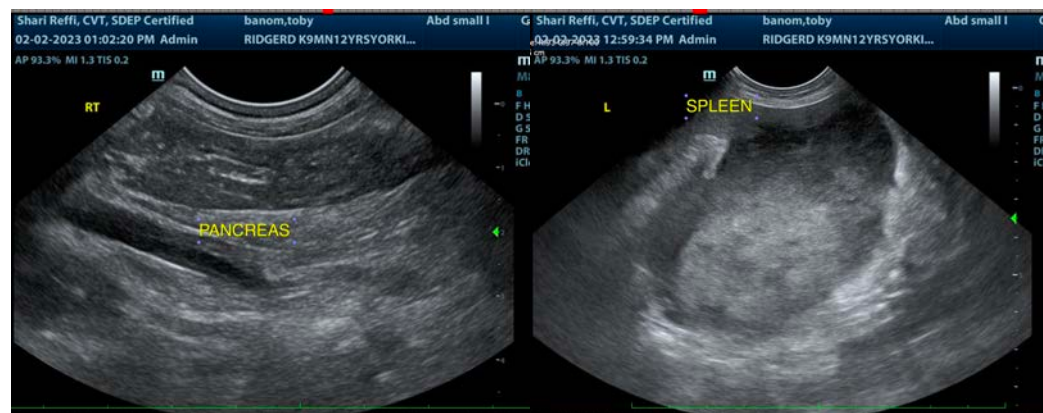
Dr. Pathak

INVOICE

44734

DATE

2/2/23





PATIENT

Toby Banom

SPECIES

Canine

BREED

Yorkiepoop

SEX

Neutered Male

AGE

12 Years

WEIGHT

14.3 Pounds

INTERPRETED BY

Beth Johnson, DVM
DACVIM

IMAGING PERFORMED BY

Shari Reffi, CVT

HOSPITAL NAME

Ridge Road AH

REFERRING VET

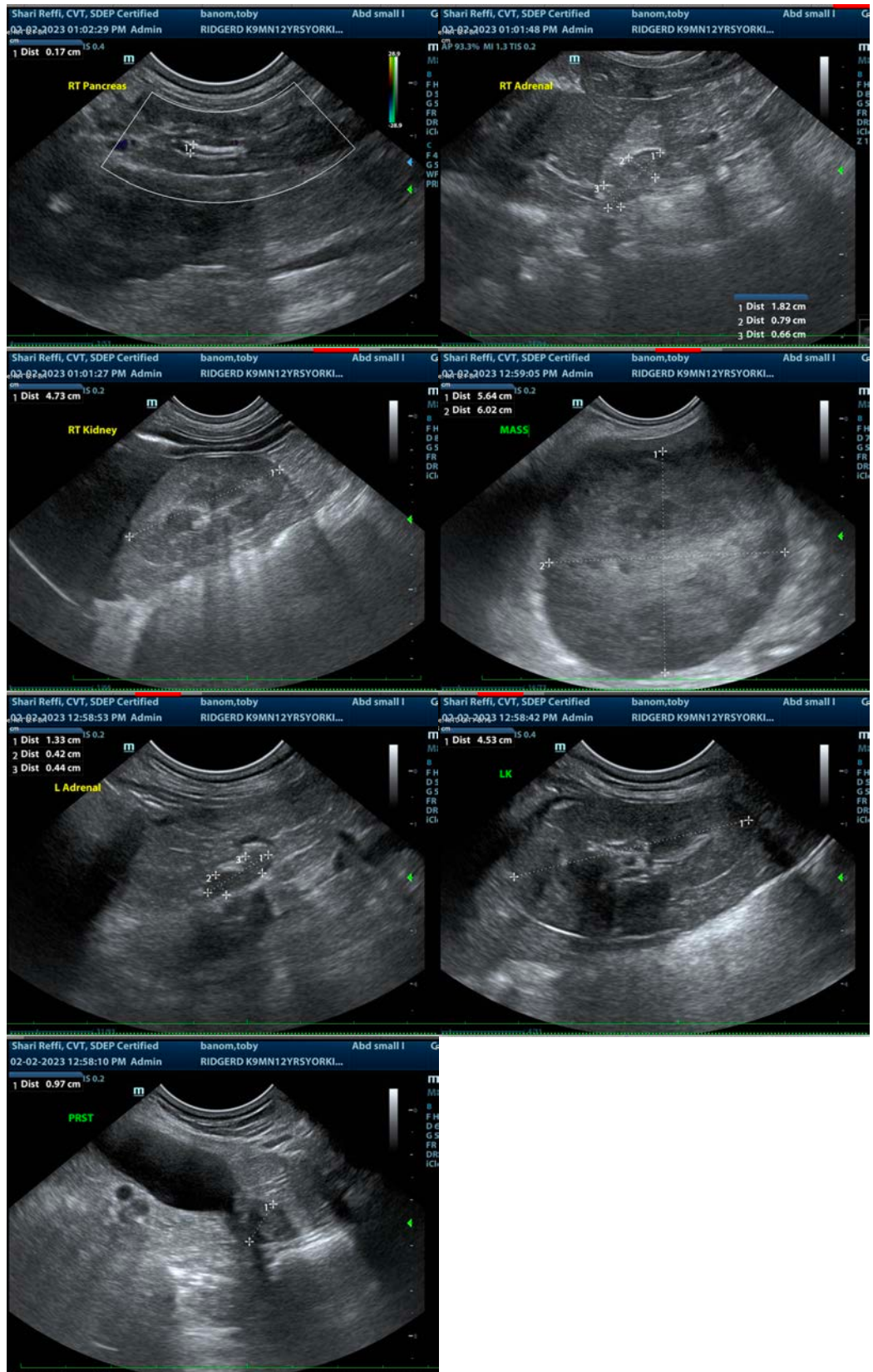
Dr. Pathak

INVOICE

44734

DATE

2/2/23





PATIENT

Toby Banom

The information and recommendations provided are based on the images presented by the referring veterinarian/sonographer. No evaluation can be communicated regarding pathology that was not visible in the image/video clips provided.

SPECIES

Canine

Thank you for this referral. If the clinical or image interpretation does not parallel your findings or if I can be of any further assistance please contact me.

BREED

Yorkiepool

Beth Johnson, DVM, DACVIM

Beth.Johnson@sonopath.com

SEX

Neutered Male

AGE

12 Years

WEIGHT

14.3 Pounds

INTERPRETED BY

Beth Johnson, DVM
DACVIM

**IMAGING
PERFORMED BY**

Shari Reffi, CVT

HOSPITAL NAME

Ridge Road AH

REFERRING VET

Dr. Pathak

INVOICE

44734

DATE

2/2/23