

**PATIENT**

Hans Helfen

**SPECIES**

Canine

**BREED**

Dachshund

**SEX**

Neutered Male

**AGE**

10 Years

**WEIGHT**

23.2 Pounds

**INTERPRETED BY**Beth Johnson, DVM  
DACVIM**IMAGING PERFORMED BY**

Amy Mayhew, LVT

**HOSPITAL NAME**

SVS Imaging MI

**REFERRING VET**

Dr. Jason Rivas

**INVOICE**

44727

**DATE**

2/2/23

**PRESENTING CLINICAL SIGNS**

Presented to our office on 12/27/22 for vomiting &amp; recheck protein levels.

Abnormal PE/Chem/CBC/UA Results: We ran a Total Protein Panel and Urinalysis with UPC on 12/27/22 - results for both are attached with patient file. UA results were normal, showing no protein loss in the urine. Protein Panel showed that all protein levels are mildly decreased.

**ULTRASONOGRAPHIC EXAMINATION OF THE ABDOMEN****Urinary System**

The urinary bladder is moderately distended with anechoic contents. No masses, inflammatory changes, echogenic sediment or cystoliths are observed. The urinary bladder, trigone and visible pelvic urethra are normal in thickness with a smooth mucosal surface.

Prostate is normal in size, echotexture and echogenicity for a neutered male.

The right kidney is normal in size (5.6 cm), shape and echogenicity. It has smooth peripheral margination. There is a normal 1:3 cortex to medulla ratio with appropriate corticomedullary distinction. There is no evidence of pyelectasia, mineral or infarcts observed.

The left kidney is normal in size (5.16 cm), shape and echogenicity. It has smooth peripheral margination. There is a normal 1:3 cortex to medulla ratio with appropriate corticomedullary distinction. There is no evidence of pyelectasia, mineral or infarcts observed.

**Adrenal Glands**

The right adrenal gland is normal in size (0.61 cm at the cranial pole and 0.68 cm at the caudal pole), shape and contour. Corticomedullary structure is unremarkable. Visible surrounding vasculature appears normal.

The left adrenal gland is normal in size (0.61 cm at the cranial pole and 0.60 cm at the caudal pole), shape and contour. Corticomedullary structure is unremarkable. Visible surrounding vasculature appears normal.

**Spleen**

The spleen is subjectively normal in size with a normal smooth capsular contour. Parenchyma is appropriately finely textured and homogenous with normal echogenicity relative to surrounding tissue (hyperechoic to liver). No focal nodules or masses are observed. Splenic vasculature appears normal.

**Liver**

The liver is subjectively normal in size with normal smooth curvilinear peripheral contour. Parenchyma is appropriately hypoechoic to the spleen in echogenicity and appropriately mildly coarse and homogenous in echotexture. No focal lesions are observed. Visible vasculature and biliary tree appear normal without distension or congestion.

Gallbladder is moderately distended with anechoic bile as well as mild to moderate suspended and gravity dependent echogenic debris. The wall is smooth without visible thickening. There is no evidence of cystic or CBD dilation. There is no evidence of effusion or inflammation.

**Gastrointestinal**

The visible stomach wall is normal in thickness and layering. The lumen of the stomach is mildly distended with echogenic non-shadowing luminal contents and gas consistent with normal ingesta.

## IMAGING PERFORMED BY

SVS Mobile Imaging MI 734-637-7711  
svsimagingmi@gmail.com



### PATIENT

Hans Helfen

There is no evidence of obstruction, foreign material or infiltrative disease. Pyloric outflow tract appears patent.

### SPECIES

Canine

Small intestine is diffusely mildly thick with a relatively thick mucosa compared to other layers. Normal wall layering is preserved; however, the mucosa is more echogenic than normal and contains hyperechoic striations perpendicular to the lumen. The lumen is empty with no evidence of obstruction or foreign material.

### BREED

Dachshund

The visible colon is normal in wall thickness (< 0.2 cm) and layering. Contents are consistent with normal formed feces and gas.

### SEX

Neutered Male

### *Pancreas*

The pancreatic parenchyma is appropriately isoechoic to surrounding tissue. Visible capsule is smooth and normal in contour. There is no visible pancreatic duct dilation. There is no evidence of active peripancreatic inflammation.

### AGE

10 Years

### *Free Abdomen*

A very scant amount of anechoic free fluid is noted.

There is no apparent lymphadenopathy noted in these images.

### WEIGHT

23.2 Pounds

### PRIMARY FINDINGS

- **Lymphangiectasia** – Small bowel findings are most consistent with lacteal dilation. These findings can be observed with protein-losing enteropathies caused by either primary lymphangiectasia or primary infiltrative inflammatory disease with secondary lymphangiectasia. Infiltrative neoplasia is possible but considered less likely. Histopathology is necessary to definitively determine underlying cause.
- **Scant amount of anechoic free fluid** – Likely secondary to this patient's reported hypoalbuminemia.

### INTERPRETED BY

Beth Johnson, DVM  
DACVIM

### SECONDARY FINDINGS

- **Mild to moderate gallbladder debris** - Cholecystic debris is of unknown clinical significance. It can be seen with biliary stasis from fasting or illness. Cholecystic debris is not necessarily related to hepatobiliary disease. Echogenic bile is most commonly an incidental finding in dogs and should be interpreted in combination with clinical signs such as nausea, inappetence, cranial abdominal discomfort and/or laboratory changes such as increased ALP and/or increased Tbili.

### IMAGING PERFORMED BY

Amy Mayhew, LVT

### HOSPITAL NAME

SVS Imaging MI

### INTERPRETATION OF THE FINDINGS & FURTHER RECOMMENDATIONS

### REFERRING VET

Dr. Jason Rivas

A gastrointestinal malabsorption panel (including cobalamin, folate, TLI and PLI) to Texas A&M GI Laboratory is recommended for further evaluation of GI and pancreatic function.

Ideally, biopsies of the GI tract are recommended to definitively diagnose and therefore manage the infiltrative bowel process.

### INVOICE

44727

If biopsies cannot be obtained safely due to low albumin or patient stability, etc., empirical therapies could include diet change to an ultra-low fat diet, empirical deworming with a 5 day course of Panacur, cobalamin supplementation (unless cobalamin level is evaluated and supplementation is not warranted) a probiotic and prednisolone (if not contraindicated based on patient contraindications, co-morbidities, etc.). Calcium monitoring, and supplementation if necessary, is also recommended.

### DATE

2/2/23

**IMAGING PERFORMED BY**

SVS Mobile Imaging MI 734-637-7711  
svsimagingmi@gmail.com



**PATIENT**

Hans Helfen

**SPECIES**

Canine

**BREED**

Dachshund

**SEX**

Neutered Male

**AGE**

10 Years

**WEIGHT**

23.2 Pounds

**INTERPRETED BY**

Beth Johnson, DVM  
DACVIM

**IMAGING PERFORMED BY**

Amy Mayhew, LVT

**HOSPITAL NAME**

SVS Imaging MI

**REFERRING VET**

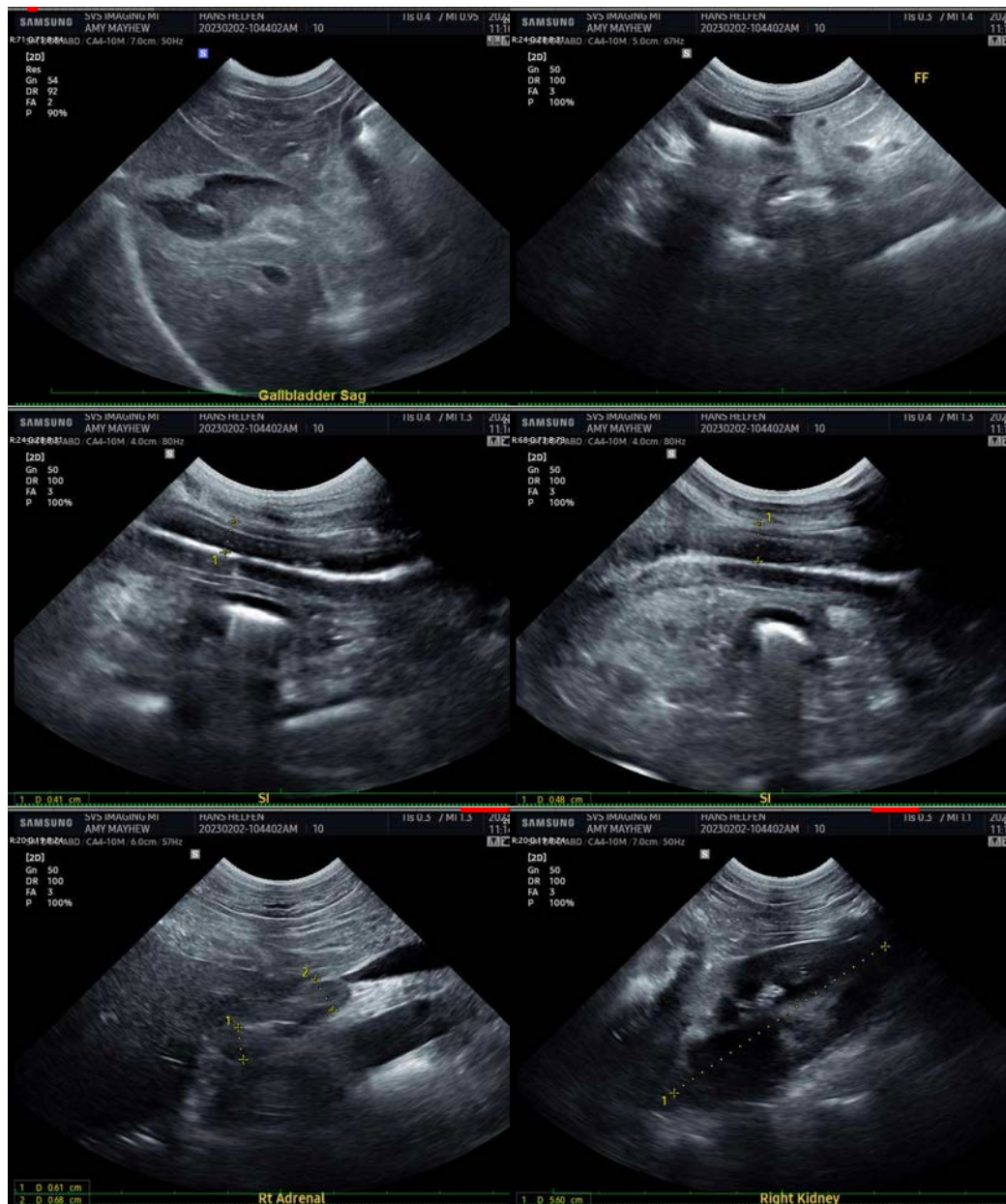
Dr. Jason Rivas

**INVOICE**

44727

**DATE**

2/2/23



**IMAGING PERFORMED BY**

SVS Mobile Imaging MI 734-637-7711  
svsimagingmi@gmail.com



**Clinical Sonography & Telecytology**

EDUCATIONAL TELECONSULTATION SERVICES™

1-800-838-4268 info@sonopath.com SonoPath.com

**PATIENT**

Hans Helfen

**SPECIES**

Canine

**BREED**

Dachshund

**SEX**

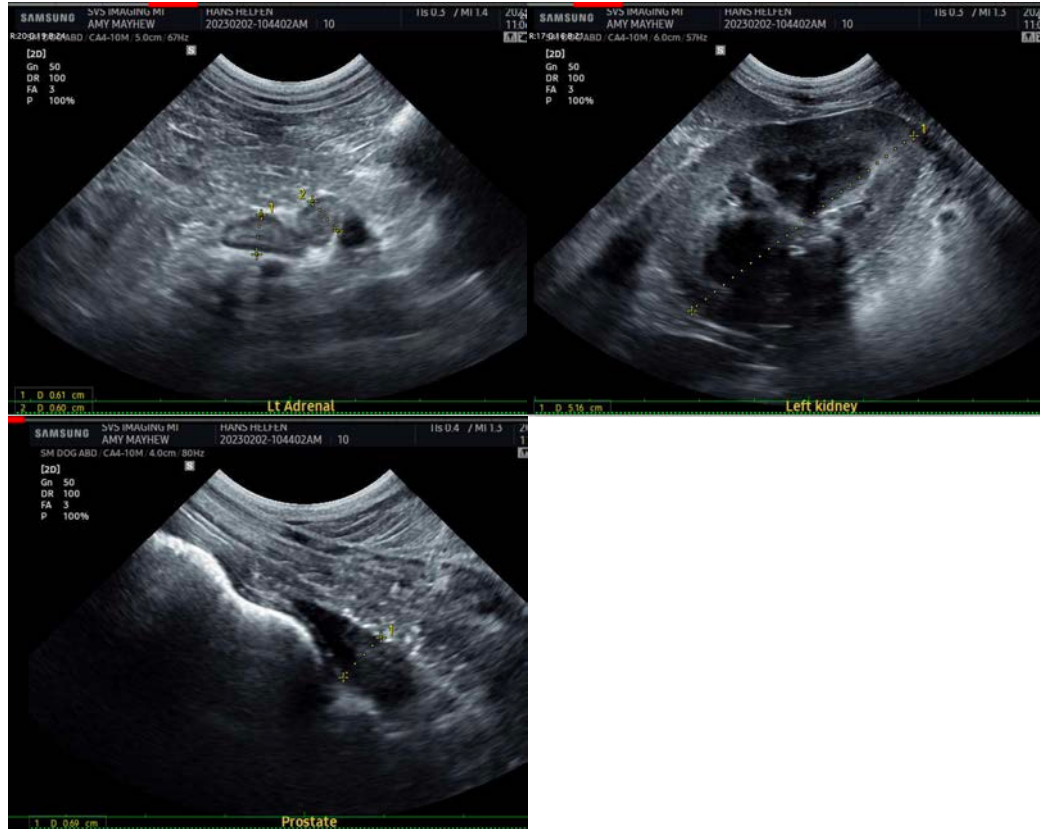
Neutered Male

**AGE**

10 Years

**WEIGHT**

23.2 Pounds



**INTERPRETED BY**

Beth Johnson, DVM  
DACVIM

**IMAGING PERFORMED BY**

Amy Mayhew, LVT

**HOSPITAL NAME**

SVS Imaging MI

**REFERRING VET**

Dr. Jason Rivas

**INVOICE**

44727

**DATE**

2/2/23

The information and recommendations provided are based on the images presented by the referring veterinarian/sonographer. No evaluation can be communicated regarding pathology that was not visible in the image/video clips provided.

Thank you for this referral. If the clinical or image interpretation does not parallel your findings or if I can be of any further assistance please contact me.

**Beth Johnson, DVM, DACVIM**  
Beth.Johnson@sonopath.com