

**PATIENT**

Chuey Fazio

PRESENTING CLINICAL SIGNS

Anorexia and lethargic

SPECIES

Canine

Abnormal PE/Chem/CBC/UA Results: Mass palpated mid abdomen. Radiograph confirms mass-suspect enlarged left kidney with stones in bladder and ureter.

BREED

Dachshund

ULTRASONOGRAPHIC EXAMINATION OF THE ABDOMEN**Urinary System**

The urinary bladder is moderately distended with anechoic contents. No masses or inflammatory changes. A 1.2 cm cystolith is noted along the dependent inner wall. The urinary bladder, trigone and visible pelvic urethra are normal in thickness with a smooth mucosal surface.

SEX

Neutered Male

The area of the prostate is examined without evident prostatic pathology.

AGE

15 Years

The right kidney is normal in size (4.99 cm), shape and echogenicity. It has smooth peripheral margination. There is a normal 1:3 cortex to medulla ratio with appropriate corticomedullary distinction. There is no evidence of infarcts. Multiple non-obstructive nephroliths are present as well as multiple small cortical cysts. Pyelectasia measuring 0.57 cm noted in the transverse view, as well as hydroureter. The proximal ureter measures 0.53 cm and is dilated all the way to the presence of a ureterolith. Multiple small ureteroliths are present aside from the apparent obstructive one.

WEIGHT

11.7 Pounds

Adrenal Glands

The right adrenal gland is normal in size (0.50 cm at the cranial pole and 0.50 cm at the caudal pole), shape and contour. Corticomedullary structure is unremarkable. Visible surrounding vasculature appears normal.

INTERPRETED BYBeth Johnson, DVM
DACVIM

The left adrenal gland is normal in size (0.72 cm at the cranial pole and 0.53 cm at the caudal pole), shape and contour. Corticomedullary structure is unremarkable. Visible surrounding vasculature appears normal.

IMAGING PERFORMED BY

Amy Mayhew, LVT

Spleen

Spleen is subjectively normal in size with a normal smooth capsular contour. Parenchyma is appropriately finely textured and homogenous with normal echogenicity relative to surrounding tissue (hyperechoic to liver). Multifocal well-demarcated hyperechoic homogenous nodules are noted. Splenic vasculature appears normal.

HOSPITAL NAME

SVS Imaging MI

Liver

Liver is subjectively enlarged with mildly irregular margins. Parenchyma is heterogenous characterized by multiple poorly defined hypoechoic nodules within otherwise hyperechoic liver parenchyma. Visible vasculature and biliary tree appear normal without distension or congestion.

REFERRING VET

Dr. Amy Kallin

INVOICE

44752

Gallbladder is moderately distended with anechoic bile as well as mild suspended and gravity dependent echogenic debris. The wall is smooth without visible thickening. There is no evidence of cystic or CBD dilation. There is no evidence of effusion or inflammation.

DATE

2/2/23

Gastrointestinal

The visible stomach wall is normal in thickness and layering. The lumen of the stomach is mildly distended with echogenic non-shadowing luminal contents and gas consistent with normal ingesta.

IMAGING PERFORMED BY

SVS Mobile Imaging MI 734 - 637 - 7711
svsimagingmi@gmail.com

**PATIENT**

Chuey Fazio

There is no evidence of obstruction, foreign material or infiltrative disease. Pyloric outflow tract appears patent.

SPECIES

Canine

The visible small intestines are normal in wall thickness and layering. Hyperechoic mucosal fogging or speckling is noted. Small intestinal motility appears adequate (1-3 contractions per min). The lumen is empty with no evidence of obstruction or foreign material.

BREED

Dachshund

The visible colon is normal in wall thickness (< 0.2 cm) and layering. Contents are consistent with normal formed feces and gas.

Pancreas**SEX**

Neutered Male

The observed pancreas appears appropriately isoechoic to surrounding omental fat. The capsule is mildly irregular in shape. Parenchyma is mildly heterogenous and coarse. There is no visible pancreatic duct dilation. There is no evidence of active peripancreatic inflammation.

Free Abdomen**AGE**

15 Years

There is no evidence of free peritoneal effusion noted in these images.

There is no apparent lymphadenopathy noted in these images.

PRIMARY FINDINGS**WEIGHT**

11.7 Pounds

- Urinary bladder cystolith
- Non-obstructive nephroliths in the right kidney, as well as ureteroliths, including an obstructive ureterolith, hydroureter, and pyelectasia (likely secondary to the obstruction)
- Completely hydronephrosed left kidney with no remaining normal architecture, presumably secondary to migrating ureteroliths on that side as well.
- **Mucosal speckling** – Mucosal speckling is often present with inflammatory bowel disease (IBD). It is not specific for type or severity of disease. Mild speckling change can occur as a normal patient variant in the post-prandial state.
- **Heterogenous Liver** – These changes are most consistent with benign processes such as nodular hyperplasia, steroid (vacuolar) hepatopathy, extramedullary hematopoiesis or possibly chronic inflammatory disease and less commonly infiltrative round cell or metastatic neoplasia.

INTERPRETED BY

Beth Johnson, DVM
DACVIM

IMAGING PERFORMED BY

Amy Mayhew, LVT

HOSPITAL NAME

SVS Imaging MI

REFERRING VET

Dr. Amy Kallin

INVOICE

44752

DATE

2/2/23

SECONDARY FINDINGS

- **Hyperechoic splenic nodules** – most consistent with benign myelolipomas. Other differentials such as fibrosis or calcification caused by old hematomas or infarcts, chronic inflammation, granulomatous disease or metastatic disease cannot be ruled out, but are considered less likely.
- **Mild gallbladder debris** - Cholecystic debris is of unknown clinical significance. It can be seen with biliary stasis from fasting or illness. Cholecystic debris is not necessarily related to hepatobiliary disease. Echogenic bile is most commonly an incidental finding in dogs and should be interpreted in combination with clinical signs such as nausea, inappetence, cranial abdominal discomfort and/or laboratory changes such as increased ALP and/or increased Tbili.
- **Pancreatic age-related remodeling** – Mild irregularities are consistent with benign age-related change. Low-grade smoldering chronic pancreatitis cannot be ruled out and should be suspected in the face of appropriate clinical signs.

IMAGING PERFORMED BY

SVS Mobile Imaging MI 734 - 637 - 7711
svsimagingmi@gmail.com



PATIENT

Chuey Fazio

SPECIES

Canine

BREED

Dachshund

SEX

Neutered Male

AGE

15 Years

WEIGHT

11.7 Pounds

INTERPRETED BY

Beth Johnson, DVM
DACVIM

IMAGING PERFORMED BY

Amy Mayhew, LVT

HOSPITAL NAME

SVS Imaging MI

REFERRING VET

Dr. Amy Kallin

INVOICE

44752

DATE

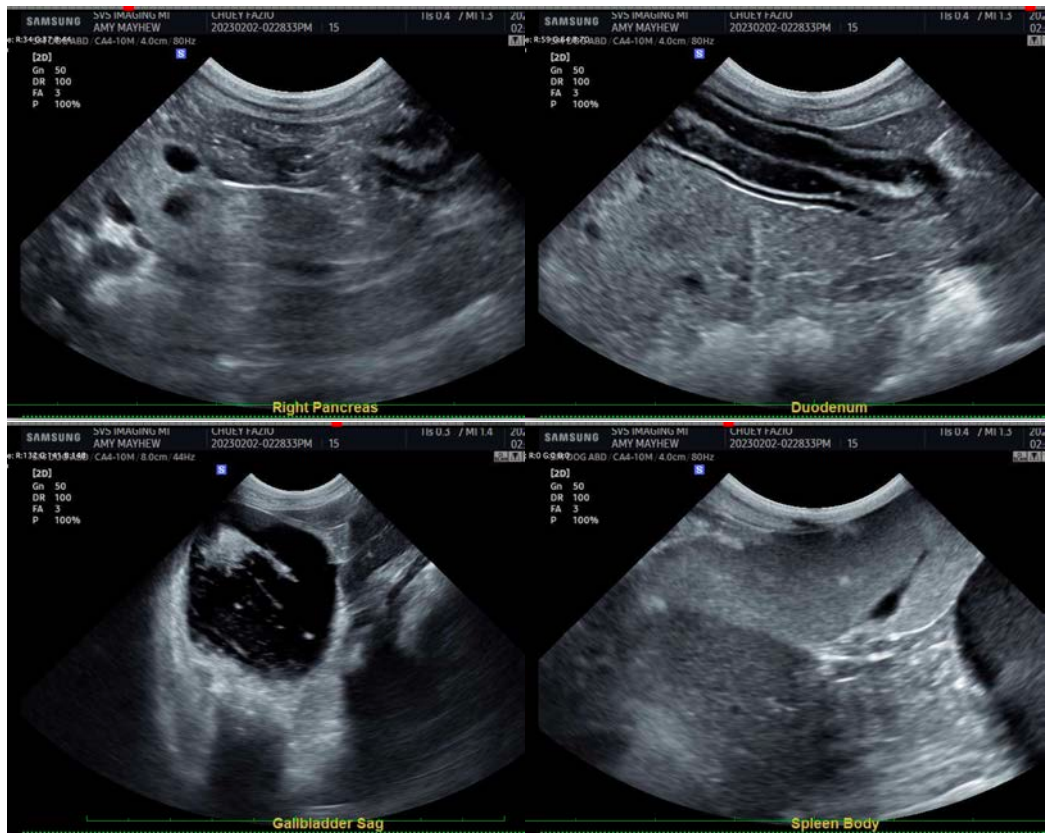
2/2/23

INTERPRETATION OF THE FINDINGS & FURTHER RECOMMENDATIONS

If not recently evaluated, a general metabolic health screen is recommended to further assess this patient's kidney function, beginning with a CBC/Chem panel, electrolytes, and a urinalysis and, if indicated based on urinalysis results, urine culture. If protein is present in an otherwise quiet sediment, protein quantification with a urine protein to creatinine ration is recommended.

Given the ultrasonographic appearance of the kidneys, the left kidney is likely not functioning at all, ad the right kidney appears, if not fully obstructed, mostly obstructed in that right ureter. Therefore, pending patient stability and owner wishes, recommend intervention could include surgical intervention to remove the left kidney and place a SUB on the right side.

The remaining pathology is believed to be less significant. Having said that, if the patient has a history of gastrointestinal signs, further evaluation of the mucosal speckling is recommended, beginning with A gastrointestinal malabsorption panel (including cobalamin, folate, TLI and PLI) to Texas A&M GI Laboratory.



IMAGING PERFORMED BY

SVS Mobile Imaging MI 734-637-7711
svsimagingmi@gmail.com



PATIENT

Chuey Fazio

SPECIES

Canine

BREED

Dachshund

SEX

Neutered Male

AGE

15 Years

WEIGHT

11.7 Pounds

INTERPRETED BY

Beth Johnson, DVM
DACVIM

IMAGING PERFORMED BY

Amy Mayhew, LVT

HOSPITAL NAME

SVS Imaging MI

REFERRING VET

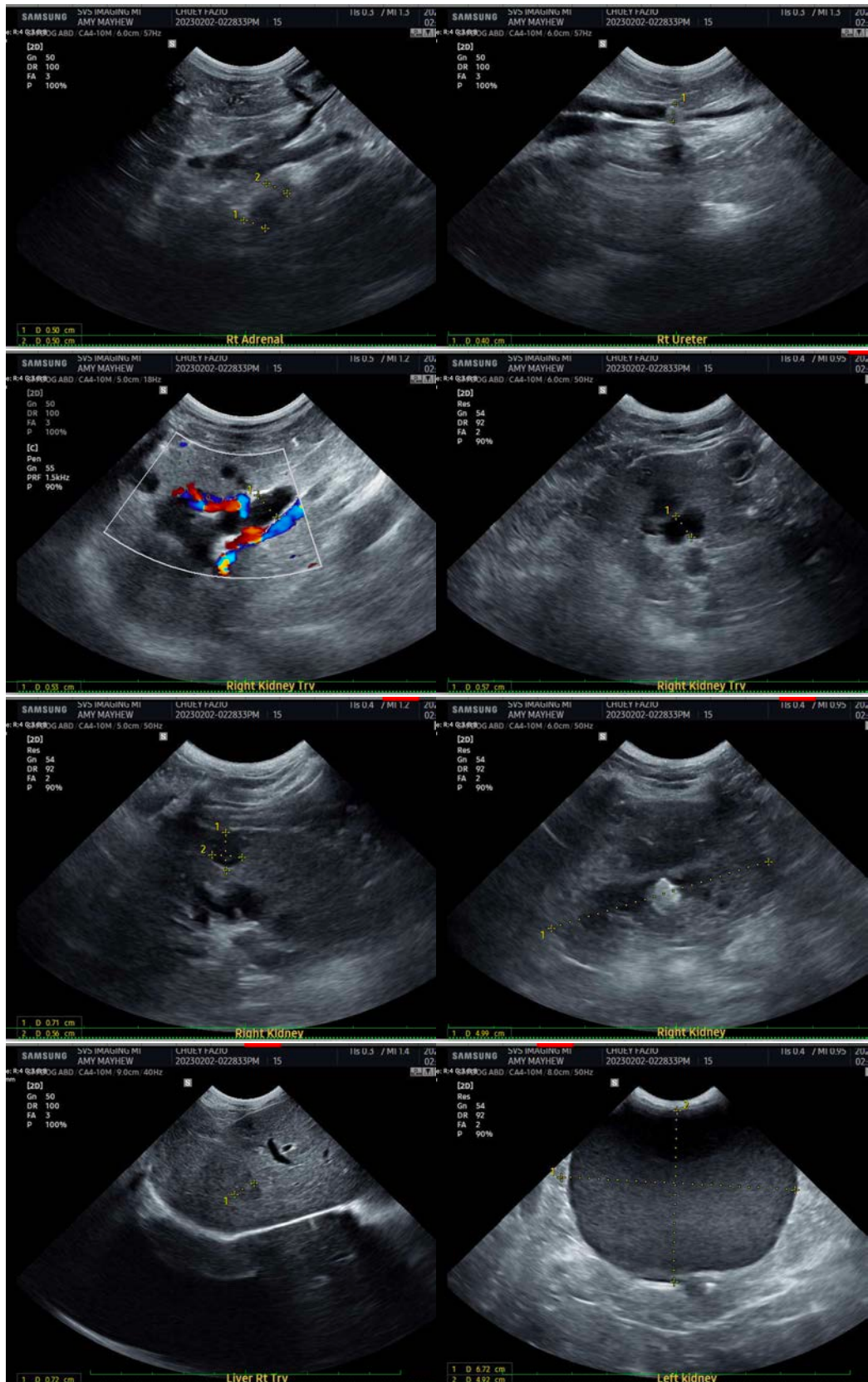
Dr. Amy Kallin

INVOICE

44752

DATE

2/2/23



IMAGING PERFORMED BY

SVS Mobile Imaging MI 734-637-7711
svsimagingmi@gmail.com



PATIENT

Chuey Fazio

SPECIES

Canine

BREED

Dachshund

SEX

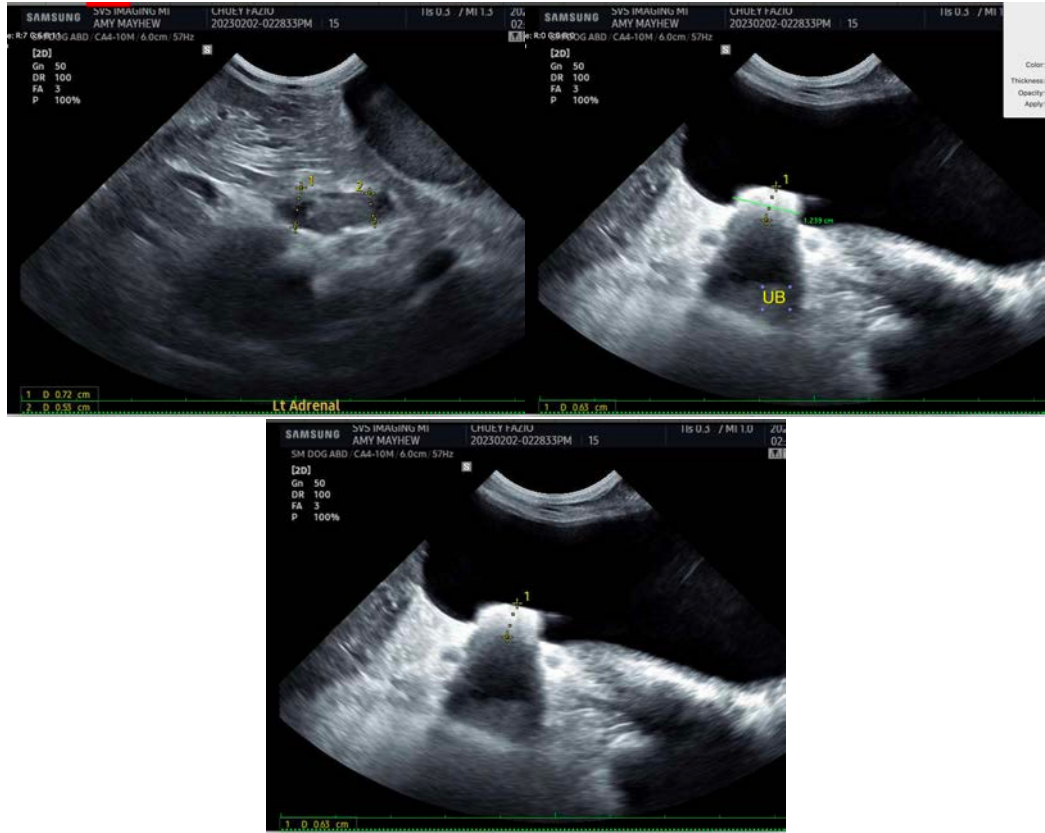
Neutered Male

AGE

15 Years

WEIGHT

11.7 Pounds



INTERPRETED BY

Beth Johnson, DVM
DACVIM

IMAGING PERFORMED BY

Amy Mayhew, LVT

HOSPITAL NAME

SVS Imaging MI

REFERRING VET

Dr. Amy Kallin

INVOICE

44752

DATE

2/2/23

The information and recommendations provided are based on the images presented by the referring veterinarian/sonographer. No evaluation can be communicated regarding pathology that was not visible in the image/video clips provided.

Thank you for this referral. If the clinical or image interpretation does not parallel your findings or if I can be of any further assistance please contact me.

Beth Johnson, DVM, DACVIM
Beth.Johnson@sonopath.com