

**DATE PRESENTING CLINICAL SIGNS**

2/2/22

History: p presented on 1/24/22 for chronic intermittent vomiting and weight loss. O states the vomiting started around Christmas shortly after the p received a new toy. Shortly after that, the o noted bird seed and bile in the vomit. Additionally, o has noticed some loss of muscle mass and lethargy. Appetite has remained normal. O also mentions a single episode of shaking where p head was bobbing. Owner states it was short lived and p did not appear to be dysphoric or disoriented.

PATIENT

Bruin Vogel

SPECIES

Canine

Lab Results: 1/24/22 fecal – negative. 1/24/22 total health check plus: SDMA 17, Amylase 315.

Date of Previous IntraPet Ultrasound: No previous IntraPet scans.

Sedation: Not required to complete full diagnostic ultrasound.

Stat Report: Not requested.

BREED

Mixed

ULTRASONOGRAPHIC EXAMINATION OF THE ABDOMEN**SEX**

Neutered Male

Urinary System

The urinary bladder is moderately distended with anechoic contents. No masses, inflammatory changes, echogenic sediment or cystoliths are observed. The urinary bladder, trigone and visible pelvic urethra are normal in thickness with a smooth mucosal surface.

AGE

11/23/16

Prostate (neutered) is normal in size, echotexture and echogenicity for a neutered male.

The right kidney is normal in size (6.23 cm), shape and echogenicity. It has smooth peripheral margination. There is a normal 1:3 cortex to medulla ratio with appropriate corticomedullary distinction. There is no evidence of pyelectasia, mineral or infarcts observed.

WEIGHT

65.4 Pounds

The left kidney is normal in size (6.73 cm), shape and echogenicity. It has smooth peripheral margination. There is a normal 1:3 cortex to medulla ratio with appropriate corticomedullary distinction. There is no evidence of pyelectasia, mineral or infarcts observed.

INTERPRETED BYBeth Johnson, DVM
DACVIM**Adrenal Glands**

The right adrenal gland is normal in size (2.78 cm long x 0.76 cm at the cranial pole and 0.81 cm at the caudal pole), shape and contour. Corticomedullary structure is unremarkable. Visible surrounding vasculature appears normal.

IMAGING PERFORMED BYStephanie Pearce
RDCS, RVT

The left adrenal gland is normal in size (2.53 cm long x 0.56 cm at the cranial pole and 0.57 cm at the caudal pole), shape and contour. Corticomedullary structure is unremarkable. Visible surrounding vasculature appears normal.

HOSPITAL NAME

Northwind AH

Spleen

The spleen is subjectively normal in size with a normal smooth capsular contour. Parenchyma is appropriately finely textured and homogenous with normal echogenicity relative to surrounding tissue (hyperechoic to liver). No focal nodules or masses are observed. Splenic vasculature appears normal.

REFERRING VET

Dr. Wilson

Liver

The liver is subjectively normal in size with normal smooth curvilinear peripheral contour. Parenchyma is appropriately hypoechoic to the spleen in echogenicity and appropriately mildly coarse and homogenous in echotexture. No focal lesions are observed. Visible vasculature and biliary tree appear normal without distension or congestion.

INVOICE

35397

The gallbladder is non-distended in size. The wall is smooth without visible thickening. Luminal contents are primarily anechoic. There is no evidence of cystic or common bile duct dilation.

Gastrointestinal

The stomach wall is normal in thickness (canine < 0.5 cm and feline < 0.4 cm) and layering. The lumen of the stomach is markedly distended with echogenic non-shadowing luminal contents and gas consistent with normal ingesta. There is no evidence of obstruction, foreign material or infiltrative disease. Pyloric outflow tract appears patent.

**Note: The patient was reportedly fasted at 6pm the day before the ultrasound with water pulled at 7:30pm.

The visible small intestines are normal in wall thickness and layering (canine duodenum < 0.5 cm and feline duodenum < 0.4 cm; other < 0.3 cm). Small intestinal motility appears adequate (1-3 contractions per min). The lumen of the small intestine is empty with no evidence of obstruction, foreign material or infiltrative disease.

The visible colon is normal in wall thickness (< 0.2 cm) and layering. Contents are consistent with normal formed feces and gas.

Pancreas

The pancreatic parenchyma is appropriately isoechoic to surrounding tissue. Visible capsule is smooth and normal in contour. There is no visible pancreatic duct dilation. There is no evidence of active peripancreatic inflammation.

Free Abdomen

There is no evidence of peritoneal effusion. Hypoechoic enlarged mesenteric lymph nodes that maintain a normal shape are appreciated.

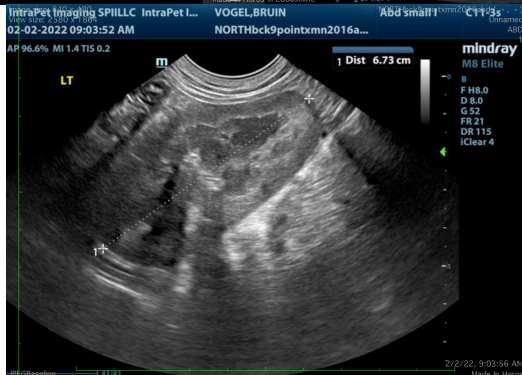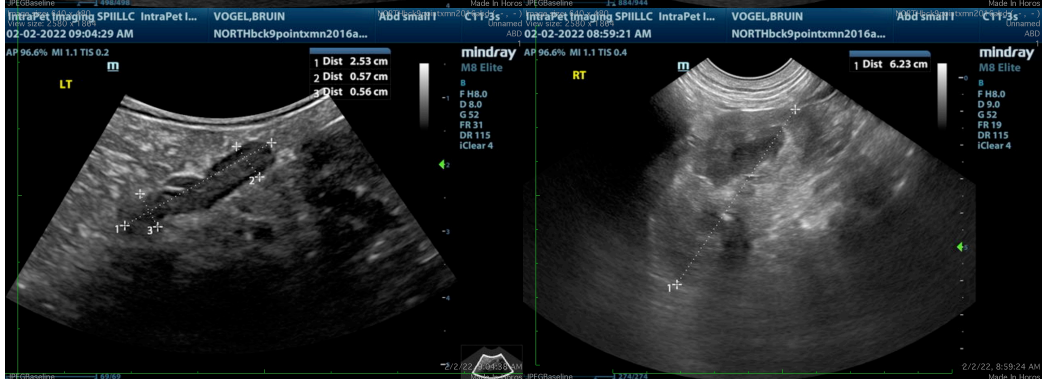
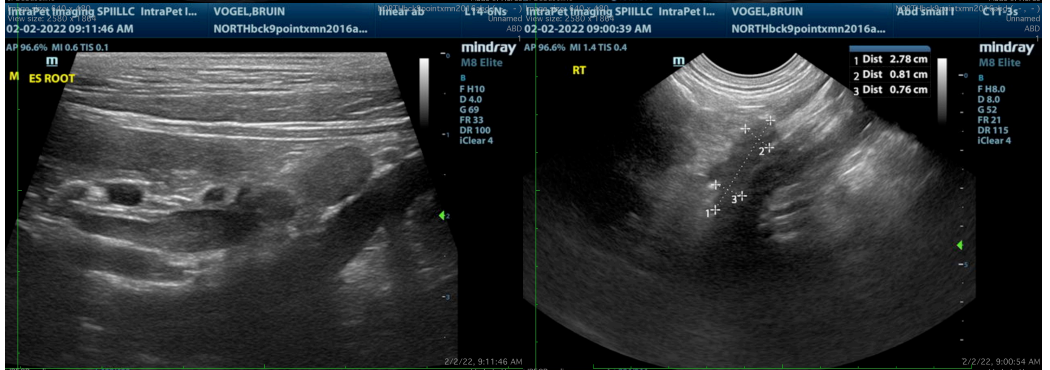
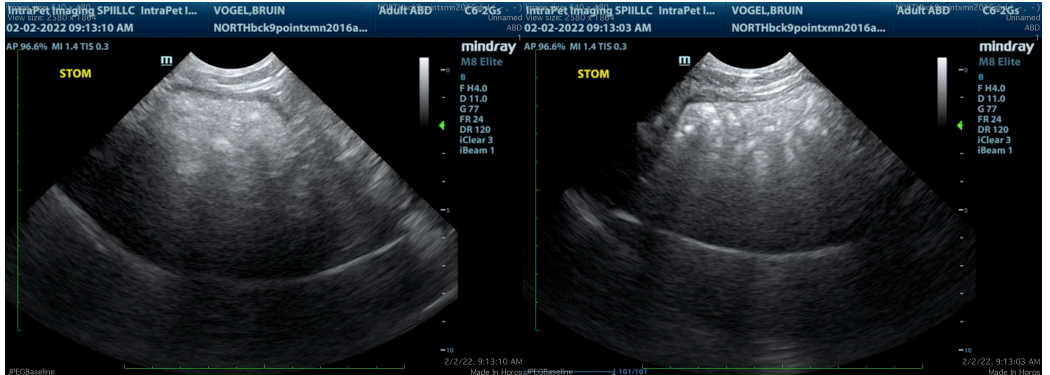
ULTRASONOGRAPHIC FINDINGS

- Markedly distended stomach with what appears to be normal ingesta. However, given the reported fasting, there may be some delayed gastric emptying or pyloric outflow obstruction, or what appears to be normal ingesta could be soft foreign material resulting in obstruction and the reported intermittent vomiting since ingesting the toy over Christmas.
- Reactive mesenteric lymphadenopathy

INTERPRETATION OF THE FINDINGS & FURTHER RECOMMENDATIONS

Recommendations include a more prolonged fasting with recheck of the stomach, or an ultrasound immediately after one of the vomiting episodes to hopefully be able to scan an empty stomach. If these options are not possible, or do not result in an empty stomach, then either gastroscopy would be recommended to further analyze the contents of the stomach and the pyloric outflow tract, or a surgical laparotomy for gastrotomy, assessment of the pyloric outflow tract, and biopsy of the enlarged mesenteric lymph nodes could be considered.

If the stomach empties normally, and the chronic intermittent vomiting persists, recommendations would include a gastrointestinal malabsorption panel including TLI, PLI, folate and cobalamin to Texas A&M GI laboratory as well as a baseline cortisol to rule out unlikely but possible hypoadrenocorticism. In the meantime, a diet change to a novel or hydrolyzed protein diet may help alleviate clinical signs if food insensitivity or inflammatory bowel disease are a component of this condition.



The information and recommendations provided are based on the images presented by the referring veterinarian/sonographer. No evaluation can be communicated regarding pathology that was not visible in the image/video clips provided.

Thank you for this referral. If the clinical or image interpretation does not parallel your findings or if I can be of any further assistance please contact me.

Beth Johnson, DVM, DACVIM
Beth.Johnson@sonopath.com